



# Articular Cartilage Injury in Athletes

## Citation

McAdams, Timothy R., Kai Mithoefer, Jason M. Scopp, and Bert R. Mandelbaum. 2010. "Articular Cartilage Injury in Athletes." *Cartilage* 1 (3): 165-179. doi:10.1177/1947603509360210. <http://dx.doi.org/10.1177/1947603509360210>.

## Published Version

doi:10.1177/1947603509360210

## Permanent link

<http://nrs.harvard.edu/urn-3:HUL.InstRepos:17295686>

## Terms of Use

This article was downloaded from Harvard University's DASH repository, and is made available under the terms and conditions applicable to Other Posted Material, as set forth at <http://nrs.harvard.edu/urn-3:HUL.InstRepos:dash.current.terms-of-use#LAA>

## Share Your Story

The Harvard community has made this article openly available.  
Please share how this access benefits you. [Submit a story](#).

[Accessibility](#)

# Articular Cartilage Injury in Athletes

Timothy R. McAdams<sup>1</sup>, Kai Mithoefer<sup>2</sup>, Jason M. Scopp<sup>3</sup>,  
and Bert R. Mandelbaum<sup>4</sup>

Cartilage  
1(3) 165–179  
© The Author(s) 2010  
Reprints and permission:  
sagepub.com/journalsPermissions.nav  
DOI: 10.1177/1947603509360210  
http://cart.sagepub.com



## Abstract

Articular cartilage lesions in the athletic population are observed with increasing frequency and, due to limited intrinsic healing capacity, can lead to progressive pain and functional limitation over time. If left untreated, isolated cartilage lesions can lead to progressive chondropenia or global cartilage loss over time. A chondropenia curve is described to help predict the outcome of cartilage injury based on different lesion and patient characteristics. Nutraceuticals and chondroprotective agents are being investigated as tools to slow the development of chondropenia. Several operative techniques have been described for articular cartilage repair or replacement and, more recently, cartilage regeneration. Rehabilitation guidelines are being developed to meet the needs of these new techniques. Next-generation techniques are currently evaluated to optimize articular cartilage repair biology and to provide a repair cartilage tissue that can withstand the high mechanical loads experienced by the athlete with consistent long-term durability.

## Keywords

microfracture, cartilage repair, sports injury

## Introduction

Articular cartilage defects of the knee are frequently observed. Curl and coworkers described 53,569 hyaline cartilage lesions in 19,827 patients undergoing knee arthroscopy.<sup>24</sup> Similarly, a recent prospective survey of 993 consecutive knee arthroscopies demonstrated evidence of articular cartilage pathology in 66%.<sup>5</sup> Most lesions are single high-grade lesions located on the femur. Levy and coworkers have noted an increasing frequency of chondral injuries in collegiate, professional, and world-class athletes.<sup>21</sup> Besides this rising incidence in high-level competitive sports, increasing participation in organized recreational sports such as soccer, basketball, and football has been associated with a growing incidence of sports-related articular cartilage injuries.<sup>4,59,95</sup> Articular cartilage lesions frequently result in association with acute ligament or meniscal injuries, traumatic patellar dislocations, and osteochondral injuries or may develop from chronic ligamentous instability or malalignment.<sup>9,98,125</sup> Articular cartilage defects of the femoral condyles have been observed in up to 50% of athletes undergoing anterior cruciate ligament (ACL) reconstruction with an increased propensity in female athletes.<sup>4,110</sup> These injuries often limit participation in athletic activity while predisposing the athlete to early joint degeneration.<sup>32,69</sup>

Due to their documented poor spontaneous repair potential, injuries to the articular cartilage surfaces present

a therapeutic challenge particularly in young and active individuals.<sup>18,19,57</sup> Recent development of new surgical techniques has incited considerable clinical and scientific interest in articular cartilage repair, replacement, and most recently, regeneration.<sup>2,3,16,43,98,130</sup> Because injuries to the articular cartilage of the knee have been shown to present one of the most common causes of permanent disability in athletes,<sup>28,30</sup> management of articular cartilage in this high-demand population has important long-term implications.<sup>118,119</sup> Due to the documented detrimental effect of excessive joint loading and articular impaction,<sup>18,57</sup> articular cartilage repair in the athletic population requires cartilage surface restoration that can withstand the significant mechanical joint stresses generated during high-impact, pivoting sports. Besides reducing pain, increasing mobility, and improving functional outcome scores, the ability to return to sport and to continue to perform at the preinjury

<sup>1</sup>Department of Orthopaedic Surgery, Stanford University, Palo Alto, CA

<sup>2</sup>Harvard Vanguard Orthopedics and Sports Medicine, Brigham and Women's Hospital, Harvard Medical School, Boston, MA

<sup>3</sup>Peninsula Regional Medical Center, Salisbury, MD

<sup>4</sup>Santa Monica Orthopedic and Sports Medicine Foundation, Los Angeles, CA

## Corresponding Author:

Timothy R. McAdams, Stanford University, 450 Broadway Street, Redwood City, CA 94063

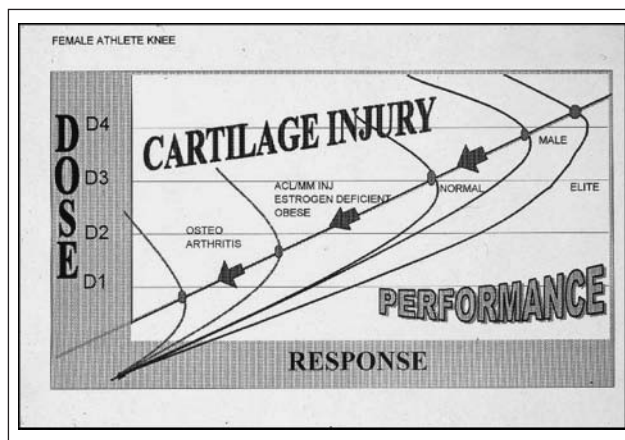
Email: tmcadams@stanford.edu

athletic level is the most important parameter for outcome evaluation from articular cartilage restoration in this challenging population.

## Natural History

The limited ability of articular cartilage for spontaneous repair has been well documented.<sup>18,137</sup> Following the acute injury and resultant tissue necrosis, the lack of vascularization of articular cartilage prevents the physiological inflammatory response to tissue injury. The absent potential for replication and repair by the intrinsic mature chondrocytes and lack of recruitment of extrinsic undifferentiated repair cells results in a qualitatively and quantitatively insufficient repair cartilage. Repetitive loading of the injured articular cartilage results in further cellular degeneration with accumulation of degradative enzymes and cytokines, disruption of collagen ultrastructure, increased hydration, and fissuring of the articular surface. These biochemical and metabolic changes mimic the early changes seen in osteoarthritis.<sup>25,77,82</sup>

While much knowledge has been gained from laboratory studies about the progression from cartilage injury to osteoarthritis, prospective clinical information about the natural history of articular cartilage lesions is still rare, particularly in athletes. This lack of long-term data can be largely attributed to the previous inability to accurately diagnose and follow chondral lesions by noninvasive techniques. One study demonstrated that hyaline cartilage defects cause pain and swelling and predict severe changes in lifestyle and athletic activity in patients with ACL injuries.<sup>29</sup> Other authors have shown that untreated articular cartilage defects in patients with ACL deficiency resulted in significantly worse outcome scores up to 19 years after the original injury.<sup>122</sup> Nebelung reported 68% of ACL-deficient East German Olympic athletes had grade 4 chondral lesions 20 years after injury.<sup>101</sup> Importantly, a Swedish study reported on the long-term results in 28 athletes with isolated, severe chondral damage in the weightbearing condyles. While 75% of athletes returned to their sport initially, a significant decline of athletic activity was observed 14 years after the initial injury with radiographic evidence of osteoarthritis in 57% of these athletes.<sup>79</sup> Similarly, a prospective study of osteochondral lesions reported poor results with strenuous athletic activity in 38% and moderate to severe radiographic evidence of osteoarthritis in 45% at an average of 34 years.<sup>49</sup> This is consistent with the findings of a National Institutes of Health (NIH) consensus conference on osteoarthritis, which demonstrated a relative risk of 4.4 to 5.3 for knee osteoarthritis in high-demand, pivoting athletes.<sup>32</sup> Church found an increased risk of degenerative change in patients who delayed ACL reconstruction to more than 1 year after injury compared to patients who were reconstructed within 1 year.<sup>22</sup> This



**Figure 1.** Diagram displaying the relationship between level of performance (response) and activity (dose) with performance and cartilage injury.

increased risk for arthritic joint degeneration is felt to result from the high joint stresses associated with the repetitive joint impact and torsional loading seen with the rapid deceleration motions, frequent pivoting, and player contact in high-impact sports.

## Chondropenia

The increased risk for development of knee osteoarthritis in athletes is well documented, particularly at the elite level.<sup>28,30,32,70,118,119</sup> Intact articular cartilage possesses optimal load-bearing characteristics and adjusts to the level of activity. Increasing weightbearing activity in athletes and adolescents has been shown to increase the volume and thickness of articular cartilage<sup>58</sup> and to increase knee cartilage glycosaminoglycan content.<sup>117</sup> In the healthy athlete, a positive, linear dose-response relationship exists for repetitive loading activities and articular cartilage function. However, studies indicate that this dose-response curve reaches a threshold and that activity beyond this threshold can result in maladaptation and injury of articular cartilage<sup>62</sup> (Fig. 1). High-impact joint loading above this threshold has been shown to decrease cartilage proteoglycan content, increase levels of degradative enzymes, and cause chondrocyte apoptosis.<sup>6,57,77,107</sup> If the integrity of the functional weightbearing unit is lost, either through acute injury or chronic microtrauma in the high-impact athlete, a chondropenic response is initiated that can include loss of articular cartilage volume and stiffness, elevation of contact pressures, and development or progression of articular cartilage defects. Concomitant pathological factors such as ligamentous instability, malalignment, and meniscal injury or deficiency can further support progression of the chondropenic cascade. Without intervention, chondropenia leads to progressive deterioration

of articular cartilage function and may ultimately progress to osteoarthritis.

Commonly used classification systems for cartilage injury include the Outerbridge and International Cartilage Repair Society (ICRS).<sup>56,105</sup> These classification systems are based on size and depth of the articular cartilage lesion. We propose a new cartilage score, the “chondropenia severity score” (CSS), which includes consideration of the chondropenic curve. The CSS gives objective scores to each anatomical location and also considers meniscal injury (**Table 1**). Based on the CSS, a young athlete with an isolated grade III lesion would have a better prognosis than an older individual with degenerative medial and lateral meniscal tears and a diffuse grade II chondral injury. The senior author (B.R.M.) has been using the CSS in all arthroscopies over the last 2 years, and studies are ongoing to see how the CSS relates to prognosis for different age groups, body mass index, and gender.

## Diagnosis

Diagnosis of articular cartilage lesions can be achieved by a combination of history, clinical examination, and radiographic/magnetic resonance evaluation. A high index of suspicion is important in patients with acute hemarthrosis,<sup>65</sup> acute or chronic ligamentous instability, patellar dislocation or maltracking, or lower extremity malalignment. Clinical symptoms of articular cartilage injury are not specific, but athletes will often complain about activity-related pain, effusion, catching, and locking. Plain radiographs including weight-bearing anteroposterior and lateral views, Rosenberg and tunnel views, long-leg films, and Merchant views can help to identify osteochondral lesions, joint space narrowing, patellar maltracking, or lower extremity malalignment. Cartilage-sensitive magnetic resonance imaging (MRI) presents a sensitive, specific, and accurate tool for noninvasive diagnosis of articular cartilage injury. Images should be obtained in 3 planes, and using fast spin-echo imaging with a repetition time (TR) of 3,500 to 5,000 milliseconds and moderate echo time (TE) provides high contrast resolution between articular cartilage, subchondral bone, and joint fluid.<sup>114</sup> Besides preoperative diagnosis, cartilage-sensitive MRI can be very helpful for postoperative evaluation of cartilage repair.<sup>17,94</sup> Even though MRI is an outstanding tool for the evaluation of cartilage injury, a considerable number of chondral lesions may remain undetected until arthroscopy, especially partial-thickness lesions.<sup>34,136</sup> The number of undetected lesions should decrease in the future, as the MRI techniques are improving rapidly. The latest MRI techniques will not only predictably define subtle cartilage lesions but also detect changes in the matrix, such as glycosaminoglycan content.<sup>111</sup>

## Nutritional Supplements and Viscosupplementation

Nutritional supplements have received much recent interest as both a way to prevent cartilage injury and limit its progression.<sup>23,41</sup> However, most of the literature on nutritional supplements involves their role in general osteoarthritis, and very little is known about how it may affect athletes at different stages of the chondropenia curve. Regardless, the sports physician should have a basic understanding of the common supplements as they will undoubtedly continue to increase as investigators search for a way to slow joint destruction.

### Glucosamine and Chondroitin

After publication of *The Arthritis Cure* in 1997, glucosamine has been the center of much attention and controversy.<sup>133</sup> Glucosamine has been found to be safe and effective in meta-analysis studies,<sup>88,135</sup> but definitive conclusions were difficult due to possible commercial bias and different methodologies. In 2006, the NIH sponsored the GAIT (Glucosamine/chondroitin Arthritis Intervention), which compared glucosamine, chondroitin, glucosamine/chondroitin combination, celecoxib, and placebo in 1,583 patients with knee arthritis. The glucosamine/chondroitin sulfate combination had a rate of response 6.5% greater than placebo, but this was not statistically significant. Other nutritional supplements, including methylsulfonylmethane (MSM),<sup>61</sup> S-adenosylmethionine,<sup>99</sup> and collagen hydrolysate,<sup>23</sup> are all being studied as potential supplements to limit arthritis pain.

Viscosupplementation, like nutritional supplements, has become a popular treatment option for osteoarthritis of the knee. A series of 3 to 5 injections of hyaluronic acid, hylan, or hyaluronan may be done in an effort to decrease pain and improve function. Much discrepancy exists between the studies of viscosupplementation. Campbell compared meta-analyses on hyaluronate efficacy and safety and found moderate evidence to support the benefit of hyaluronate with respect to pain reduction and functional improvement with a low risk of harm.<sup>20</sup> Likewise, a meta-analysis by Wang et al. found hyaluronate injections can reduce pain from arthritis of the knee with few adverse effects.<sup>138</sup> Although not commonly used in the younger athlete, viscosupplementation can be helpful for recreational athletes who are lower on the chondropenic curve. Further study is needed to determine what, if any, chondroprotective role glucosamine/chondroitin, other nutritional supplements, and viscosupplementation have in athletes with articular cartilage injury.

**Table I.** Chondropenia Severity Score (CSS) Is Graded 0 to 100 and Involves Assessment of Meniscus Injury as well as Size and Number of Cartilage Lesions

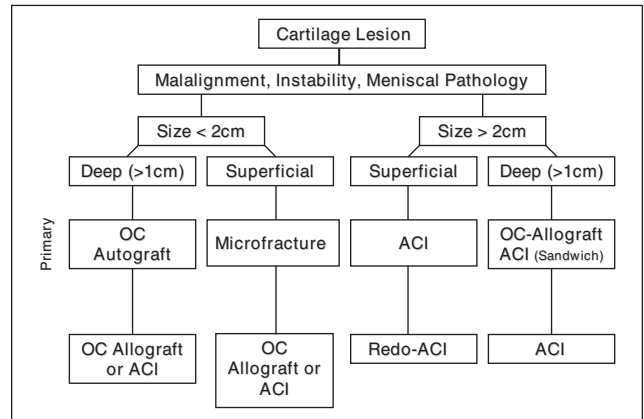
PATELLOFEMORAL		MEDIAL COMPARTMENT		LATERAL COMPARTMENT	
<b>Patella</b>		<b>MFC</b>		<b>LFC</b>	
Normal	10	Normal	10	Normal	10
Grade IA	8	Grade IA	8	Grade IA	8
Grade IB	6	Grade IB	6	Grade IB	6
Grade IIA	5	Grade IIA	5	Grade IIA	5
Grade IIB	3	Grade IIB	3	Grade IIB	3
Grade IIIA	2	Grade IIIA	2	Grade IIIA	2
Grade IIIB	1	Grade IIIB	1	Grade IIIB	1
Grade IV	0	Grade IV	0	Grade IV	0
<b>Trochlea</b>					
Normal	10	Normal	10	Normal	10
Grade IA	8	Grade IA	8	Grade IA	8
Grade IB	6	Grade IB	6	Grade IB	6
Grade IIA	5	Grade IIA	5	Grade IIA	5
Grade IIB	3	Grade IIB	3	Grade IIB	3
Grade IIIA	2	Grade IIIA	2	Grade IIIA	2
Grade IIIB	1	Grade IIIB	1	Grade IIIB	1
Grade IV	0	Grade IV	0	Grade IV	0
		MEDIAL MENISCUS		LATERAL MENISCUS	
		100% remaining	20	100% remaining	20
		>2/3 remaining	15	>2/3 remaining	15
		1/3 to 2/3 remaining	10	1/3 to 2/3 remaining	10
		<1/3 remaining	5	<1/3 remaining	5
		0% remaining	0	0% remaining	0
<b>SUMS:</b>					
<b>TOTAL CSS:</b>					

Patient Name: \_\_\_\_\_ Index Knee: \_\_\_\_\_

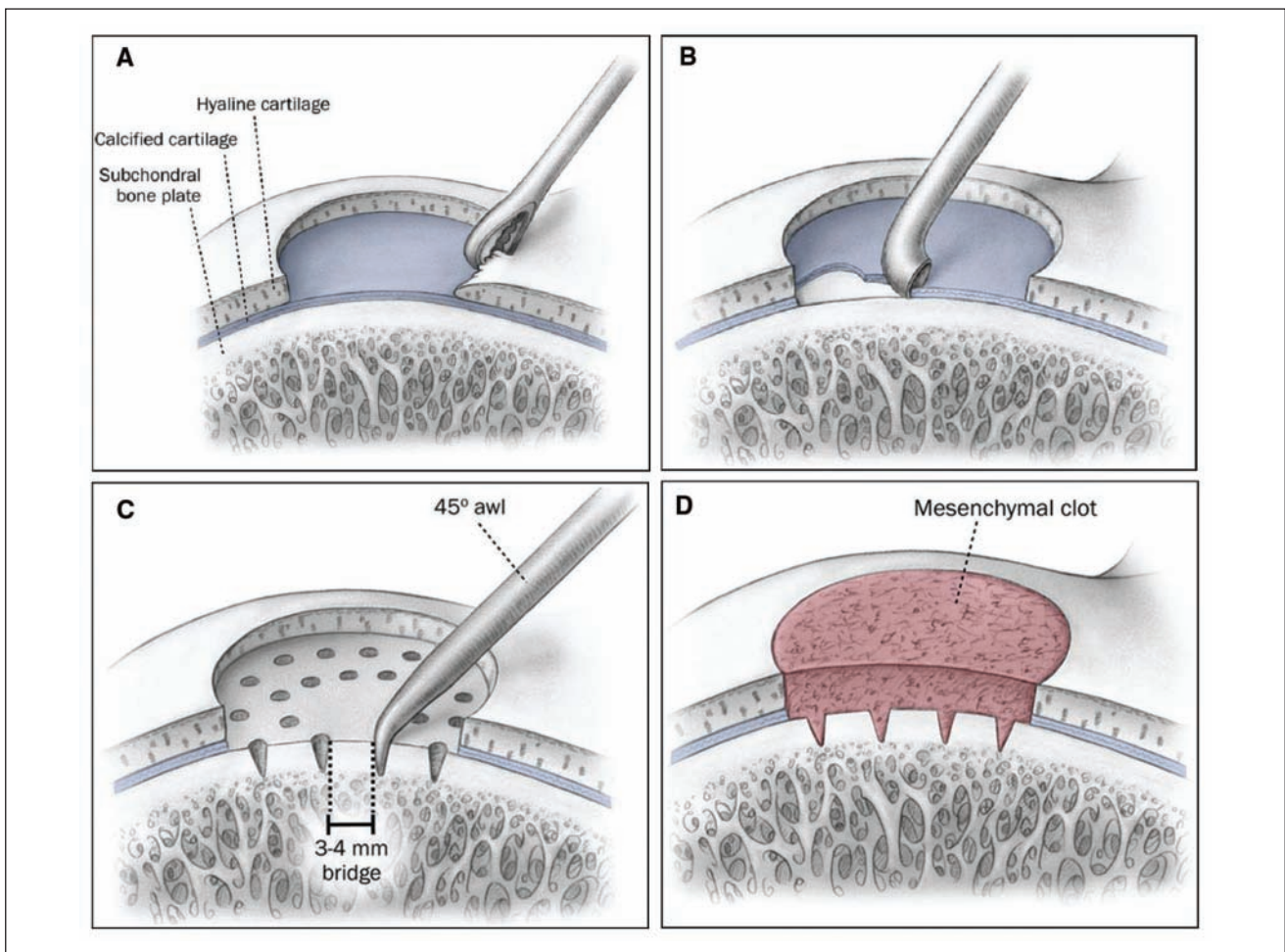
Dob: \_\_\_\_\_

### Treatment

Historically, surgical attempts at cartilage repair involved stimulation of mesenchymal stem cell metaplasia to form fibrocartilage. This is done by lavage, debridement, drilling, or microfracture, all in an attempt to repair a cartilage defect through marrow stimulation. In an attempt to improve the quality of the cartilage, investigators devised methods to replace rather than repair a cartilage defect. This involves allografts or autografts that fill the defect through a variety of techniques. Most recently, biologic autologous chondrocyte culture techniques have emerged in an effort to regenerate hyaline cartilage. The treatment algorithm for articular cartilage defects depends on both the size and depth of the lesion (Fig. 2).



**Figure 2.** Clinical algorithm for management of articular lesions in athletes.



**Figure 3.** Microfracture technique for articular cartilage repair with debridement of cartilage margins (A), removal of calcified cartilage (B), and systematic distribution of microfractures of the subchondral bone (C), resulting in formation of a pluripotent mesenchymal clot in the cartilage defect that is well anchored in the microfracture holes (D).

Source: Mithoefer K, Williams RJ III, Warren RF et al. Chondral resurfacing of articular cartilage defects in the knee with the microfracture technique. *Surgical technique. J Bone Joint Surg Am.* 2006;88:294-304. Reprinted with publisher permission (<http://www.ejbs.org/>).

### Cartilage Repair: Mesenchymal Stem Cell Stimulation

Reports of mesenchymal stem cell stimulation first occurred in 1946 when Magnusson<sup>77</sup> described debridement of injured hyaline cartilage. Subsequent reports described abrasion, drilling, and microfracture.<sup>33,55,103,113,114,120,126,127</sup> In 1994, Rodrigo described the use of an “ice pick,” or small surgical awls, to create microfractures, the technique commonly used today for marrow stimulation.<sup>116</sup>

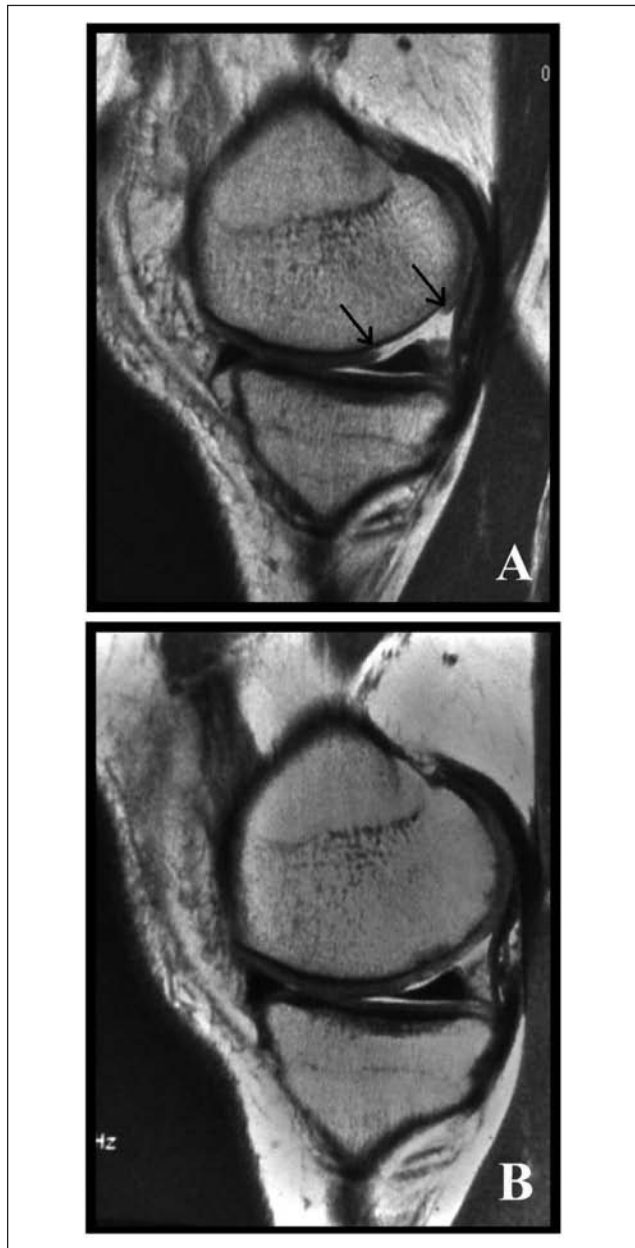
The microfracture technique has been well described<sup>91,92</sup> and involves debridement through the calcified cartilage layer followed by perforation of the subchondral bone with arthroscopic surgical awls (**Fig. 3**). In an equine study, Frisbie demonstrated the importance of removal of the calcified cartilage layer in order to maximize the amount of repair tissue.<sup>35</sup> The subchondral bone perforations are generally between 2 to 4 mm apart, depending on the size of the lesion.<sup>91</sup> Steadman emphasizes early motion protocols with continuous passive motion (CPM) and limited weight-bearing for 8 weeks in order to optimize long-term functional outcome.<sup>129</sup> However, Marder found no difference in the clinical result of microfracture between patients who were nonweightbearing with CPM versus patients allowed weightbearing as tolerated without CPM.<sup>87</sup>

Initial studies showed good early clinical results that tended to deteriorate with time.<sup>39</sup> Recently, Steadman measured functional outcomes in 71 knees after microfracture, and clinical improvement persisted 7 years after surgery in 80%.<sup>129</sup> Mithoefer prospectively studied 48 patients who underwent microfracture and found 67% good to excellent results at 2-year minimum follow-up.<sup>94</sup> Suboptimal results were correlated with high body mass index and poor fill grades on MRI. Mithoefer also prospectively evaluated the results of microfracture technique in high-impact athletes and found 66% good to excellent results.<sup>91</sup> In this high activity group, 47% had a decrease in Tegner activity scores after an initial increase.

Microfracture is an appealing option in the treatment of articular cartilage injury because it is relatively simple with minimal morbidity. It appears best suited for young patients with acute, smaller contained lesions.<sup>68</sup> Potential deterioration of clinical results over time may be related to defect repair with “hyaline-like” rather than true hyaline cartilage, with resultant compromise in wear characteristics. This has prompted investigation toward replacement and remodeling techniques.

### Cartilage Replacement: Substitution Replacement Options

Segmental fresh allograft replacement of osteochondral defects was first reported by Lexar in 1908.<sup>74</sup> Additional studies showed good to excellent results in 75% to 86% of patients, but the risk of disease transmission and difficulties with procurement of fresh, unirradiated grafts have limited widespread use of this technique.



**Figure 4.** Technique of mosaicplasty using osteochondral cylinder harvest from the peripheral trochlea and press-fit insertion into the cartilage defect in a mosaic pattern with recreation of the condylar convexity.

More recently, osteochondral autograft transplantation surgery (OATS), or “mosaicplasty,” has been utilized for small, 1- to 2-cm lesions. In this technique, the osteochondral autograft cylindrical plugs are harvested from an area of the distal femur that experiences the lowest contact pressures, most commonly the superomedial and superolateral trochlea.<sup>1,10,37</sup> The donor site can be “back-filled” by bone graft substitute if desired, but donor-site morbidity can be significant.<sup>115</sup> Peripheral chondrocyte death from mechanical

trauma at the graft and recipient edges can lead to lack of peripheral integration with persistent gap formation.<sup>53</sup>

The surgical technique was described by Hangody and can be accomplished through a mini-arthrotomy or arthroscopically<sup>48</sup> (**Fig. 4**). The graft diameter can be varied to optimize defect filling and usually ranges from 6 to 8 mm in diameter and 15 to 25 mm in length. Although a larger diameter graft provides more hyaline tissue and better pull-out properties, it may be difficult to contour. Initially, it was recommended to leave the grafts slightly “proud” to allow for some settling, but this can increase contact pressures and result in fissuring or cysts. It may be better to leave the graft slightly sunk rather than proud, but a flush graft is optimal.<sup>45,63,64,106</sup> Care must be taken to limit impact loads during graft insertion; otherwise, chondrocyte death can occur.<sup>15</sup>

Rabbit and goat model studies show evidence of preservation of chondral viability with osteochondral autograft transfer.<sup>70,100</sup> Clinical studies are optimistic as well.<sup>7,21,44,47,84</sup> In 2003, Hangody used clinical scores, arthroscopy, and histological examination of biopsy specimens to evaluate 831 mosaicplasties.<sup>47</sup> Good to excellent results were attained in 92% of femoral condyle lesions, 87% of tibial plateau lesions, and 79% of patellofemoral lesions over a 10-year period. In 2005, Gudos reported superiority of mosaicplasty over microfracture in the treatment of articular cartilage defects (average, 2.5 cm<sup>2</sup>) in the knee of young, active athletes.<sup>44</sup> In this prospective, randomized study with an average follow-up of 37.1 months, only 52% of microfracture athletes could return to sports at preinjury level compared to 93% of the mosaicplasty athletes. In 2007, Marcacci prospectively evaluated 30 full-thickness lesions <2.5 cm<sup>2</sup> treated arthroscopically with autologous osteochondral grafts.<sup>85</sup> At 7 years, the authors found good to excellent results in 76.7% of patients based on ICRS objective scoring. Twenty-four of the 30 patients underwent MRI at 7 years, and 62.5% showed good integration of the graft. Osteochondral autograft transplantation is a viable source of hyaline tissue for articular cartilage defects. It is best suited for smaller (2-3 cm) lesions due to limited donor tissue availability.

Options for cartilage transplantation in larger defects include cartilage slurry and osteochondral allograft transplantation. Stone<sup>132</sup> reported significant improvement in pain and function after articular cartilage paste grafting for an average defect size of 28.6 cm<sup>2</sup> (level 4 study). The paste is made by grinding up an 8 × 15-mm osteochondral cylindrical autograft and applying the slurry to the microfractured defect. Further study with longer follow-up is needed before any recommendations can be made. Osteochondral allograft transplantation can provide hyaline tissue for larger defects because it is not limited by autogenous tissue availability. In a prospective study in 2007, McCulloch reported 84% patient satisfaction with 88% radiographic

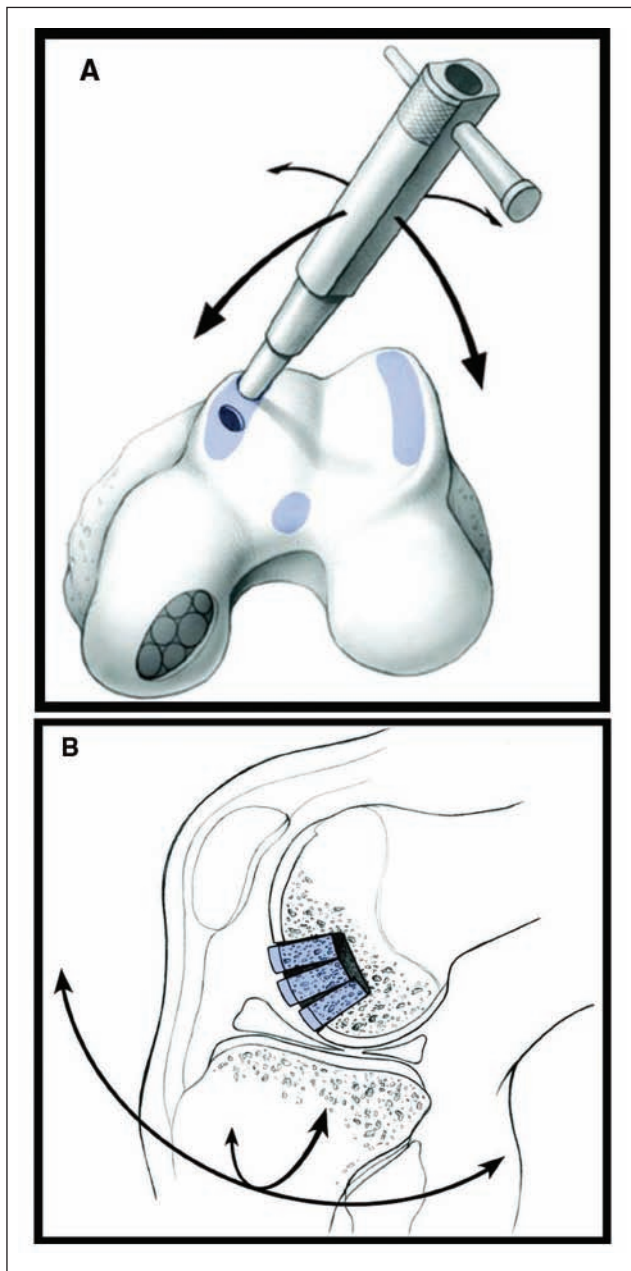
graft incorporation at an average follow-up of 35 months (minimum, 2 years).<sup>92</sup> As with the original allograft techniques described by Lexar in 1908, fresh and cryopreserved osteochondral allografts have a risk of disease transmission. In addition, logistical challenges occur in regard to timing of the procedure, as chondrocyte death may occur 2 to 3 weeks after procurement.<sup>80,141</sup> Williams<sup>141</sup> studied whether this chondrocyte death translates to inferior clinical outcomes. In a review of 19 patients treated with fresh osteochondral grafts stored for a mean of 30 days (range, 17-42 days), Williams found 18 of 19 grafts demonstrated normal cartilage thickness at a mean of 25 months, and functional outcome scores improved. Further study is needed in a larger group of patients to determine if the duration of allograft storage affects the clinical results in the treatment of distal femur osteochondral defects.

### Cartilage Regeneration: Cell/Biologic Implantation

Since 1976, investigators have attempted to transplant perichondrium to stimulate production of articular cartilage.<sup>52,124</sup> However, two thirds of the grafts underwent endochondral ossification. In 1989, Grande<sup>42</sup> supplemented the periosteal transplants with cultured chondrocytes in a rabbit model. This generated interest in “autologous chondrocyte implantations,” or ACI. The rationale for this procedure is based on the ability of normal articular chondrocytes that are released enzymatically to dedifferentiate in monolayer culture and undergo proliferative expansion.<sup>13</sup> This expansion provides a large number of cells that are transplanted 3 to 6 weeks later into a large articular cartilage defect, covered by a periosteal flap from the proximal medial tibia, where they redifferentiate and form hyaline-like cartilage. The periosteal rim is sealed with fibrin glue prior to injection of the chondrocytes (**Fig. 5**). Early encouraging results of this technique were reported by Brittberg in 1994 in *The New England Journal of Medicine*.<sup>16</sup>

Recent studies support ACI in athletes with large articular cartilage lesions (**Fig. 6**). Mithöfer<sup>95</sup> in 2005 reported 72% good to excellent results with ACI in 45 soccer players with a mean defect size of 5.7 cm<sup>2</sup>. There were 83% of competitive-level soccer players who returned to play. Results in adolescent athletes were even better with a 96% return to high-impact sports.<sup>96</sup> ACI also appears effective for trochlear lesions. In 2007, Mandelbaum<sup>81</sup> evaluated 40 trochlear lesions (mean size, 4.5 cm<sup>2</sup>) treated with ACI and found a statistically significant increase in Cincinnati Knee Score at an average follow-up of 59 months. Long-term durability of ACI was reported by Petersen in 2002, with 82% good to excellent results at 2 years and 83% good to excellent results at 5 to 11 years after ACI.<sup>119</sup> Sports participation appears to improve the long-term results of ACI.<sup>131</sup>





**Figure 5.** Technique of mosaicplasty using osteochondral cylinder harvest from the peripheral trochlea (A) and press-fit insertion into the cartilage defect in a mosaic pattern with recreation of the condylar convexity (B).

Source: Hangody L, Ráthonyi GK, Duska Z, et al. Autologous osteochondral mosaicplasty. Surgical technique. *J Bone Joint Surg Am.* 2004;86:65-72. Reprinted with publisher permission (<http://www.ejbs.org/>).

ACI has recently been compared to both debridement and mosaicplasty. Fu compared ACI to debridement in 2005.<sup>36</sup> In this study, patients who underwent ACI obtained higher levels of knee function and had greater pain relief than those who underwent debridement, with a minimum

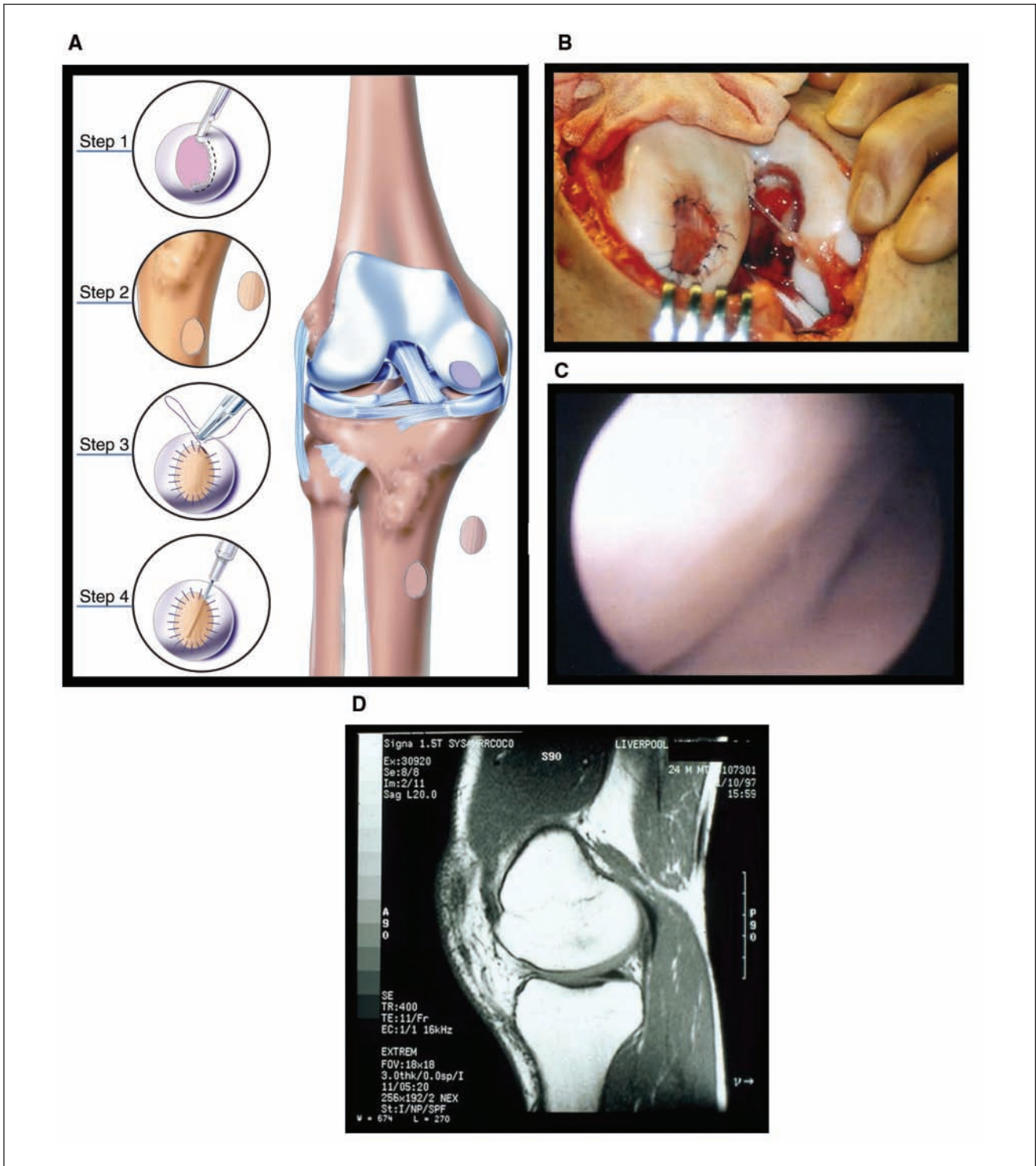
follow-up of 3 years. In 2003, Bentley prospectively compared ACI versus mosaicplasty in 100 randomized patients.<sup>12</sup> Good to excellent results were seen in 88% of the ACI group compared with 69% in the mosaicplasty group. Repeat arthroscopy at 1 year showed good to excellent repair in 82% of the ACI group and only 34% in the mosaicplasty group. Mean defect size was 4.66 cm<sup>2</sup>, and mean follow-up was 19 months (minimum, 1 year). Horas also compared ACI to mosaicplasty but found equally good results after 2 years in 40 patients.<sup>53</sup>

ACI provides an autologous source of hyaline-like tissue and can be used in larger lesions with no donor-site morbidity. The stiffness of ACI hyaline-like tissue (2.77 N) more closely approximates hyaline cartilage (3.07 N) than fibrocartilage seen after microfracture (1.27 N).<sup>108</sup> This is important because reduced stiffness leads to fissures in tissue texture and progressive degradation.<sup>38</sup>

The negative aspects of ACI include technical difficulty, requires a staged procedure, and potential cost/reimbursement issues. One of the main technical challenges is the periosteal flap, and problems with periosteal hypertrophy may necessitate debridement in 18% to 31% of patients.<sup>50,142</sup> When human chondrocytes are cultured and multiplied, they lose their ability to produce type II cartilage matrix and begin producing type I collagen as part of the dedifferentiation process. Once implanted and covered by the periosteum, the chondrocytes redifferentiate in response to local biochemical factors. However, this redifferentiation can be hypertrophic, which can be a clinical problem. Researchers are studying culture techniques that would limit the amount of redifferentiation.<sup>75</sup>

In an attempt to limit the hypertrophy that occurs during redifferentiation, alternatives to the periosteal flap have evolved. In this way, no incision is necessary to harvest the periosteum, and the procedure can sometimes be done arthroscopically.<sup>31,109</sup> Gooding<sup>40</sup> found that a porcine type I/III collagen membrane showed no improvement over a periosteal membrane.

Rather than simply altering the cultured chondrocyte cover, the latest techniques involve a biodegradable matrix seeded with chondrocytes to cover the defect ("matrix articular cartilage implantation," or MACI). The biological matrix can be composed of a porcine type I/III collagen membrane, polydioxanone/polyglactin, or other material. The matrix should be resorbable, able to be seeded with cultured chondrocytes, and provide a 3-dimensional scaffold that limits chondrocyte hypertrophy. Promising results have been seen in Europe and Australia, where these techniques are most popular.<sup>8,11,66,84,102,131,135</sup> Ossendorf reported on 40 patients who underwent ACI with a polyglactin/polydioxanone matrix scaffold.<sup>104</sup> Cincinnati, Lysholm, Knee Injury and Osteoarthritis Outcome Score (KOOS), and SF-36 knee scores showed significant improvement at 2-year follow-up. Biopsy specimens in 4 patients at 9 and



**Figure 6.** Case study of a high-impact athlete treated with autologous chondrocyte transplantation (**A**). Image taken 4 months after injury for a full-thickness lesion of the weightbearing femoral condyle (**B**). Second-look arthroscopy at 1 year demonstrated complete restoration of the articular cartilage surface (**C**). After returning to high-impact sports at the preinjury level, magnetic resonance imaging evaluation 4 years postoperatively showed a maintained repair cartilage while continuing to participate in high-impact athletics (**D**).

Source: 6A reproduced with permission from Genzyme Biosurgery, Cambridge, MA.

12 months showed evidence of hyaline-like tissue, but this was not quantified. MRI at 6 and 12 months showed good defect filling.

Bartlett compared porcine collagen membrane-ACI to porcine collagen biomatrix-ACI.<sup>8</sup> In 91 patients, both groups showed improvement in Cincinnati Knee Score at 1 year. The 2 techniques showed comparable amounts of hyaline cartilage and graft hypertrophy at 1 year. Although a biomatrix seeded with chondrocytes has the theoretical advantages of less chondrocyte leakage, less graft hypertrophy, and a more even chondrocyte distribution, this has not yet been shown clinically. At the time of this publication, membrane ACI (MACI) techniques are not available for use in the United States.

### Rehabilitation after Cartilage Reconstitution Procedures

Little is known about the optimal rehabilitation protocols after cartilage reconstitution procedures. The phases of rehabilitation in cartilage reconstitution are proliferative, transitional, remodeling, and maturation. Although early motion with progression to closed chain rehabilitation is standard, recommendation regarding the timing of progression can vary greatly due to the significant variation in techniques. Hambly recently reviewed rehabilitation protocols and noted the deficiency in evidence-based evaluations.<sup>46</sup> The ICRS recently met in Zurich, Switzerland, to develop a consensus statement regarding rehabilitation after cartilage reconstitution. Until specific guidelines are developed, it is critical for the surgeon and therapist to communicate regarding the durability of the surgical technique, size and location of the lesion, and specific restrictions for the chosen procedure.

### Future Directions

The future of articular cartilage reconstitution lies in regeneration of tissue. At this time, regeneration involves collecting and culturing chondrocytes with subsequent reimplantation, using a variety of carriers and membranes. Even when successful, chondrocyte implantation results in "hyaline-like" tissue rather than true hyaline tissue, and glycosaminoglycan profiles of the implanted cartilage differ from that of native hyaline tissue.<sup>121</sup> In addition, apoptotic cell death may contribute to delamination of the graft in the setting of chondrocyte implantation.<sup>72</sup>

Based on currently available repair technologies, new approaches are being evaluated that may help to improve quality and quantity of the repair cartilage tissue and overcome the current technical and biologic limitations. Second-generation microfracture techniques may improve stabilization and adhesion of the microfracture clot by using different thrombogenic and adhesive polymers

that also increase mesenchymal cell recruitment and 3-dimensional organization.<sup>51,138</sup> Third-generation ACI techniques have been developed that use implantation of 3-dimensional neocartilage generated from autologous chondrocytes in bioreactors. These techniques can be performed less invasively and may help to accelerate the prolonged postoperative recovery after ACI.<sup>97</sup> Implanting highly productive, selected autologous chondrocytes may help to further increase repair cartilage quality and quantity. In addition, single-step cartilage autograft implantation onto a bioabsorbable scaffold is being evaluated.

Stem cells have the potential to differentiate into chondrocytes under appropriate conditions, potentially with improved cell viability, and are at the forefront of articular cartilage regeneration investigations. Specifically, mesenchymal stem cells (MSCs), found in bone marrow, skin, and adipose tissue, are capable of differentiating into articular cartilage as well as other cells of mesenchymal origin.<sup>71</sup> Hui et al. compared MSC transplants to cultured chondrocytes, osteochondral autograft, and periosteal grafts in animal models of osteochondritis dissecans.<sup>54</sup> Based on histological and biomechanical evaluation, the authors found the MSC transplants to be comparable to cultured chondrocytes and superior to periosteum and osteochondral autograft in their ability to repair chondral defects. Another study found MSCs to be superior to cultured chondrocytes in a rabbit model.<sup>143</sup> MSCs can be attained from a variety of easily accessible sources, including bone marrow,<sup>76</sup> synovium,<sup>125</sup> and adipose tissue.<sup>27</sup> Dragoo found that MSCs derived from adipose tissue predictably healed chondral defects in a rat model.<sup>26</sup> MSCs can be easily obtained and provide significant promise in the future of cartilage tissue engineering.

### Concomitant Procedures

Combined pathology is frequently encountered by the surgeon treating articular cartilage defects in the athletic knee. Malalignment, ligamentous instability, or meniscal injury and deficiency are known to contribute to the development of articular cartilage lesions, and surgically addressing these concomitant pathologies is critical for an effective and durable articular cartilage repair.<sup>83,90</sup> A recent study demonstrated that isolated or combined adjuvant procedures including ACL reconstruction, high tibial osteotomy, or meniscal allograft and repair did not negatively affect the ability to return to athletics after autologous chondrocyte transplantation.<sup>95</sup> Similarly, treatment of associated injuries of menisci or ACL did not influence the recovery time or level of athletic activity after mosaicplasty,<sup>61</sup> and better outcomes have been demonstrated with microfracture in patients who undergo simultaneous ACL reconstruction.<sup>130</sup> This is important

because performing simultaneous adjuvant procedures in the athletic population avoids the prolonged rehabilitation and absence from competition associated with staged procedures, which has been shown to limit the athlete's ability to return to demanding athletic activity.<sup>14,95</sup>

## Summary

Articular cartilage repair in athletes is aimed at returning the athlete to the preinjury level of athletic participation without increased risk for long-term arthritic degeneration. Nutritional supplements may play a role in both the prevention and treatment of articular cartilage injury. Several surgical techniques have been shown to improve function and athletic activity after articular cartilage reconstitution in this population. The rate of improvement and ability to return to athletic activity is dependent on age, length of the preoperative intervals, lesion size, and activity level. Proper rehabilitation is critical to the success of the current surgical techniques. Each technique is associated with specific advantages and limitations, and second-generation techniques are being developed to improve the current shortcomings. Adjuvant procedures to correct concomitant pathology are critical for the success of the articular cartilage repair and do not seem to negatively affect the ability to return to demanding sports. Future directions include regeneration through gene therapy utilizing stem cells. Long-term studies in this population will determine the efficacy of articular cartilage repair to slow or reverse chondropenia and to prevent the development of secondary arthritic degeneration.

## Declaration of Conflicting Interests

The authors declared no potential conflicts of interest with respect to the authorship and/or publication of this article.

## Funding

The authors received no financial support for the research and/or authorship of this article.

## References

- Ahmad CS, Cohen ZA, Levine WN, Ateshian GA, Mow VC. Biomechanical and topographic considerations for autologous osteochondral grafting in the knee. *Am J Sports Med.* 2001;29:201-6.
- Alford JW, Cole BJ. Cartilage restoration, part 2: techniques, outcomes, and future directions. *Am J Sports Med.* 2005;33:443-60.
- Alford JW, Cole BJ. Cartilage restoration, part I: basic science, historical perspective, patient evaluation, and treatment options. *Am J Sports Med.* 2005;33:295-306.
- Arendt E, Dick R. Knee injury patterns among men and women in collegiate basketball and soccer: NCAA data and review of literature. *Am J Sports Med.* 1995;23:694-701.
- Aroen A, Loken S, Heir S, Alvik E, Ekland A, Granlund OG, Engebretsen L. Articular cartilage lesions in 993 consecutive knee arthroscopies. *Am J Sports Med.* 2004;32:211-5.
- Arokoski J, Kiviranta I, Jurvelin J, Tammin M, Helminen HJ. Long-distance running causes site-dependent decrease of cartilage glycosaminoglycan content in the knee joint of beagle dogs. *Arthritis Rheum.* 1993;36:1451-9.
- Barber FA, Chow JCY. Arthroscopic chondral osseous autograft transplantation (COR Procedure) for femoral defects. *Arthroscopy.* 2006;22:10-6.
- Bartlett W, Skinner JA, Gooding CR, Carrington RW, Flanagan AM, Briggs TW, Bentley G. Autologous chondrocyte implantation versus matrix-induced autologous chondrocyte implantation for osteochondral defects of the knee: a prospective, randomized study. *J Bone Joint Surg Br.* 2005;87:640-5.
- Bartz RL, Laudicina L. Osteoarthritis after sports knee injuries. *Clin Sports Med.* 2005;24:39-45.
- Bartz RL, Kamaric E, Noble PC, Lintner D, Bocell J. Topographic matching of selected donor and recipient sites for osteochondral autografting of the articular surface of the femoral condyles. *Am J Sports Med.* 2001;29:207-12.
- Behrens P, Bitter T, Kurz B, Russlies M. Matrix-associated autologous chondrocyte transplantation/implantation (MACT/MACI): 5-year follow-up. *Knee.* 2006;13:194-202.
- Bentley G, Biant LC, Carrington RW, Akmal M, Goldberg A, Williams AM, et al. A prospective, randomised comparison of autologous chondrocyte implantation versus mosaicplasty for osteochondral defects in the knee. *J Bone Joint Surg Br.* 2003;85:223-30.
- Benya PD, Schaffer JD. Dedifferentiated chondrocytes reexpress the differentiated collagen phenotype when cultured in agarose gels. *Cell.* 1982;30:215-24.
- Blevins FT, Steadman JR, Rodrigo JJ, Silliman J. Treatment of articular cartilage defects in athletes: an analysis of functional outcome and lesion appearance. *Orthopedics.* 1998;21:761-8.
- Borazjani BH, Chen AC, Bae WC, Patil S, Sah RL, et al. Effect of impact on chondrocyte viability during insertion of human osteochondral grafts. *J Bone Joint Surg.* 2006;88:1934-43.
- Brittberg M, Lindahl A, Nilsson A, Ohlsson C, Isaksson O, Peterson L. Treatment of deep cartilage defects in the knee with autologous chondrocyte transplantation. *N Engl J Med.* 1994;331:889-95.
- Brown WE, Potter HG, Marx RG, Wickiewicz TL, Warren RF. Magnetic resonance imaging appearance of cartilage repair in the knee. *Clin Orthop.* 2004;422:214-23.
- Buckwalter JA, Mankin HJ. Articular cartilage. Part II: degeneration and osteoarthritis, repair, regeneration, and transplantation. *J Bone Joint Surg Am.* 1997;79:612-32.
- Buckwalter JA. Evaluating methods for restoring cartilaginous articular surfaces. *Clin Orthop.* 1999;367S:S224-38.
- Campbell J, Bellamy N, Gee T. Differences between systematic reviews/meta-analyses of hyaluronic acid/hyaluronan/

- hylan in osteoarthritis of the knee. *Osteoarthritis Cartilage*. 2007;15:1424-36.
21. Chow JCY, Hantes ME, Houle JB, Zalavras CG. Arthroscopic autogenous osteochondral transplantation for treating knee cartilage defects: a 2- to 5-year follow-up study. *Arthroscopy*. 2004;20:681-90.
  22. Church S, Keating JF. Reconstruction of the anterior cruciate ligament: timing of surgery and the incidence of meniscal tears and degenerative change. *J Bone Joint Surg*. 2005;87:1639-42.
  23. Clark KL. Nutritional considerations in joint health. *Clin Sports Med*. 2007;26:101-18.
  24. Curl WW, Krome J, Gordon E, Rushing J, Smith BP, Poehling GG. Cartilage injuries: a review of 31516 knee arthroscopies. *Arthroscopy*. 1997;13:456-60.
  25. Ding C, Cicuttini F, Scott F, Cooley H, Boon C, Jones G. Natural history of knee cartilage defects and factors affecting change. *Arch Int Med*. 2006;166:651-8.
  26. Dragoo JL, Carlson G, McCormick F, Khan-Farooqi, Zhu M, Zuk PA, et al. Healing full-thickness cartilage defects using adipose-derived stem cells. *Tissue Engineering*. 2007;13:1-7.
  27. Dragoo JL, Samimi B, Zhu M, Hame SL, Thomas BJ, Lieberman JR, et al. Tissue-engineered cartilage and bone using stem cells from human infrapatellar fat pads. *J Bone Joint Surg*. 2003;85:740-7.
  28. Drawer S, Fuller CW. Propensity for osteoarthritis and lower limb joint pain in retired professional soccer players. *Br J Sports Med*. 2001;35:402-8.
  29. Drongowski RA, Coran AG, Woitys EM. Predictive value of meniscal and chondral injuries in conservatively treated anterior cruciate ligament injuries. *Arthroscopy*. 1994;10:97-102.
  30. Engstrom B, Forssblad M, Johansson C, Tornkvist H. Does a major knee injury definitely sideline an elite soccer player? *Am J Sports Med*. 1990;18:101-5.
  31. Erggelet C, Sittlinger M, Lahm A. The arthroscopic implantation of autologous chondrocytes for the treatment of full-thickness cartilage defects of the knee joint. *Arthroscopy*. 2003;19:108-10.
  32. Felson DT. Osteoarthritis: new insights. Part 1: the disease and its risk factors. *Ann Intern Med*. 2000;133:635-46.
  33. Ficat RP, Ficat C, Gedeon P, Toussaint JB. Spongialization: a new treatment for diseased patellae. *Clin Orthop*. 1979;144:74-83.
  34. Figueroa D, Calvo R, Vaisman A, Carrasco MA, Moraga C, Delgado I. Knee chondral lesions: incidence and correlation between arthroscopic and magnetic resonance findings. *Arthroscopy*. 2007;23:312-5.
  35. Frisbie DD, Morisset S, Ho C, Rodkey WG, Steadman JR, McIlwraith CW. Effects of calcified cartilage on healing of chondral defects treated with microfracture in horses. *Am J Sports Med*. 2006;34:1824-31.
  36. Fu FH, Zurakowski D, Browne JE, Mandelbaum B, Erggelet C, Moseley JB JR, et al. Autologous chondrocyte implantation versus debridement for treatment of full-thickness chondral defects of the knee. *Am J Sports Med*. 2005;33:1658-66.
  37. Garretson RB III, Katolik LI, Verma N, Beck PR, Bach BR, Cole BJ. Contact pressure at osteochondral donor sites in the patellofemoral joint. *Am J Sports Med*. 2004;32:967-74.
  38. Glaser C, Putz R. Functional anatomy of articular cartilage under compressive loading. *Osteoarthritis and Cartilage*. 2002;10:83-89.
  39. Gobbi A, Nunag P, Malinowski K. Treatment of chondral lesions of the knee with microfracture in a group of athletes. *Knee Surg Sports Traumatol Arthrosc*. 2005;13:213-21.
  40. Gooding CR, Bartlett W, Bentley G, Skinner JA, Carrington R, Flanagan A. A prospective, randomized study comparing two techniques of autologous chondrocyte implantation for osteochondral defects in the knee: periosteum covered versus type I/III covered. *Knee*. 2006;13:203-10.
  41. Gorsline RT, Kaeding CC. The use of NSAIDs and nutritional supplements in athletes with osteoarthritis: prevalence, benefits, and consequences. *Clin Sports Med*. 2005;24:71-82.
  42. Grande DA, Pitman MI, Peterson L, Menche D, Klein M. The repair of experimentally produced defects in rabbit articular cartilage by autologous chondrocyte implantation. *J Orthop Res*. 1989;7:208-18.
  43. Gross A. Fresh osteochondral allograft for posttraumatic knee defects: surgical technique. *Op Tech Orthop*. 1997;7:334-9.
  44. Gudas R, Kelesinskas RJ, Kimtys V, Stankevicius E, Toliusis V, Benotavicius G, Smailys A. A prospective randomized clinical study of mosaic osteochondral autologous transplantation versus microfracture for the treatment of osteochondral defects in the knee joint in young athletes. *Arthroscopy*. 2005;21:1066-75.
  45. Guettler JH, Demetropoulos CK, Yang KH, Jurist KA. Osteochondral defects in the human knee: influence of defect size on cartilage rim stress and load redistribution to surrounding cartilage. *Am J Sports Med*. 2004;32:1451-8.
  46. Hambly K, Bobic V, Wondrasch B, Van Assche D, Marlovitis S. Autologous chondrocyte implantation postoperative care and rehabilitation: science and practice. *Am J Sports Med*. 2006;34:1020-38.
  47. Hangody L, Fule P. Autologous osteochondral mosaicplasty for the treatment of full thickness defects of weight bearing joints: ten years of experimental and clinical experience. *J Bone Joint Surg Am*. 2003;85 Suppl 2:25-32.
  48. Hangody L, Rathonyi GK, Duska Z, Vasarhelyi G, Fules P, Modis L. Autologous osteochondral mosaicplasty: surgical technique. *J Bone Joint Surg Am*. 2004;86 Suppl 1:65-72.
  49. Hefti F, Beguiristain J, Krauspe R, Moller-Madsen B, Riccio V, Tschauer C, et al. Osteochondritis dissecans: a multicenter study of the European Pediatric Orthopedic Society. *J Pediatr Orthop B*. 1999;8:231-45.
  50. Henderson I, Gui J, Lavigne P. Autologous chondrocyte implantation: natural history of postimplantation periosteal

- hypertrophy and effects of repair-site debridement on outcome. *Arthroscopy*. 2006;22:1318-24.
51. Hoemann CD, Hurtig M, Rossomacha E, Sun J, Chevrier A, Shive MS. Chitosan-glycerol phosphate/blood implants improve hyaline cartilage repair in ovine microfracture defects. *J Bone Joint Surg*. 2005;87:2671-86.
  52. Homminga GN, Bulstra SK, Bouwmeester PSM, VanderLinden AJ. Perichondral grafting for cartilage lesions of the knee. *J Bone Joint Surg*. 1990;72:1003-7.
  53. Horas U, Pelinkovic D, Aigner T. Autologous chondrocyte implantation and osteochondral cylinder transplantation in cartilage repair of the knee joint: a prospective comparative trial. *J Bone Joint Surg Am*. 2003;85:185-92.
  54. Hui JH, Chen F, Thambyah A, Lee EH. Treatment of chondral lesions in advanced osteochondritis dissecans: a comparative study of the efficacy of chondrocytes, mesenchymal stem cells, periosteal graft, and mosaicplasty (osteochondral autograft) in animal models. *J Pediatr Orthop*. 2004;24:427-33.
  55. Insall J. The Pridie debridement operation for osteoarthritis of the knee. *Clin Orthop*. 1974;101:61-7.
  56. International Cartilage Repair Society (ICRS) Web site. <http://www.cartilage.org>.
  57. Jackson DW, Lalor PA, Aberman HM, Simon TM. Spontaneous repair of full-thickness defects of articular cartilage in a goat model. *J Bone Joint Surg Am*. 2001;83:53-64.
  58. Jones G, Bennell K, Cicuttini FM. Effect of physical activity on cartilage development in healthy kids. *Br J Sports Med*. 2003;37:382-3.
  59. Jones SJ, Lyons RA, Sibert J, Evans R, Palmer SR. Changes in sports injuries to children between 1983 and 1998: comparison of case series. *J Public Health Med*. 2001;23:268-71.
  60. Kim LS, Axelrod IJ, Howard P, Buratovich N, Waters RF. Efficacy of methylsulfonylmethane (MSM) in osteoarthritis pain of the knee: a pilot clinical trial. *Osteoarthritis Cartilage*. 2006;14:286-94.
  61. Kish G, Modis L, Hangody L. Osteochondral mosaicplasty for the treatment of focal chondral and osteochondral lesions of the knee and talus in the athlete: rationale, indications, technique, and results. *Clin Sports Med*. 1999;18:45-66.
  62. Kiviranta I, Tammi M, Jurvelin J, Arokoski J, Saamanen AM, Helminen HJ. Articular cartilage thickness and glycosaminoglycan distribution in the canine knee joint after strenuous running exercise. *Clin Orthop*. 1992;283:302-8.
  63. Koh J, Wirsing K, Lautenschlager E, Zhang LO. The effect of graft height mismatch on contact pressures following osteochondral grafting. *Am J Sports Med*. 2004;32:317-20.
  64. Koh JL, Kowalski A, Lautenschlager E. The effect of angled osteochondral grafting on contact pressure: a biomechanical study. *Am J Sports Med*. 2006;34:116-9.
  65. Kohn D. Arthroscopy in acute injuries of anterior cruciate-deficient knees: fresh and old intraarticular lesions. *Arthroscopy*. 1986;2:98-102.
  66. Krishnan SP, Skinner JA, Carrington RWJ, Flanagan AM, Briggs TW, Bentley G. Collagen-covered autologous chondrocyte implantation for osteochondritis dissecans of the knee: two- to seven-year results. *J Bone Joint Surg*. 2006;88:203-5.
  67. Krueze PC, Erggelet C, Steinwachs M, Krause SJ, Lahm A, Niemeyer P, et al. Is microfracture of chondral defects in the knee associated with different results in patients aged 40 years or younger? *Arthroscopy*. 2006;22:1180-6.
  68. Krueze PC, Steinwachs M, Erggelet C, Lahm A, Krause S, Ossendorf C, et al. Importance of sports in cartilage regeneration after autologous chondrocyte implantation: a prospective study with a 3-year follow-up. *Am J Sports Med*. 2007;35:1261-8.
  69. Kujala UM, Kettunen J, Paananen H, Aalto T, Battie MC, Impivaara O, et al. Knee osteoarthritis in former runners, soccer players, weight lifters, and shooters. *Arth Rheum*. 1995;38:539-46.
  70. Lane JG, Massie JB, Ball ST, Amiel ME, Chen AC, Bae WC, et al. Follow-up of osteochondral plug transfers in a goat model: a 6-month study. *Am J Sports Med*. 2004;32:1440-50.
  71. Lee EH, Hui JHP. The potential of stem cells in orthopaedic surgery. *J Bone Joint Surg*. 2006;88:841-51.
  72. Lee JH, Prakash KVB, Pengatteeri YH, Park SE, Koh HS, Han CW. Chondrocyte apoptosis in the regenerated articular cartilage after allogenic chondrocyte transplantation in the rabbit knee. *J Bone Joint Surg*. 2007;89:977-83.
  73. Levy AS, Lohnes J, Sculley S, LeCrow M, Garrett W. Chondral delamination of the knee in soccer players. *Am J Sports Med*. 1996;24:634-39.
  74. Lexar E. Substitution of whole or half joints from freshly amputated extremities by free plastic operation. *Surg Gynecol Obstet*. 1908;6:601-7.
  75. Liu G, Kawaguchi H, Ogasawara T, Asawa Y, Kishimoto J, Takahashi T, et al. Optimal combination of soluble factors for tissue engineering of permanent cartilage from cultured human chondrocytes. *J Biol Chem*. 2007;282:20407-15.
  76. Liu Y, Shu XZ, Prestwich GD. Osteochondral defect repair with autologous bone marrow-derived mesenchymal stem cells in an injectable, in situ, cross-linked synthetic extracellular matrix. *Tissue Eng*. 2006;12:3405-16.
  77. Lohmander LS, Roos H, Dahlberg L, Hoerner LA, Lark MW. Temporal patterns of stromelysin, tissue inhibitor and proteoglycan fragments in synovial fluid after injury to the knee cruciate ligament or meniscus. *J Orthop Res*. 1994;12:21-8.
  78. Magnusson PB. Technique of debridement of the knee joint for arthritis. *Surg Clin North Am*. 1946;26:226-49.
  79. Maletius W, Messner K. The long-term prognosis for severe damage to the weightbearing cartilage in the knee: a 14-year clinical and radiographic follow-up in 28 young athletes. *Acta Orthop Scand*. 1996;67:165-8.
  80. Malinin T, Temple HT, Buck BE. Transplantation of osteochondral allografts after cold storage. *J Bone Joint Surg*. 2006;88:762-70.

81. Mandelbaum B, Browne JE, Fu F, Micheli LJ, Moseley JB, Erggelet C, et al. Treatment outcomes of autologous chondrocyte implantation for full-thickness articular cartilage defects of the trochlea. *Am J Sports Med.* 2007;35:915-21.
82. Mandelbaum BR, Waddell D. Etiology and pathophysiology of osteoarthritis. *Orthopedics.* 2005;28:1-8.
83. Mandelbaum BT, Browne JE, Fu F, Micheli J, Mosley JB, Erggelet C, et al. Articular cartilage lesions of the knee. *Am J Sports Med.* 2000;26:853-61.
84. Marcacci M, Berruto M, Brocchetta D, Delcogliano A, Ghinelli D, Gobbi A, et al. Articular cartilage engineering with Hyalograft C. *Clin Orthop.* 2005;435:96-105.
85. Marcacci M, Kon E, Delcogliano M, Filardo G, Busacca M, Zaffagnini S. Arthroscopic autologous osteochondral grafting for cartilage defects of the knee: prospective study results at a minimum 7-year follow-up. *Am J Sports Med.* 2007;35:2014-21.
86. Marcacci M, Kon E, Zaffagnini S, Iacono F, Neri MP, Vascellari A, et al. Multiple osteochondral arthroscopic grafting (mosaicplasty) for cartilage defects of the knee: prospective study results at 2-year follow-up. *Arthroscopy.* 2005;21:462-70.
87. Marder RA, Hopkins G, Timmerman L. Arthroscopic microfracture of chondral defects of the knee: a comparison of two postoperative treatments. *Arthroscopy.* 2005;21:152-8.
88. McAlindon TE, LaValley MP, Gulin JP, Felson DT. Glucosamine and chondroitin for treatment of osteoarthritis: a systematic quality assessment and meta-analysis. *JAMA.* 2000;283:1469-75.
89. McCulloch PC, Kang RW, Sobhy MH, Hayden JK, Cole BJ. Prospective evaluation of prolonged fresh osteochondral allograft transplantation of the femoral condyle: minimum 2-year follow-up. *Am J Sports Med.* 2007;35:411-20.
90. Minas T. The role of cartilage repair techniques, including chondrocyte transplantation, in focal chondral knee damage. *Instr Course Lect.* 1999;48:629-43.
91. Mithöfer K, Williams RJ III, Warren RF, Wichiewicz TL, Marx RF. High-impact athletics after knee articular cartilage repair. *Am J Sports Med.* 2006;34:1413-8.
92. Mithöfer K, Williams RJ, Warren RF, Potter HG, Spock CR, Jones BC, et al. Chondral resurfacing of articular cartilage defects in the knee with the microfracture technique. *J Bone Joint Surg.* 2006;88:294-305.
93. Mithöfer K, Steadman JR. The microfracture technique. *Tech Knee Surg.* 2006;5:140-8.
94. Mithöfer K, Williams RJ, Warren RF, Potter HG, Spock CR, Jones EC, et al. The microfracture technique for treatment of articular cartilage lesions in the knee: a prospective cohort evaluation. *J Bone Joint Surg.* 2005;87:1911-20.
95. Mithöfer K, Peterson L, Mandelbaum BR, et al. Articular cartilage repair in soccer players with autologous chondrocyte transplantation: functional outcome and return to competition. *Am J Sports Med.* 2005;33:1639-46.
96. Mithöfer K, Minas T, Peterson L, et al. Functional outcome of articular cartilage repair in adolescent athletes. *Am J Sports Med.* 2005;3:1147-53.
97. Mizuno S, Alleman F, Glowacki J. Effects of medium perfusion on matrix production by bovine chondrocytes in three-dimensional collagen sponges. *J Biomed Mater Res.* 2001;56:368-75.
98. Moti AW, Micheli LJ. Meniscal and articular cartilage injury in the skeletally immature knee. *Instr Course Lect.* 2003;52:683-90.
99. Najm WI, Reinsch S, Hoehler F, Tobis JS, Harvey PW. S-adenosyl methionine (SAME) versus celecoxib for the treatment of osteoarthritis symptoms: a double-blind crossover trial. *BMC Muscul Disord.* 2004;5:6.
100. Nam EK, Makhsous M, Koh J, Bowen M, Nuber G, Zhang LQ. Biomechanical and histological evaluation of osteochondral transplantation in a rabbit model. *Am J Sports Med.* 2004;32:308-16.
101. Nebelung W, Wuschech H. Thirty-five years of follow-up of anterior cruciate ligament-deficient knees in high-level athletes. *Arthroscopy.* 2005;21:696-702.
102. Nehrer S, Domayer S, Dorotka R, Schatz K, Bindreiter U, Kotz R. Three-year clinical outcome after chondrocyte transplantation using a hyaluronan matrix for cartilage repair. *Eur J Rad.* 2006;57:3-8.
103. Ogilvie-Harris DJ, Jackson RW. The arthroscopic treatment of chondromalacia patella. *J Bone Joint Surg.* 1984;66:660-5.
104. Ossendorf C, Kaps C, Kreuz PC, Burmester GR, Sittinger M, Erggelet C. Treatment of posttraumatic and focal osteoarthritic cartilage defects of the knee with autologous polymer-based three-dimensional chondrocyte grafts: 2-year clinical results. *Arthrit Res Ther.* 2007;9:1-11.
105. Outerbridge RE. The etiology of chondromalacia patellae. *J Bone Joint Surg.* 1961;43:752-67.
106. Pearce SG, Hurtig MB, Clarnette R, Kalra M, Cowan B, Miniaci A. An investigation of 2 techniques for optimizing joint surface congruency using multiple cylindrical osteochondral autografts. *Arthroscopy.* 2001;17:50-5.
107. Pearle AD, Warren RF, Rodeo SA. Basic science of articular cartilage and osteoarthritis. *Clin Sports Med.* 2005;24:1-12.
108. Peterson L, Brittberg M, Kiviranta I, Akerlund EL, Lindahl A. Autologous chondrocyte transplantation: biomechanics and long-term durability. *Am J Sports Med.* 2002;30:2-12.
109. Petersen W, Zelle S, Zantop T. Arthroscopic implantation of a three dimensional scaffold for autologous chondrocyte transplantation. *Arch Orthop Trauma Surg.* 2008;128:505-8.
110. Piasecki DD, Spindler KP, Warren TA, Andrich JT, Parker RD. Intraarticular injuries associated with anterior cruciate ligament tear: findings at ligament reconstruction in high school and recreational athletes. *Am J Sports Med.* 2003;31: 601-5.
111. Potter HG, Foo LF. Magnetic resonance imaging of articular cartilage. *Am J Sports Med.* 2006;34:661-7.

112. Potter HG, Linklater JM, Allen AA, Hannafin JA, Haas SB. Magnetic resonance imaging of articular cartilage in the knee. *J Bone Joint Surg Am.* 1998;80:1276-84.
113. Pridie KH. A method of resurfacing osteoarthritic knee joints. *J Bone Joint Surg.* 1959;41:618-9.
114. Rae PJ, Noble J. Arthroscopic drilling of osteochondral lesions of the knee. *J Bone Joint Surg.* 1989;71:534-41.
115. Reddy S, Pedowitz DI, Parekh SG, Sennett BJ, Okereke E. The morbidity associated with osteochondral harvest from asymptomatic knees for the treatment of osteochondral lesions of the talus. *Am J Sports Med.* 2007;35:80-5.
116. Rodrigo JJ, Steadman RJ, Silliman JF. Improvement of full-thickness chondral defect healing in the human knee after debridement and microfracture using continuous passive motion. *Am J Knee Surg.* 1994;7:109-16.
117. Roos EM, Dahlberg L. Positive effects of moderate exercise on glycosaminoglycan content in knee cartilage. *Arthritis Rheum.* 2005;52:3507-14.
118. Roos H, Lindberg H, Ornell M. Soccer as a cause of hip and knee osteoarthritis. *Ann Rheum Dis.* 1996;55:690-8.
119. Roos H. Are there long-term sequelae from soccer? *Clin Sports Med.* 1998;17:819-83.
120. Schonholtz GJ, Ling B. Arthroscopic chondroplasty of the patella. *Arthroscopy.* 1985;1:92-6.
121. Sharma A, Wood LD, Richardson JB, Roberts S, Kuiper NJ. Glycosaminoglycan profiles of repair tissue formed following autologous chondrocyte implantation differ from control cartilage. *Arthritis Res Ther.* 2007;9:R79.
122. Shelbourne KD, Jari S, Gray T. Outcome of untreated traumatic articular cartilage defects of the knee: a natural history study. *J Bone Joint Surg Am.* 2003;85 Suppl 2:8-16.
123. Shintani N, Kurth T, Hunziker EB. Expression of cartilage-related genes in bovine synovial tissue. *J Orthop Res.* 2007;25:813-9.
124. Skoog T, Johansson SH. The formation of articular cartilage from free perichondrial grafts. *Plast Reconstr Surg.* 1976;57:1-6.
125. Smith AD, Tao SS. Knee injuries in young athletes. *Clin Sports Med.* 1995;14:629-50.
126. Smith-Peterson MN. Evolution of mould arthroplasty of the hip joint. *J Bone Joint Surg.* 1948;30:59-75.
127. Sprague NF 3rd. Arthroscopic debridement for degenerative knee joint disease. *Clin Orthop Relat Res.* 1981;160:118-23.
128. Steadman JR, Rodkey WG, Singleton SB. Microfracture technique for full thickness chondral defects: technique and clinical results. *Oper Tech Orthopedics.* 1997;7:300-4.
129. Steadman JR, Briggs KK, Rodrigo JJ, Kocher MS, Gill TJ, Rodkey WG. Outcomes of microfracture for traumatic chondral defects of the knee: average 11-year follow-up. *Arthroscopy.* 2003;19:477-84.
130. Steadman JR, Miller BS, Karas SG, Schlegel TF, Briggs KK, Hawkins RJ. The microfracture technique in the treatment of full-thickness chondral lesions of the knee in National Football League players. *J Knee Surg.* 2003;16:83-6.
131. Steinwachs M, Kreuz PC. Autologous chondrocyte implantation in chondral defects of the knee with a type I/III collagen membrane: a prospective study with a 3-year follow-up. *Arthroscopy.* 2007;23:381-7.
132. Stone KR, Walgenbach AW, Freyer A, Turek TJ, Speer DP. Articular cartilage paste grafting to full-thickness articular cartilage knee joint lesions: a 2- to 12-year follow-up. *Arthroscopy.* 2006;22:291-9.
133. Theosakis J, Adderly B, Fox B. The arthritis cure: the medical miracle that can halt, reverse, and may even cure osteoarthritis. Vol. XVI. 1st ed. New York: St. Martin's Press; 1997.
134. Towheed TE. Current status of glucosamine therapy in osteoarthritis. *Arthritis Rheum.* 2003;49:601-4.
135. Trattnig S, Pinker K, Drestan C, Plank C, Millinton S, Marlavits S. Matrix-based autologous chondrocyte implantation for cartilage repair with Hyalograft C: two-year follow-up by magnetic resonance imaging. *Eur J Rad.* 2006;57:9-15.
136. Victor von Engelhardt L, Kraft CN, Pennekamp PH, Schild HH, Schmitz A, von Falkenhausen M. The evaluation of articular cartilage lesions of the knee with a 3-tesla magnet. *Arthroscopy.* 2007;23:496-502.
137. Vrahas MS, Mithoefer K, Joseph D. Long-term effects of articular impaction. *Clin Orthop.* 2004;423:40-3.
138. Wang DA, Varghese S, Sharma B, Strehin I, Fermanian S, Gorham J. Multifunctional chondroitin sulphate for cartilage tissue-biomaterial integration. *Nat Mater.* 2007;6:385-92.
139. Wang CT, Lin J, Chang CJ, Lin YT, Hou SM. Therapeutic effects of hyaluronic acid on osteoarthritis of the knee: a meta-analysis of randomized controlled trials. *J Bone Joint Surg.* 2004;86:538-55.
140. Williams RJ, Ranawat AS, Potter HG, Carter T, Warren RF. Fresh stored allografts for the treatment of osteochondral defects of the knee. *J Bone Joint Surg.* 2007;89:718-26.
141. Williams SK, Amiel D, Ball ST, Allen RT, Wong VW, Chen AC, et al. Prolonged storage effects on the articular cartilage of fresh human osteochondral allografts. *J Bone Joint Surg.* 2003;85:2111-20.
142. Wood JJ, Malek MA, Frassica FJ, Polder JA, Mohan AK, Bloom ET, et al. Autologous cultured chondrocytes: adverse events reported to the United States Food and Drug Administration. *J Bone Joint Surg.* 2006;88:503-7.
143. Yan H, Yu C. Repair of full-thickness cartilage defects with cells of different origin in a rabbit model. *Arthroscopy.* 2007;23:178-87.