



Low-dose ultraviolet-B irradiation of donor corneal endothelium and graft survival

Citation

Dana, Mohamad R., Steven T. Olkowski, Houshang Ahmadian, Walter J. Stark, and Elaine M. Young. 1990. "Low-dose ultraviolet-B irradiation of donor corneal endothelium and graft survival." *Investigative Ophthalmology & Visual Science* 31, no.11: 2261-2268.

Permanent link

<http://nrs.harvard.edu/urn-3:HUL.InstRepos:34721609>

Terms of Use

This article was downloaded from Harvard University's DASH repository, and is made available under the terms and conditions applicable to Other Posted Material, as set forth at <http://nrs.harvard.edu/urn-3:HUL.InstRepos:dash.current.terms-of-use#LAA>

Share Your Story

The Harvard community has made this article openly available.
Please share how this access benefits you. [Submit a story](#).

[Accessibility](#)

Low-Dose Ultraviolet-B Irradiation of Donor Corneal Endothelium and Graft Survival

Mohamad R. Dana, Steven T. Olkowski, Houshang Ahmadian, Walter J. Stark, and Elaine M. Young

Donor rabbit corneal endothelium was pretreated with different doses of ultraviolet (UV-B) irradiation (302 nm) before grafting to test whether allograft survival could be favorably affected in comparison with untreated corneas grafted into the same recipients. Endothelial rejection was observed in 19 of 32 (59%) eyes that received no treatment compared with five of 32 (16%) eyes that received UV-B ($P < 0.001$), and increasing doses of UV-B were associated with lower rejection rates ($P < 0.05$). Although exposure of donor endothelium significantly reduced endothelial rejection at all doses tested, it resulted in primary graft failure in a substantial proportion of corneas treated at high doses. Class II (Ia) antigen staining of corneal tissue was present in conjunction with clinical evidence of rejection, and the magnitude of staining correlated with the histologic extent of inflammation. Scanning electron microscopy revealed various endothelial cell surface irregularities and membrane defects in high-dose UV-treated corneas. Endothelial cell cultures exposed in vitro to UV-B light showed a dose-dependent loss in cell viability. These data suggest that UV-B pretreatment of donor corneal endothelium prolongs graft survival but that toxic side effects must be carefully controlled. Invest Ophthalmol Vis Sci 31:2261-2268, 1990

Extensive literature on the immunosuppressive effects of ultraviolet (UV) radiation (200–400 nm) suggests that it may modify the functional behavior of immunocompetent cells without killing them.¹⁻³ Possible application to transplantation has generated much interest.^{4,5} Exposure of rat pancreatic islet cells to UV light before experimental transplantation was used to prolong islet allograft survival without immunosuppression of the host,⁶ and applications to keratoplasty in the murine model have been reported.^{7,8}

The mechanism by which UV radiation modifies immunogenicity is not completely understood. The major donor antigens which trigger allograft rejection are believed to be coded for by the major histocompatibility complex (MHC) antigens, especially those of the Class II region.^{9,10} Furthermore, it is generally believed that although the Langerhans' cells of the corneal limbus possess Class II antigens,¹¹ the epithelial, stromal, and endothelial cells themselves do not express these antigens¹²⁻¹⁴ unless induced to do so by exposure to mediators such as gamma interferon.¹⁵ For this reason, much of the current literature on the immunosuppressive effect of UV has focused on modification of the Class II-expressing antigen-pre-

senting cells. Some investigators suggest that the sensitivity of Langerhans' cells to UV may abrogate their antigen-presenting function.¹⁶⁻²⁰ Others suggest that the production of a tolerogenic signal that activates donor-specific suppressor cells is responsible for UV-induced immunosuppression.^{21,22}

The applicability of UV to transplantation is limited by its well-documented ocular toxic effects. Severe damage to the corneal epithelium occurs with exposures of 50 mJ/cm² at 300 nm in vivo,^{23,24} and the threshold level of UV-B sufficient to disturb deturgescence of the endothelium in vivo is 120 mJ/cm² at 305 nm²⁵ from the anterior surface of the cornea. The UV-induced endothelial structural alterations have also been described in scanning electron microscopic studies,²⁶ but it is difficult to quantitate the true effect of UV on the endothelium because the energy reaching that layer is governed by absorption in the anterior and midcorneal layers.

Because destruction of allograft endothelium is the most important prognosticator for graft rejection, we tested direct treatment of donor endothelium with UV-B (302 nm) to see whether allograft survival could be prolonged. In addition, we examined irradiated corneas for subsequent Class II antigen expression and morphologic alterations to corroborate our clinical observations.

Materials and Methods

All procedures conformed to the ARVO Resolution on the Use of Animals in Research.

From the Wilmer Eye Institute, The Johns Hopkins School of Medicine, Baltimore, Maryland.

Supported in part by National Institutes of Health Grants EY-01765, EY-03999, and RR-04060.

Reprint requests: Dr. Mohamad Dana, Department of Ophthalmology, The Illinois Eye & Ear Infirmary, 1855 West Taylor Street, Chicago, IL 60612.

Clinical Protocol

Normal young adult New Zealand white and pigmented rabbits (Bunnyville, Littlestown, PA) served as donor and recipient pairs. One pigmented and one white rabbit were anesthetized, and two 7.5-mm central full-thickness corneal buttons were excised from each animal. One button was placed endothelial-side up in a tissue culture dish containing M-K medium without phenol red and exposed to a UV-B light source (model UVM-57, 298–305 nm range with peak at 302 nm; UVP, San Gabriel, CA) at a distance of 12.5 cm from the source for 1.5, 2.0, 2.5, or 5.0 min (67, 90, 110, and 220 mJ/cm²). Irradiance was calibrated with a UVX-31 digital radiometer (UVP) equipped with a sensor to record radiation at a peak of 302 nm. The second donor button was not irradiated. Both corneas were then orthotopically grafted into the opposite recipient animal so that each animal received one irradiated and one unirradiated button. To insure high rejection rates in a relatively short period of time, 10–0 nylon sutures were left in place for the duration of the study to stimulate a vascular response, and animals were not immunosuppressed. Each eye was examined by slit-lamp microscopy twice weekly until the animals were killed for signs of rejection in any of the corneal layers. The clarity of the graft was noted, and the presence of an endothelial line or keratic precipitate was recorded (Fig. 1). With the exception of four animals killed 1 week after they had rejected both grafts (bilaterally), all animals, except two, were killed on postoperative day 65. Two were randomly selected and followed for 120 days to observe any change in their clinical outcome after postoperative day 65. In all cases, there was no change in the grafts' rejection status after postoperative day 50. Since a period of graft transparency is a requirement for making the diagnosis of graft rejection, any cloudiness that developed in the immediate postoperative period (less than 7 days) was defined as primary graft failure.

Scanning Electron Microscopy and Immunohistochemical Staining

Corneas from killed rabbits were placed into 3% glutaraldehyde for scanning electron microscopy (model #840; JEOL, Peabody, MA). Other sections were snap-frozen in liquid nitrogen and cut into 6- μ m sections (Frigocut 2800N microtome, Reichert-Jung, Deerfield, IL) for analysis of Class II antigens. An ungrafted, normal rabbit cornea (negative) and normal rabbit lymph node (positive) were used as controls. Sections were stained by the avidin-biotin-peroxidase complex (ABC) system,^{27,28} using the Vectastain ABC kit protocol (Vector, Burlingame, CA),

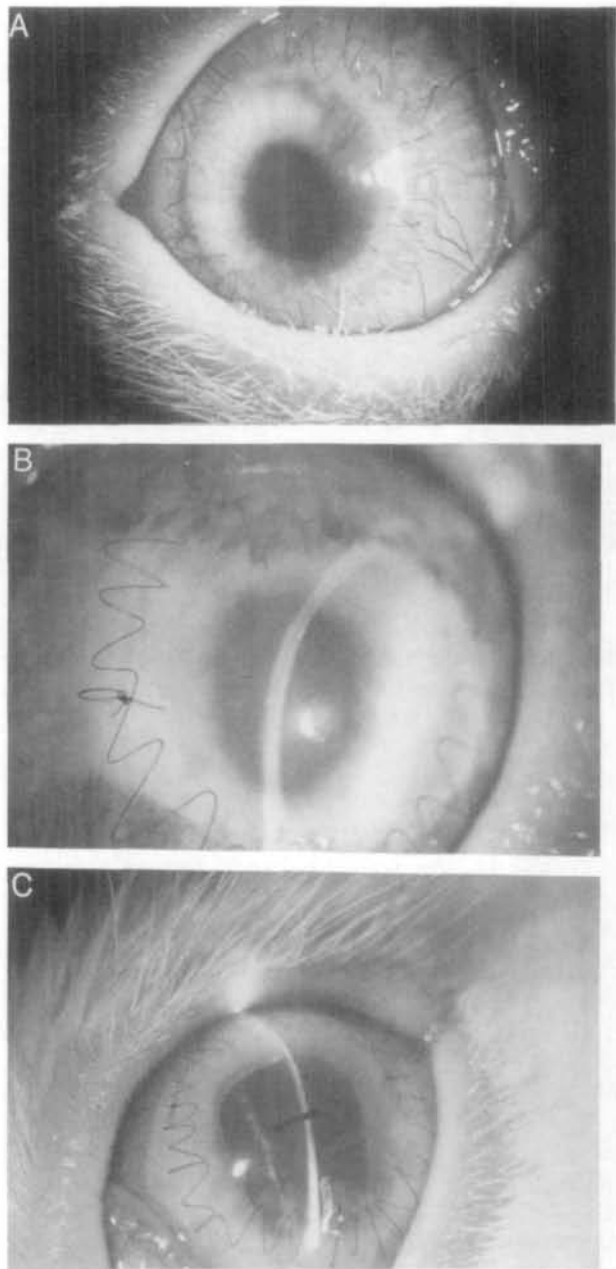


Fig. 1. (A) Corneal allograft treated with 110 mJ/cm² of UV-B irradiation is clear on postoperative day 20. (B) Corneal allograft treated with 110 mJ/cm² of UV-B reveals a stromal haze and vascular ingrowth into the superficial stroma on postoperative day 17. (C) Untreated corneal graft reveals an isolated endothelial layer rejection line (arrow) on postoperative day 38.

with a final peroxide concentration of 0.015%. Class II antigen expression was assessed using a mouse monoclonal antibody which detects an isotopic determinant on rabbit Ia molecules.²⁹ The clone (2C4.B12) was provided by Dr. K. L. Knight, University of Illinois, Chicago, IL. Antibody was prepared, affinity purified, concentrated to 1 mg/ml, and diluted 1:30 just before use. Anti-human T-cell anti-

body (Leu 4; Becton-Dickinson, Mt. View, CA) was diluted 1:30 and used as a negative control. Sections were analyzed and graded microscopically for the presence and distribution of Ia⁺ and endogenous peroxidase⁺ cells.

UV Treatment of Endothelial Cell Cultures

Normal, ungrafted outbred New Zealand white rabbits were killed, and their eyes were harvested immediately. The central cornea was removed under sterile conditions, sectioned into six pieces, and placed endothelial-side down in 60-mm tissue culture dishes (Corning, Corning, NY). Sections were allowed to adhere for 15 min, then one to two drops of growth medium was placed on each section (Dulbecco's modified Eagle's medium, supplemented with 10% fetal bovine serum, 2 mM glutamine, 100 units/ml penicillin, and 100 µg/ml streptomycin; Gibco, Grand Island, NY). On the next day, 4 ml of medium was added to each plate, and cultures were incubated at 37°C in 5% CO₂. At 1 week, tissue was removed, cultures were grown to confluency, and duplicate cultures in M-K medium without phenol red were exposed to 0.5, 1.0, 1.5, 2.0, 2.5, or 5.0 min (22, 45, 67, 90, 110, and 220 mJ/cm²) of UV-B light according to the clinical protocol. Control plates were not irradiated. After exposure, all plates were washed once with phosphate-buffered saline and fed as usual. After overnight incubation, the cultures were examined with an inverted microscope for cell death and changes in morphology. They were then trypsinized, washed, and counted in trypan blue. All cultures were reseeded at known concentration, cultured for an additional 3 days, trypsinized, and counted again to establish growth kinetics. Cultured endothelial cells were also stained for Class II expression as previously described.³⁰

Statistical Analysis

The chi-square test for homogeneity of proportions was used to determine whether the rejection status of

Table 1. Dose effect of UV-B irradiation of donor corneal endothelium on rejection

Donor pretreatment	No.	Endothelial rejection
		No. (%)
Not irradiated	32	19 (59)
Irradiated		
67 mJ/cm ²	6	1 (17)
90 mJ/cm ²	6	0 (0)
100 mJ/cm ²	14	3 (21)
220 mJ/cm ²	6	1 (17)
Total irradiated	32	5 (16)

Table 2. Rates of endothelial rejection as a function of UV-B (302 nm) irradiation in pigmented and white rabbits

	Recipient rabbits		
	Pigmented (n = 16)	White (n = 16)	Total (n = 32)
Allografts with no UV-B pretreatment (n = 32)	0.44	0.75	0.59
Allografts with UV-B pretreatment (n = 32)	0.19	0.13	0.16
Total	0.31	0.44	0.75

one graft significantly affected the rejection status of the contralateral graft. The sign test, a binomial model for calculating the distribution of outcomes among discordant pairs, was used to test for significant differences between the rejection rates of irradiated and unirradiated corneas. Finally, a probit model was applied to examine the dose-response relationship between the dose of UV-B, the probability of rejection, and the in vitro viability of cultured endothelial cells.

Results

Clinical

As shown in Table 1, endothelial rejection was observed in 19 of 32 unirradiated corneas compared with five of 32 grafts which received pretreatment with UV-B ($P < 0.001$). The prevalence of endothelial rejection showed an inverse relationship to the dose of UV exposure between 0–90 mJ/cm², but then increased to approximately 20% for doses between 110–220 mJ/cm². Because of small sample sizes, there was no statistically significant difference in the rates of rejection between any two doses tested; however, the application of a probit response model to all available data revealed that, taken as a whole, the effect of increasing dose was significant ($z = 2.77$, $P < 0.05$) in decreasing the probability of rejection. The probability of endothelial rejection of one allograft was not significantly altered by the clinical outcome of the contralateral button ($P = 0.64$).

Recipient animals were divided equally between white and pigmented rabbits. The overall rejection rate among pigmented recipients was 31% compared with 44% among white recipients (Table 2). Despite comparable rejection rates of irradiated allografts between the two subgroups (19% and 13%), the rejection rate of unirradiated grafts by white rabbits (75%) greatly exceeded that observed among pigmented recipients (44%). Although rejection of treated corneas was substantially lower than rejection of untreated

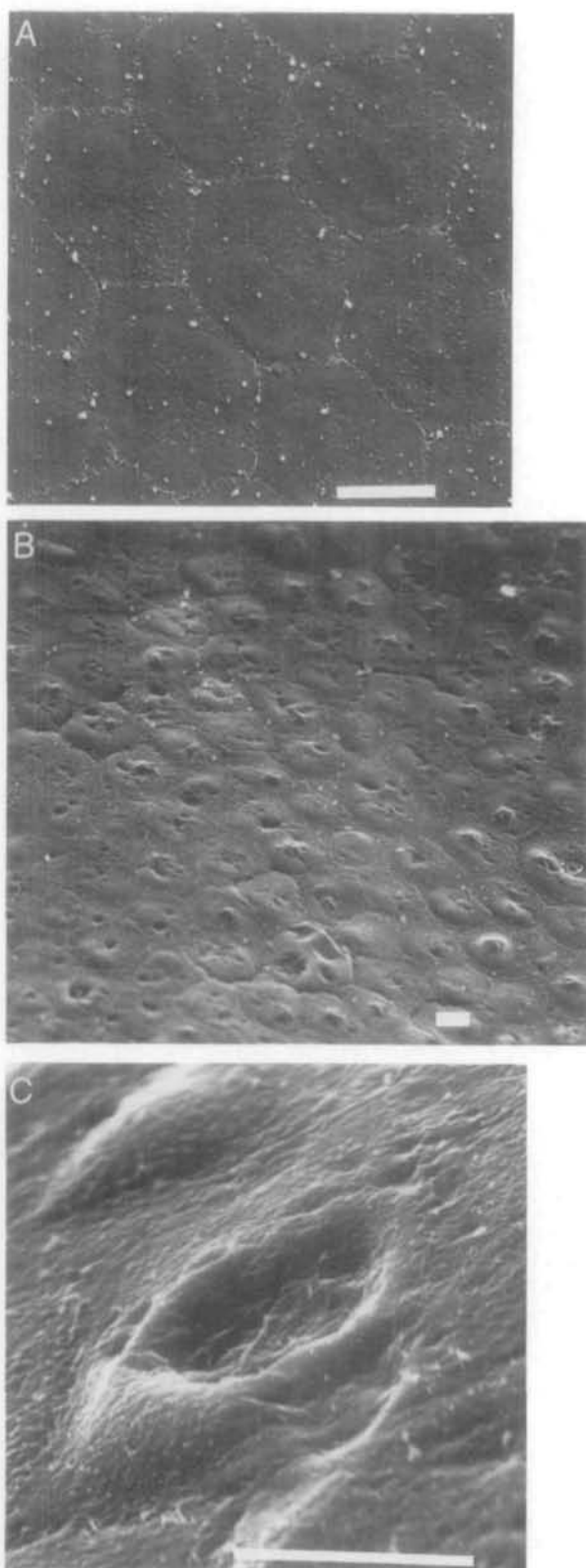


Fig. 2. (A) Scanning electron micrograph of untreated and nonrejected donor button reveals normal endothelial cell layer on postoperative day 65. (Bar equals 10 μm .) (B) Scanning electron micrograph of nonrejected corneal button pretreated with 200 mJ/cm^2 of UV-B demonstrating widespread cell surface irregularities on postoperative day 65. (Bar equals 10 μm .) (C) Higher mag-

eyes in both subgroups, the difference was not statistically significant in the pigmented group ($P = 0.11$).

Fifty percent of treated eyes and 34% of untreated eyes showed epithelial or stromal rejection. The endothelial layer in all of these cases was spared with the exception of one untreated allograft which exhibited rejection in all three layers. It was not possible to determine conclusively if exposure of donor endothelium to 220 mJ/cm^2 abrogated endothelial rejection, since one half of those corneas suffered primary graft failure.

Histopathology and Immunohistochemistry

Scanning electron microscopy revealed only minimal differences between corneal endothelia treated with low-dose UV-B radiation (110 mJ/cm^2 or less) and untreated corneas. In contrast, cell surface irregularities ranging from small microvillouslike projections to large membrane defects were prominent among endothelial cells receiving 220 mJ/cm^2 (Fig. 2) regardless of the clinical outcome of the graft.

Staining for Class II antigen was restricted to those layers of the allografts with clinical signs of rejection (Fig. 3), except for the occasional staining of a few cells in the epithelium of even clear grafts. Class II antigens were most marked in the stromal layer of rejected allografts, particularly in conjunction with the presence of inflammatory cells in the incision area (Fig. 4).

Negative controls (incubated with anti-Leu 4) revealed an influx of mononuclear endogenously peroxidase⁺ cells around the wound and sutures. Similar to our findings with Class II antigen expression, the numbers of these cells correlated strongly with histologic evidence of inflammation. These endogenously positive cells were absent from both ungrafted buttons and clear allografts (Fig. 5).

Normal rabbit lymph nodes showed typical Class II antigen expression in the medulla and cortex and peroxidase⁺ cells in the deep medullary and parafollicular regions (data not shown).

Endothelial Cell Cultures

Examination of endothelial cell cultures exposed to UV-B radiation revealed a significant loss in the number of viable cells compared with unirradiated cell cultures (Table 3). Linear regression analysis (of three separate experiments) showed significant loss of cells in direct correlation with increasing doses of

nification of endothelial layer shown in Figure 2B reveals cell with large membrane defect (Bar equals 10 μm .)

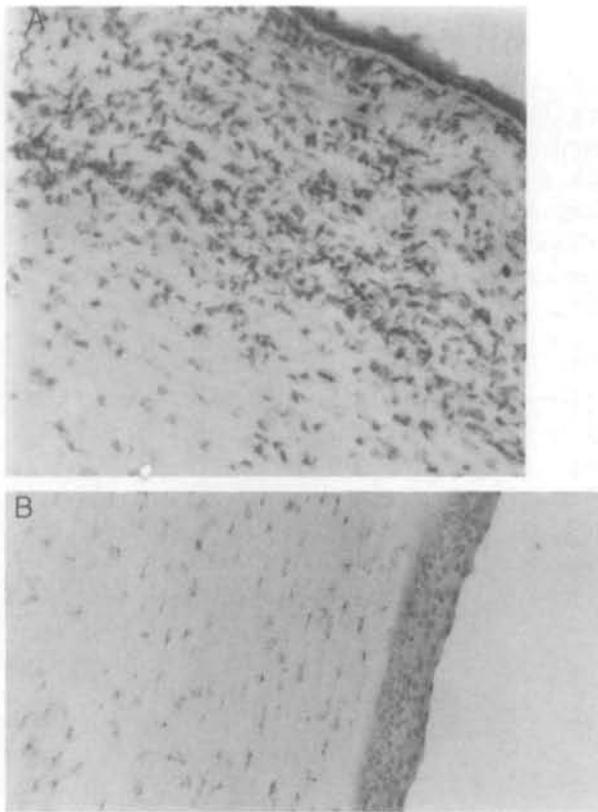


Fig. 3. (A) Photomicrograph of untreated corneal allograft with clinical signs of rejection in three layers, exhibiting staining for Class II antigen in the superficial stroma on postoperative day 65 (original magnification $\times 100$). (B) Clinically clear UV-treated allograft reveals no Class II antigen expression on postoperative day 65 (original magnification $\times 100$).

UV-B ($P = 0.009$); this was most evident after 3 days of incubation. Cultured endothelial cells stained for Class II antigen expression were negative under all test conditions.

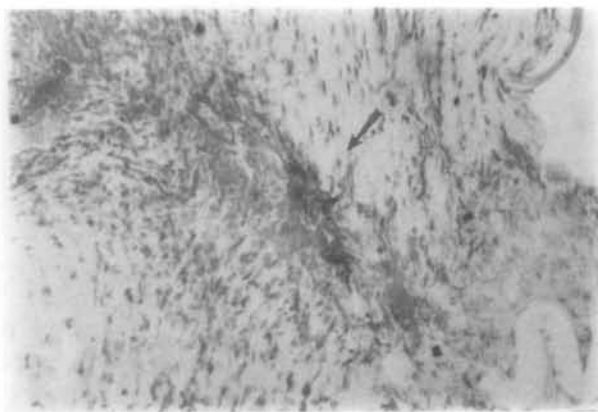


Fig. 4. Photomicrograph of untreated corneal graft with clinical signs of stromal rejection reveals leukocytic infiltration of the surgical wound area (arrow) associated with dense staining for Class II antigens on postoperative day 65 (original magnification $\times 100$).

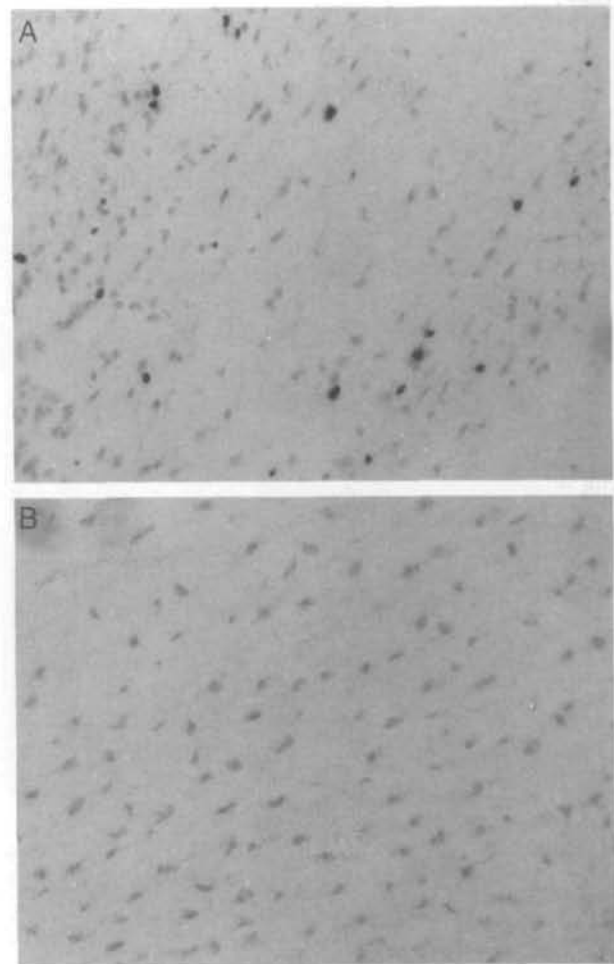


Fig. 5. (A) Numerous strongly stained peroxidase⁺ cells present in the stroma of stromally rejecting untreated graft on postoperative day 65 (original magnification $\times 100$). (B) Clear irradiated graft reveals no peroxidase⁺ cells in the stroma on postoperative day 65 (original magnification $\times 100$).

Discussion

We showed that treatment of rabbit donor corneal tissue with UV-B radiation before grafting results in a significant reduction in the incidence of endothelial rejection. The reduction in the rejection rate observed in pigmented rabbits was not statistically sig-

Table 3. Representative experiment of the effect of UV-B (302 nm) irradiation on viability of cultured rabbit corneal endothelial cells

Dosage		No. of viable cells	
Minutes	mJ/cm ²	Following overnight incubation	Following 3-day incubation
0	0	8.5×10^5	9.5×10^5
1.0	45	7.0×10^5	4×10^5
2.5	110	3.5×10^5	0
5.0	220	2.5×10^5	0

nificant because of small sample size and a lower rate of rejection in control eyes. This explains why an odds ratio of 2.3 (for rejection of untreated compared with UV-B-treated allografts) among the pigmented recipients was not statistically significant; a ratio of 5.8 was significant for the white rabbits. Our major conclusions are based on the clinical outcome of the 32 allografts treated with UV-B compared with the 32 untreated grafts. Application of a statistical-response model to our data revealed that the effect of increasing dose was statistically significant in decreasing the rate of endothelial rejection despite an observed relative increase in the rejection rate at doses above 90 mJ/cm².

Our conclusions agree with previous studies; these reported a reduction in the incidence of rejection of mouse heterotopic corneal allografts by *in vitro* pretreatment of the grafts with UV light.⁷ These authors suggested that the sparing of the allograft was related to the depletion or alteration of Langerhans' cells residing in the epithelium.

Although the "passenger leukocyte" hypothesis is an attractive model in relating initial allogeneic recognition facilitated by the donor antigen-presenting cell, there are several lines of evidence which contradict this theory. First, the central cornea from which the allograft button is harvested is probably devoid of Langerhans' cells³¹⁻³³ unless it is significantly perturbed. Second, although not in itself a proof, graft rejection may occur separately in any one of the corneal layers.³⁴ This suggests that local undescribed factors may play a key role in determining the final outcome of each tissue layer. Finally, we demonstrated Class II-positive cells in the epithelium of both rejecting and nonrejecting corneal allografts. It was not possible to differentiate between donor and host Langerhans' cells based on Ia staining, but the results suggest that the presence of these cells alone is not sufficient to cause endothelial rejection.

Staining for Class II antigens showed expression only when there was clinical evidence of rejection, except for occasional positive staining in the epithelium. This staining may represent a migration of recipient Langerhans' cells into the central epithelium of the graft after penetrating keratoplasty or suture placement.^{35,36} Although the magnitude of Class II antigen expression directly correlated with inflammation, all untreated grafts were more intensely stained than UV-treated grafts. However, we did not observe any correlation between Class II antigen expression and the dose of UV, but subtle differences in antigen expression cannot be excluded.

The expression of Class II antigens in the graft is probably mediated by recipient cytokines (eg, γ interferon). The apparent lowered expression of Class II

antigens observed in treated corneas suggests these cells may not respond to these cytokines as readily as untreated corneas. To hypothesize that the immunogenicity of a corneal graft is attenuated by pretreatment with UV-B assumes an alteration in the functional interface between donor antigenicity and host immune responses. There is ample evidence that UV irradiation can cause cell membrane alterations, modification of cell surface antigens, and interference with cell-cell interactions, antigen presentation, and cytokine release.³⁷ A change in the cellular nucleic acid composition can itself alter cell surface markers. Constant expression and release of "minor noncellular" antigens which are readily available to the recipient via surface lymphatics and the aqueous humor may play a significant role in allograft rejection.³⁸ The UV exposure may also modify the functional role of nonlymphoid mediators. One example of this is the inhibition of production of epidermal cell-derived T-lymphocyte-activating factor^{39,40} in the skin or epithelial cell-derived thymocyte-activating factor⁴¹ in the cornea.

Our finding that peroxidase⁺ cells are present abundantly in rejecting corneas and absent in clear grafts probably indicates the presence of reactive inflammatory cells which may precede the intrusion of specific immunologically active cells. These cells were present in lymph nodes of normal adult rabbits and are therefore part of the normal immune armamentarium; however their exact nature is not known. Macrophages, neutrophils, and mast cells contain peroxidase, but the mononuclear appearance of the cells described in our study make them unlikely candidates for neutrophils, and their endogenous peroxidase activity makes it unlikely that they are Langerhans' cells. Interestingly, other investigators have not shown peroxidase⁺ cells in either normal corneas or those with *Klebsiella*-induced keratoconjunctivitis.⁴²

Although favorable clinical data were obtained for UV-B exposures up to 90 mJ/cm², *in vitro* exposure of cultured endothelial cells to as little as one half that dose produced a significant loss in the number of viable cells. It is not possible to compare these results with other published reports on UV toxicity to corneal endothelium because the incident rays in our experiments were directed against the endothelium and were independent of UV effects in other corneal layers. Additionally, cultured cells may not have the same repair mechanisms as the whole organism.²⁵ This is particularly true in the rabbit where the endothelial monolayer can be reformed after cellular damage at the margins.⁴³ The scanning electron microscopic observation of cell-surface alterations in UV-B exposed endothelial cells *in situ* confirms earlier studies that apparently normal corneal endothelial cells

can sustain damage that is detectable only by electron microscopy.⁴⁴ The data clearly indicate, however, that the clinically useful range of UV-B energy which may favorably alter immunogenicity without causing significant cellular damage is probably narrow.

In conclusion, although many studies document the immunosuppressive activity of UV radiation, the application of these findings to transplantation has been relatively recent. If preoperative UV-B treatment is efficacious in prolonging corneal allograft survival, it may be an inexpensive and easy method for favorably altering the outcome in prognostically poor cases such as vascularized corneal beds. Additional studies, testing UV exposure over a wider frequency and dose range and comparing outcome between full-thickness and lamellar grafts, will be helpful in elucidating the potential of UV light in corneal transplantation surgery.

Key words: ultraviolet radiation, corneal transplantation, Ia antigens, Langerhans' cell, corneal endothelium

Acknowledgments

The authors thank Millie Askew for excellent surgical assistance and Susan Vitale of the Wilmer Eye Institute's Biostatistics Center for mathematical modeling and biostatistical analysis.

References

- Morison WL, Parrish JA, Bloch KJ, and Krugler JI: In vivo effect of UV-B on lymphocyte function. *Br J Dermatol* 101:513, 1979.
- Hersey P, Haran G, Hasic E, and Edwards A: Alteration of T cell subsets and induction of suppressor T cell activity in normal subjects after exposure to sunlight. *J Immunol* 131:171, 1983.
- Lindahl-Kiessling K and Safwenberg J: Inability of UV-irradiated lymphocytes to stimulate allogenic cells in mixed lymphocyte culture. *Int Arch Allergy* 41:670, 1971.
- Deeg JH: Ultraviolet irradiation in transplantation biology. *Transplantation* 48:845, 1988.
- Chabot J, Weber C, Hardy MA, Rivera S, Bailey-Braxton D, Strausberg L, Wood M, Chow J, Pi-Sunyer FX, and Reemtsma K: Synergy of ALS and UV-B in prolongation of primate-to-mouse islet xenograft survival. *Transplant Proc* 19:1160, 1987.
- Hardy MA, Lau H, and Reemtsma K: Prolongation of rat islet allografts with the use of ultraviolet irradiation, without immunosuppression. *Transplant Proc* 16:865, 1984.
- Ray-Keil L and Chandler JW: Reduction in the incidence of rejection of heterotopic murine corneal transplants by pretreatment with ultraviolet radiation. *Transplantation* 42:403, 1986.
- Ray-Keil L and Chandler JW: Rejection of murine heterotopic corneal transplants. *Transplantation* 39:473, 1985.
- Moen T, Albrechtsen D, Flutmak A, Jakobsen A, Jervell J, Halvorsen S, Solheim BG, and Thorsby E: Importance of HLA-DR matching in cadaveric renal transplantation. *N Engl J Med* 303:850, 1980.
- Stiller CR and Keown PA: Immunologic monitoring: Current perspectives and clinical implications. *Transplant Proc* 13:1699, 1981.
- Streilein JW and Bergstresser PR: Ia antigens and epidermal Langerhans' cells. *Transplantation* 30:319, 1980.
- Fujikawa LS, Calvin RB, Bhan AK, Fuller TC, and Foster CS: Expression of HLA-A/B/C and -DR locus antigens on epithelial stromal and endothelial cells of the human cornea. *Cornea* 1:213, 1982.
- Whitsett CF and Stulting RD: The distribution of HLA antigens on human corneal tissues. *Invest Ophthalmol Vis Sci* 25:519, 1984.
- Klareskog L, Forsum U, Tjertlund UM, Rask L, and Peterson PA: Expression of Ia antigen-like molecules on cells in the corneal epithelium. *Invest Ophthalmol Vis Sci* 18:310, 1979.
- Young E, Stark WJ, and Prendergast RA: Immunology of corneal allograft rejection: HLA-DR antigens on human corneal cells. *Invest Ophthalmol Vis Sci* 26:571, 1985.
- Aberer W, Stingl G, Slingl-Gazze LA, Wolff K: Langerhans' cells as stimulator cells in the murine primary epidermal cell-lymphocyte reaction: Alterations by UV-B irradiation. *J Invest Dermatol* 79:129, 1982.
- Noonan FP, Bucana C, Sauder DN, and DeFabo EC: Effect of ultraviolet radiation on epidermal Langerhans' cell morphology and function: A dichotomy. *J Invest Dermatol* 78:484, 1982.
- Noonan FP, Kripke ML, Pedersen JM, and Greene MI: Suppression of contact hypersensitivity in mice by ultraviolet radiation is associated with defective antigen presentation. *Immunology* 43:527, 1981.
- Austad J and Braather LR: Effect of UVB on alloactivating and antigen-presenting capacity of human epidermal Langerhans cells. *Scand J Immunol* 21:417, 1985.
- Streilein JW and Bergstresser PR: Ia antigens and epidermal Langerhans' cells. *Transplant Overview* 30:319, 1980.
- Kripe ML: T cell-suppressors in ultraviolet carcinogenesis. *Transplant Proc* 16:474, 1984.
- Baadsgaard O, Fox DA, and Cooper KD: Human epidermal cells from ultraviolet light-exposed skin preferentially activate autoreactive CD4⁺ 2H4⁺ suppressor-inducer lymphocytes and CD8⁺ suppressor/cytotoxic lymphocytes. *J Immunol* 140:1738, 1988.
- Pitts DG, Cullen AP, and Hacker PD: Ocular effects of ultraviolet radiation from 295 to 365 nm. *Invest Ophthalmol* 16:932, 1977.
- Zulich JA: Ultraviolet induced damage in the primate cornea and retina. *Curr Eye Res* 3:27, 1984.
- Cullen AP, Chou BR, Hall MG, and Jany SE: Ultraviolet-B damages corneal endothelium. *Am J Optometry Physiol Optics* 61:473, 1984.
- Ringvold A, Davanger M, and Olsen EG: Changes of the cornea endothelium after ultraviolet radiation. *Acta Ophthalmol (Copenh)* 60:41, 1982.
- Hsu SM, Raine L, and Fanger H: A comparative study of the PAP method and ABC method for studying polypeptide hormones with radioimmunoassay antibodies. *Am J Clin Pathol* 75:734, 1981.
- Hsu SM, Raine L, and Fanger H: The use of ABC in immunoperoxidase techniques: A comparison between ABC and unlabeled antibody (PAP) procedures. *J Histochem Cytochem* 29:577, 1981.
- Lobel SA and Knight KL: The role of rabbit Ia molecules in immune functions as determined with the use of an anti-Ia monoclonal antibody. *Immunology* 51:34, 1984.
- Young E and McMillan BA: "Lymphocyte-defined" antigens on corneal fibroblasts. *Curr Eye Res* 4:273, 1986.
- Lang RM, Friedlaender MH, and Schoerock BJ: A new mor-

- phologic manifestation of Langerhans' cells in the guinea pig corneal transplants. *Curr Eye Res* 1:161, 1981.
32. Tagawa Y, Takeuchi T, Saga T, Matsuda H, and Silverstein AM: Langerhans' cells: Role in ocular surface immunopathology. *In Advances in Immunology and Immunopathology of the Eye*. O'Connor GR and Chandler JW, editors. Chicago, Yearbook Medical Publishers, 1985, p. 205.
 33. Rubsamens PE, McCulley J, Bergstresser PR, and Streilein JW: A murine model for heterotopic transplantation of corneas: Proof that Langerhans' cells are essential Ia-antigen-presenting cells. *In Advances in Immunology and Immunopathology of the Eye*. O'Connor GR and Chandler JW, editors. Chicago, Yearbook Medical Publishers, 1985, p. 301.
 34. Khodadoust AA and Silverstein AM: Transplantation and rejection of individual cell layers of the cornea. *Invest Ophthalmol* 8:180, 1969.
 35. Kelley JG, Ohashi Y, and Friedlaender MH: Langerhans' cell alterations in the guinea pig cornea. *Invest Ophthalmol Vis Sci* 26:1293, 1985.
 36. Roussel TJ, Osato MS, and Wilhelmus KR: Corneal Langerhans' cell migration following ocular contact hypersensitivity. *Cornea* 2:27, 1983.
 37. Kripke MI: Immunological unresponsiveness induced by ultraviolet radiation. *Immunol Rev* 80:87, 1984.
 38. Polack FM: *Corneal Transplantation*. New York, Academic Press, 1977, pp. 71-85.
 39. Sauder DN, Noonan FP, DeFabo EC, and Katz SI: Ultraviolet radiation inhibits alloantigen presentation by epidermal cells: Partial reversal by the soluble epidermal cell product, epidermal cell-derived thymocyte-activating factor (ETAf). *J Invest Dermatol* 80:485, 1983.
 40. Gahring L, Baltz M, Pepys MB, and Daynes R: Effect of ultraviolet radiation on production of epidermal cell thymocyte-activating factor/interleukin 1 in vivo and in vitro. *Proc Natl Acad Sci USA* 81:1198, 1984.
 41. Grabner G, Lugar TA, Smolin G, and Oh JO: Biological and biochemical properties of a corneal epithelial cell-derived thymocyte-activating factor (CETAf). *In Advances in Immunology and Immunopathology of the Eye*. O'Connor GR and Chandler JW, editors. Chicago, Yearbook Medical Publishers, 1985, pp. 167-169.
 42. Gracia-Olivares E, Buenaventura C, and Gallardo JM: Presence of Langerhans' cells in the cornea of *Klebsiella* keratoconjunctivitis mice. *Invest Ophthalmol Vis Sci* 29:108, 1988.
 43. Van Horn DL, Sendele DD, Seidman S, and Bucu PJ: Regenerative capacity of the corneal endothelium in rabbit and cat. *Invest Ophthalmol* 16:597, 1977.
 44. Riley MV, Susan S, Peters MI, and Schwartz CA: The effects of UV-B corneal endothelium. *Curr Eye Res* 6:1021, 1987.