



Penetrating Blast Injury to the Knee of a United States Soldier Treated with Allograft Mosaicplasty

Citation

Eichinger, Maj. Josef K., Eric M. Bluman, and Col. Edward D. Arrington. 2011. "Penetrating Blast Injury to the Knee of a United States Soldier Treated with Allograft Mosaicplasty." *Cartilage* 2 (3): 307-311. doi:10.1177/1947603510392024. <http://dx.doi.org/10.1177/1947603510392024>.

Published Version

doi:10.1177/1947603510392024

Permanent link

<http://nrs.harvard.edu/urn-3:HUL.InstRepos:17295721>

Terms of Use

This article was downloaded from Harvard University's DASH repository, and is made available under the terms and conditions applicable to Other Posted Material, as set forth at <http://nrs.harvard.edu/urn-3:HUL.InstRepos:dash.current.terms-of-use#LAA>

Share Your Story

The Harvard community has made this article openly available.
Please share how this access benefits you. [Submit a story](#).

[Accessibility](#)

Penetrating Blast Injury to the Knee of a United States Soldier Treated with Allograft Mosaicplasty

Cartilage
2(3) 307–311
© The Author(s) 2011
Reprints and permission:
sagepub.com/journalsPermissions.nav
DOI: 10.1177/1947603510392024
http://cart.sagepub.com


Maj. Josef K. Eichinger¹, Eric M. Bluman²,
and Col. Edward D. Arrington³

Abstract

Objective: This is the first report of successful allograft mosaicplasty treatment of a large osteochondral lesion of the knee caused by a blast fragment sustained during combat operations. The patient was able to return to active duty following rehabilitation. **Methods:** An active-duty infantryman sustained an osteochondral lesion of the medial femoral condyle caused by a metallic fragment of an explosively formed projectile. Initial treatment consisted of removal of the foreign body and primary closure. The patient continued to experience pain, mechanical symptoms, and repeated effusions after initial nonoperative treatment. Allograft mosaicplasty of the lesion utilizing two 18-mm-diameter fresh allograft osteochondral plugs was performed at 6 months post-injury. **Results:** At 2-year follow-up, the patient remains on active duty with marked improvement in symptoms. Two years postoperatively, his outcome scores are 72 of 100 on the Western Ontario and McMaster University osteoarthritis scoring index (WOMAC) and 60 of 100 on the Knee Injury and Osteoarthritis Outcome Score (KOOS). His follow-up x-rays and MRI demonstrate intact articular cartilage and subchondral bone incorporation. **Conclusion:** Penetrating injuries to joints are commonplace in the battlefield environment. Combat injuries to the knee are frequently associated with articular cartilage injury. While numerous cartilage restoration techniques have been used with success for the treatment of osteochondral injuries to the femoral condyles, no published reports describe the use of allograft mosaicplasty in this location for open, penetrating injuries with focal cartilage loss. This is the first documented use of allograft mosaicplasty for a traumatic osteochondral defect of the medial femoral condyle caused by a metallic projectile. The patient was able to return to active duty following rehabilitation. We demonstrate a high level of functioning is possible following allograft mosaicplasty of a large osteochondral lesion caused by penetrating ballistic trauma.

Keywords

mosaicplasty, blast injury, IED, EFP, explosive, open injury

Introduction

Penetrating injuries to the knee are encountered both in civilian trauma and during military combat operations.^{1–9} In the military, these injuries most frequently result from explosive blasts or bullets.¹⁰ Aside from the soft tissue involvement, these open wounds may involve varying degrees of bone and cartilage destruction.⁵ In addition to irrigation, debridement, and soft tissue repair, multiple other modalities may be required for successful treatment of these injuries.

Mosaicplasty procedures have been employed to treat large, full-thickness loss of cartilage in multiple joints of the extremities.¹¹ Both autograft and allograft procedures have been described. While the majority of reports on

osteochondral lesions of the knee describe trauma as the pathoetiology, none specifically describe the use of mosaicplasty for injuries caused by projectiles.^{11–15}

¹Department of Orthopaedics, Womack Army Medical Center, Fort Bragg, NC, USA

²Department of Orthopaedics, Brigham and Women's Hospital, and Harvard Medical School, Boston, MA, USA

³Orthopaedic Service, Madigan Army Medical Center, Fort Lewis, WA, USA

Corresponding Author:

Maj. Josef K. Eichinger, MD, Department of Orthopaedics, Womack Army Medical Center, Fort Bragg, NC 28310
Email: joe.eichinger@gmail.com

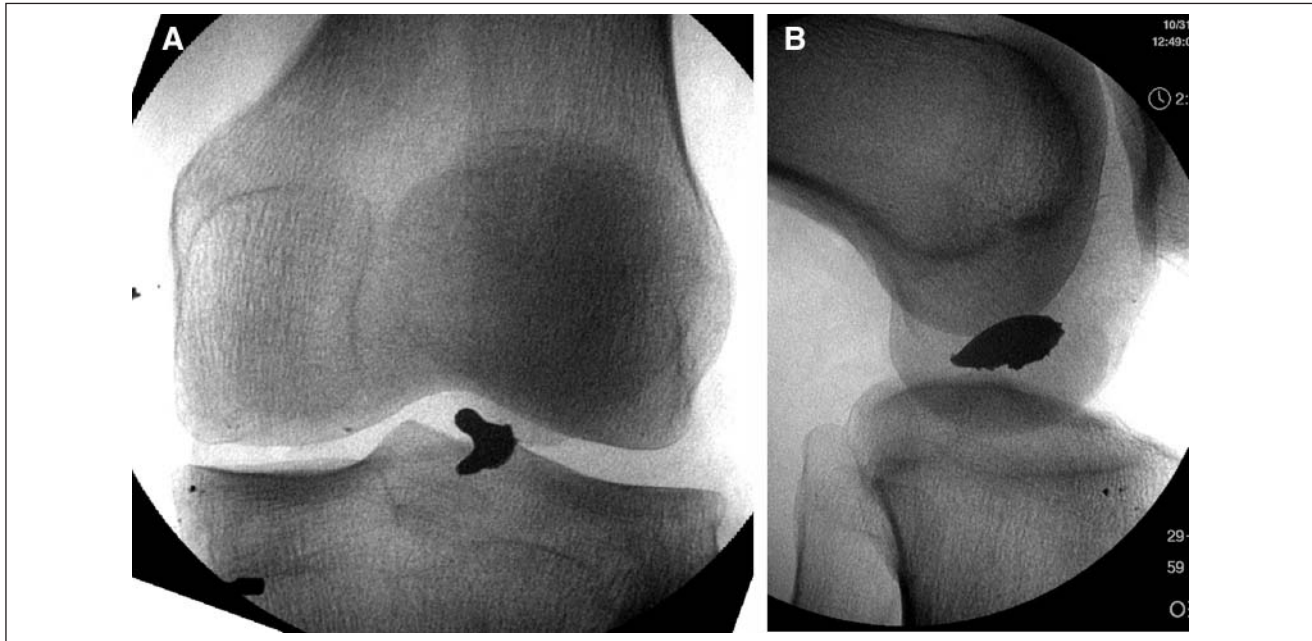


Figure 1. Initial anteroposterior (A) and lateral (B) fluoroscopic images of the knee with retained metallic fragment.

Case Report

Permission was obtained from the patient to allow publication of his treatment history and radiological images. On the evening of 30 October 2006, a 34-year-old male U.S. Army infantry officer sustained multiple injuries after his armored troop transporter was struck by an explosively formed projectile (EFP) while on patrol with his unit just outside of Baghdad, Iraq. EFPs are a particularly lethal form of armor-penetrating improvised explosive device (IED) that have been employed by insurgent forces in Iraq.¹⁶ Following the attack, the patient was unable to ambulate because of pain in his right leg and knee.

The patient was evacuated to the 28th Combat Support Hospital in Baghdad, where a full trauma work-up was performed. The ATLS survey finding was negative. During the secondary survey, his injuries were noted to include penetrating wounds to his lower extremities, scrotum, and perineum. The largest of the penetrating wounds was a 2-cm laceration just medial to the inferior pole of his left patella. The patient had a normal neurovascular and ligamentous examinations result in the affected extremity. Range of motion measurements of the knee were substantially limited by pain. Radiographs revealed an irregular radiodense piece of fragmentation in the anterior soft tissues of the knee (**Fig. 1**). Because it was unclear from the imaging whether the fragment had breached the joint capsule, a 50-mL sterile saline challenge to the knee joint was performed.^{17,18} An open knee injury was diagnosed after

injected saline was noted to be draining through the inferomedial knee wound. The patient consented for irrigation and debridement of the left knee as well as surgical treatment of his genital injuries.

In the operating room, a limited medial parapatellar arthrotomy was performed by extending the traumatic wound. Upon exploring the wound, a large metallic fragment was found within the anterior fat pad (**Fig. 2**). It measured $2.5 \times 1.0 \times 0.4$ cm. The adjacent joint capsule was noted to be lacerated. This defect was extended to reveal a 3×2 -cm area of full-thickness cartilage loss from the lateral portion of the medial condyle. In addition to the cartilage loss, a portion of the corresponding subchondral bone was noted to be denuded. The joint was further explored through the wound and irrigated with 9 L of sterile saline. No loose bone, cartilage, or additional foreign material resembling the area of osteochondral loss was found in the joint or soft tissues. A layered closure of the joint was performed after all devitalized tissue was debrided. There was no loss of integument associated with the injury. The remainder of his lower extremity wounds were irrigated and debrided followed by open management. He underwent left orchiectomy for irreparable testicular damage, and his remaining perineal wounds were debrided and treated with open management. The patient was subsequently evacuated back to the authors' medical facility within 10 days.

Initially, following healing of the soft tissues, the patient was treated with active range of motion of his injured knee

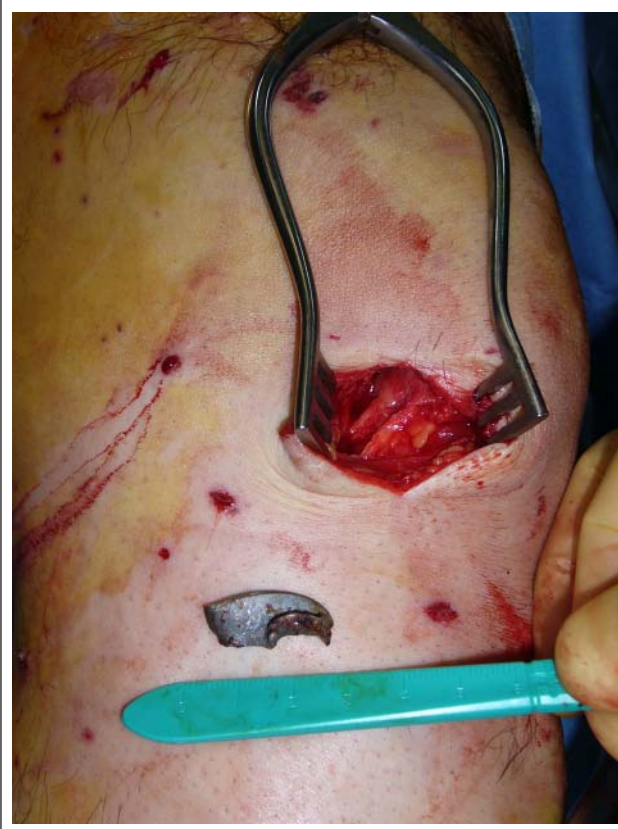

Figure 2. Knee at time of debridement with extracted metallic fragment.

and protected, partial weightbearing for 8 weeks. During this initial rehabilitation period, the patient complained of significant pain, repeated effusions, and mechanical symptoms, making weightbearing very difficult without the aid of crutches. He received additional imaging, including a computed tomography (CT) scan (**Fig. 3**), which revealed a 3.2×1.9 -cm lesion on the medial condyle. A discussion of possible treatment options was undertaken, and the patient opted to undergo allograft mosaicplasty of the lesion. Once an allograft condyle became available, the patient was taken to the operating room for arthroscopy followed by allograft mosaicplasty of the lesion at 6 months postinjury.

Intraoperatively, the patient's knee was ligamentously stable, and arthroscopic evaluation confirmed the dimensions of the lesion. A small horizontal cleavage tear of the medial meniscus was discovered and debrided. Following arthroscopy, a 10-cm medial parapatellar arthrotomy was performed, allowing access to the condylar lesion (**Fig. 4**). A decision to utilize two 18-mm-diameter allograft osteochondral plugs was made. The donor plugs were obtained from a size-matched, fresh allograft femoral condyle (Allosource, Centennial, CO) using a commercially available harvesting system. These plugs were implanted into

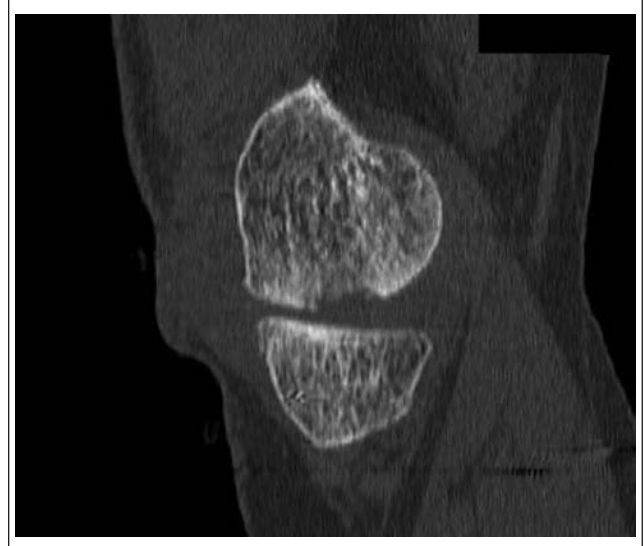

Figure 3. Sagittal computed tomography (CT) image showing the medial femoral condylar traumatic defect 4 months after injury.

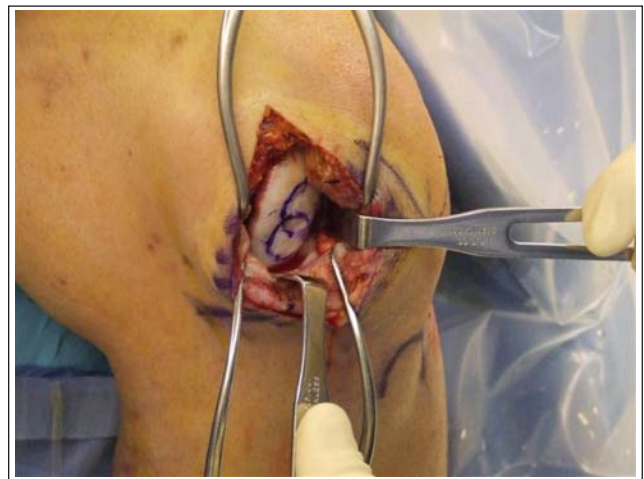


Figure 4. Intraoperative image of the right knee medial femoral condylar lesion prior to mosaicplasty.

the area of the lesion after the diseased tissue had been removed using complementary sized drill bits (**Fig. 5**).

After surgery, the patient remained nonweightbearing on the operative leg for 3 months but was allowed unrestricted range of motion. Transition to weightbearing activities and resistance training ensued. The patient was able to return to weightbearing activities with minimal discomfort. Although released to full activity, he remains limited in running and marching with full combat gear (approximately 80 lb of protective gear and equipment). Two years postoperatively, his outcome scores are the following: Western Ontario and McMaster University osteoarthritis scoring index (WOMAC), 72 of 100; and Knee Injury and Osteoarthritis Outcome

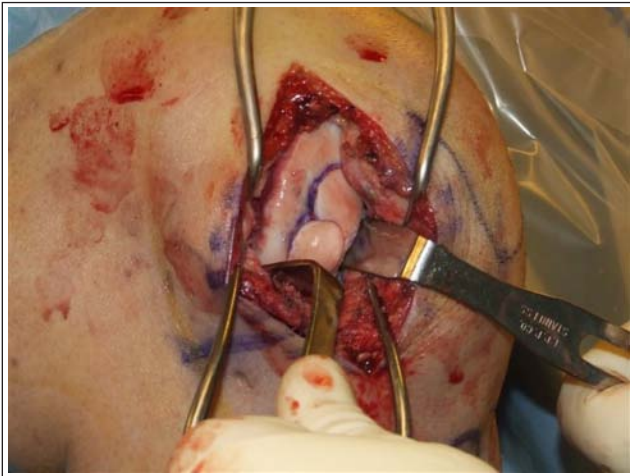


Figure 5. Intraoperative image of the right knee after inserting allograft plugs.

Score (KOOS), 60 of 100. His follow-up x-rays and MRI demonstrate intact articular cartilage and subchondral bone incorporation (**Fig. 6**). He remains on active duty at 2-year follow-up.

Discussion

Penetrating injuries to joints, particularly knees, are commonplace in the battlefield environment.^{1,5,19,20} In one series, knee trauma accounted for 50% of joint injuries.⁵ Combat injuries to the knee are frequently associated with articular cartilage injury.²⁰ Although less common than those caused by blunt trauma, penetrating articular injuries occur in non-combat-related incidents. In the noncombat environment, these frequently arise from gunshot wounds.^{16,21,22} The current conflicts have produced large numbers of knee injuries from blast mechanisms. Unfortunately, many of these injuries have large amounts of comminution, affecting limb stability and greatly complicating reconstructive efforts. Although substantially less common, we do not know the incidence of focal, nondestabilizing osteochondral lesions resulting from blast injury in the Global War on Terror.

Several case series report generally “good” outcomes in patients treated for penetrating ballistic injuries without defined follow-up periods or objective outcome measurements.^{5,8,20,23} These patients were treated with arthroscopic debridement of foreign and loose bodies without further procedures. Regarding focal cartilage lesions, only “drilling” of these defects has been described outside of a single report of allograft reconstruction for extensive bone loss of the medial femoral condyle following a gunshot wound to the knee.⁶ No objective analysis of outcome was provided in this report.

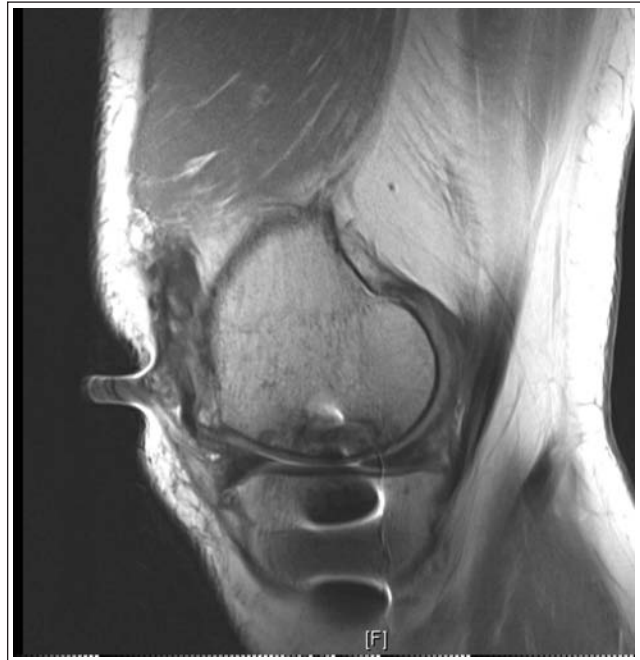

Figure 6. Sagittal fat-suppressed magnetic resonance image of the knee 2 years following allograft mosaicplasty.

While numerous cartilage restoration techniques have been used with success for the treatment of osteochondral injuries to the femoral condyles, no published reports describe the use of allograft mosaicplasty in this location for open, penetrating injuries with focal cartilage loss. To the best of our knowledge, this is the first documentation of allograft mosaicplasty used for reconstruction of a traumatic osteochondral defect of the medial femoral condyle caused by a metallic projectile.

Although the use of allograft mosaicplasty was successful in our patient, it is not appropriate for all patients with focal osteochondral lesions of the femoral condyles caused by penetrating trauma. Some patients may sustain osteochondral injuries that are large and amenable to reduction and fixation, while small articular lesions (less than 0.5-1.0 cm, depending on location) may be treated with debridement, microfracture, or abrasion chondroplasty.²⁴ For small articular cartilage lesions, it is prudent to first attempt less invasive methods such as arthroscopically assisted marrow stimulation techniques.²⁵ Larger lesions (measuring greater than 2.0-3.0 cm² in area), such as the one encountered in our patient, have been treated successfully with a variety of methods including autologous chondrocyte implantation (ACI) as well as both autograft and allograft mosaicplasty.^{11,25,26} Given the size of this patient’s lesion and the involvement of the subchondral bone, we felt the best treatment was allograft mosaicplasty. Treatment of articular

cartilage lesions is clearly dependent on several variables including patient factors, available resources, and surgeon capabilities. All factors must be taken into consideration when planning treatment. With the high percentage of penetrating knee injuries resulting in articular cartilage injury, it is important to both accurately diagnose the lesions and choose a proper method of articular resurfacing.

This case report describes successful management of a large osteochondral injury to the medial femoral condyle using allograft mosaicplasty in an active-duty serviceman. We demonstrate the utility of this technique for military as well as civilian orthopedic surgeons faced with similar scenarios.

Acknowledgments and Funding

The opinions or assertions contained herein are the private views of the authors and are not to be construed as official or reflecting the views of the Department of the Army or the Department of Defense. The authors thank Allosource for their continuing support of the United States Military and its service members. The authors received no financial support for the research and/or authorship of this article.

Declaration of Conflicting Interests

The authors declared no potential conflicts of interest with respect to the authorship and/or publication of this article.

References

1. Carney P, Fitts W, Kirby C. Gunshot wounds of the major joints. *J Bone Joint Surg Am.* 1946;28:607-15.
2. Covey DC. Blast and fragment injuries of the musculoskeletal system. *J Bone Joint Surg Am.* 2002;84-A(7):1221-34.
3. David VC. Gunshot injuries of the knee joint in a base hospital. *Ann Surg.* 1919;70(3):290-5.
4. Dougherty PJ, Najibi S, Silverton C, Vaidya R. Gunshot wounds: epidemiology, wound ballistics, and soft-tissue treatment. *Instr Course Lect.* 2009;58:131-9.
5. Nikolic D, Jovanovic Z, Popovic Z, Vulovic R, Mladenovic M. Primary surgical treatment of war injuries of major joints of the limbs. *Injury.* 1999;30(2):129-34.
6. Oladipo JO, Creevy W, Remis R. Arthroscopic management of intra-articular low-velocity gunshot wounds of the knee. *Am J Knee Surg.* 1999;12(4):229-32.
7. Perry DJ, Sanders DP, Nyirenda CD, Lezine-Hanna JT. Gunshot wounds to the knee. *Orthop Clin North Am.* 1995;26(1):155-63.
8. Raskind JR, Marder RA. Arthroscopic versus open debridement of penetrating knee joint injuries. *Iowa Orthop J.* 1993;13:121-3.
9. Tornetta P 3rd, Hui RC. Intraarticular findings after gunshot wounds through the knee. *J Orthop Trauma.* 1997;11(6):422-4.
10. Owens BD, Kragh JF Jr, Macaitis J, Svoboda SJ, Wenke JC. Characterization of extremity wounds in Operation Iraqi Freedom and Operation Enduring Freedom. *J Orthop Trauma.* 2007;21(4):254-7.
11. Gortz S, Bugbee WD. Allografts in articular cartilage repair. *J Bone Joint Surg Am.* 2006;88(6):1374-84.
12. Gross AE, Kim W, Las Heras F, Backstein D, Safir O, Pritzker KP. Fresh osteochondral allografts for posttraumatic knee defects: long-term followup. *Clin Orthop Relat Res.* 2008;466(8):1863-70.
13. Hangody L, Fules P. Autologous osteochondral mosaicplasty for the treatment of full-thickness defects of weight-bearing joints: ten years of experimental and clinical experience. *J Bone Joint Surg Am.* 2003;85-A(Suppl 2):25-32.
14. LaPrade RF, Botker J, Herzog M, Agel J. Refrigerated osteoarticular allografts to treat articular cartilage defects of the femoral condyles: a prospective outcomes study. *J Bone Joint Surg Am.* 2009;91(4):805-11.
15. McCulloch PC, Kang RW, Sobhy MH, Hayden JK, Cole BJ. Prospective evaluation of prolonged fresh osteochondral allograft transplantation of the femoral condyle: minimum 2-year follow-up. *Am J Sports Med.* 2007;35(3):411-20.
16. Morrison JJ, Mahoney PF, Hodgetts T. Shaped charges and explosively formed penetrators: background for clinicians. *J R Army Med Corps.* 2007;153(3):184-7.
17. Keese GR, Boody AR, Wongworawat MD, Jobe CM. The accuracy of the saline load test in the diagnosis of traumatic knee arthrotomies. *J Orthop Trauma.* 2007;21(7):442-3.
18. Nord RM, Quach T, Walsh M, Pereira D, Tejwani NC. Detection of traumatic arthrotomy of the knee using the saline solution load test. *J Bone Joint Surg Am.* 2009;91(1):66-70.
19. Hampton O. The management of penetrating wounds and suppurative arthritis of the knee joint in the Mediterranean theater of operations. *J Bone Joint Surg Am.* 1946;28:659-80.
20. Haspl M, Bojanic I, Pecina M. Arthroscopic retrieval of metal foreign bodies from the knee joint after war wounds. *Injury.* 1996;27(3):177-9.
21. Dicipinigaitis PA, Fay R, Egol KA, Wolinsky P, Tejwani N, Koval KJ. Gunshot wounds to the lower extremities. *Am J Orthop.* 2002;31(5):282-93.
22. Ganocy K 2nd, Lindsey RW. The management of civilian intra-articular gunshot wounds: treatment considerations and proposal of a classification system. *Injury.* 1998;29 Suppl 1:SA1-6.
23. Ashby ME. Low-velocity gunshot wounds involving the knee joint: surgical management. *J Bone Joint Surg Am.* 1974;56(5):1047-53.
24. Parisien JS, Esformes I. The role of arthroscopy in the management of low-velocity gunshot wounds of the knee joint. *Clin Orthop Relat Res.* 1984;185:207-13.
25. Alford JW, Cole BJ. Cartilage restoration, part 2: techniques, outcomes, and future directions. *Am J Sports Med.* 2005;33(3):443-60.
26. Bentley G, Biant LC, Carrington RW, Akmal M, Goldberg A, Williams AM, et al. A prospective, randomised comparison of autologous chondrocyte implantation versus mosaicplasty for osteochondral defects in the knee. *J Bone Joint Surg Br.* 2003;85(2):223-30.