



Case 8-2010 — A 22-Year-Old Woman with Hypercalcemia and a Pelvic Mass

Citation

Young, Robert, Annekathryn Goodman, Richard Penson, Anthony Russell, Raul Uppot, and Rosemary Tambouret. 2010. "Case 8-2010: A 22-Year-Old Woman with Hypercalcemia and a Pelvic Mass." *The New England Journal of Medicine* 362, no. 11 (March 2010): 1031-1040.

Published Version

DOI: 10.1056/NEJMcpc1000272

Permanent link

<http://nrs.harvard.edu/urn-3:HUL.InstRepos:40838995>

Terms of Use

This article was downloaded from Harvard University's DASH repository, and is made available under the terms and conditions applicable to Other Posted Material, as set forth at <http://nrs.harvard.edu/urn-3:HUL.InstRepos:dash.current.terms-of-use#LAA>

Share Your Story

The Harvard community has made this article openly available.
Please share how this access benefits you. [Submit a story](#).

[Accessibility](#)

CASE RECORDS of the MASSACHUSETTS GENERAL HOSPITAL

Founded by Richard C. Cabot

Nancy Lee Harris, M.D., *Editor*
Jo-Anne O. Shepard, M.D., *Associate Editor*
Sally H. Ebeling, *Assistant Editor*

Eric S. Rosenberg, M.D., *Associate Editor*
Alice M. Cort, M.D., *Associate Editor*
Christine C. Peters, *Assistant Editor*



Case 8-2010: A 22-Year-Old Woman with Hypercalcemia and a Pelvic Mass

Robert H. Young, M.D., Annekathryn Goodman, M.D.,
Richard T. Penson, M.D., M.R.C.P., Anthony H. Russell, M.D.,
Raul N. Uppot, M.D., and Rosemary H. Tambouret, M.D.

PRESENTATION OF CASE

A 22-year-old woman was admitted to this hospital because of hypercalcemia and a pelvic mass.

The patient had been well until 1 month before admission, when abdominal pain developed, initially in the right lower quadrant; during the following 3 weeks, the pain increased in severity, involved the entire abdomen, and radiated to the back. Two weeks before admission, she noted abdominal fullness. A home pregnancy test was negative. During the same interval, increased thirst, fatigue, and anorexia developed, and she had a weight loss of 2.3 kg. Two days before admission, nausea and vomiting developed. The night before admission, multiple episodes of nocturia occurred. On the day of admission, she went to the emergency department of another hospital.

The patient reported increasing abdominal fullness without increasing girth. She had chronic constipation (bowel movements once per week), which was unchanged. She did not have fevers, chills, chest pain, shortness of breath, palpitations, dizziness, vaginal bleeding or discharge, or pain with intercourse. The physical examination was normal. Levels of serum protein, albumin, total bilirubin, and lipase and tests of renal and liver function were normal; urinalysis was consistent with contamination, and a screening pregnancy test was negative. Other test results are shown in Table 1.

An electrocardiogram showed sinus rhythm at a rate of 70 beats per minute and a shortened QT interval and was otherwise normal. A computed tomographic (CT) scan of the chest, abdomen, and pelvis showed a complex cystic mass in the right adnexa, 16.7 cm by 13.4 cm by 13 cm, which displaced the uterus posteriorly and to the left. The mass contained peripheral solid components along the left lateral and inferior wall, which showed slight progressive enhancement on delayed-phase images, and central fluid density representing either cyst fluid or necrotic tissue. There was no calcification or tissue with the density of fat within the mass. The left ovary measured 3.2 cm by 1.8 cm. The right ureter passed posteriorly to the mass, and no ureteral obstruction was seen; the urinary bladder was normal. Zoledronic

From the Departments of Pathology (R.H.Y., R.H.T.), Obstetrics, Gynecology, and Reproductive Biology (A.G.), Medicine (R.T.P.), Radiation Oncology (A.H.R.), and Radiology (R.N.U.), Massachusetts General Hospital; and the Departments of Pathology (R.H.Y., R.H.T.), Obstetrics, Gynecology, and Reproductive Biology (A.G.), Medicine (R.T.P.), Radiation Oncology (A.H.R.), and Radiology (R.N.U.), Harvard Medical School.

N Engl J Med 2010;362:1031-40.

Copyright © 2010 Massachusetts Medical Society.

Table 1. Laboratory Data.*					
Variable	Reference Range, Adults†	Day of Admission, Other Hospital	Other Hospital, after Intravenous Fluids	On Admission	15 Hr after Admission
Hematocrit (%)	36.0–46.0 (women)	37.2		29.5	
Hemoglobin (g/dl)	12.0–16.0 (women)	12.8		10.5	
White-cell count (per mm ³)	4500–11,000	9600		6900	
Differential count (%)					
Neutrophils	40–70			75	
Lymphocytes	22–44			18	
Monocytes	4–11			5	
Eosinophils	0–8			2	
Platelet count (per mm ³)	150,000–400,000	433,000		382,000	
Erythrocyte sedimentation rate (mm/hr)		60 (ref 0–20)			
Calcium (mg/dl)	8.5–10.5	17.2 (repeated, 16.6)	14	12.7	11.6
Ionized calcium (mmol/liter)	1.14–1.30			1.67	
Phosphorus (mg/dl)	2.6–4.5	3.4		1.2	1.2
Magnesium (mmol/liter)	0.7–1.0			0.6	
Human chorionic gonadotropin, quantitative (IU/liter)	<6 (not pregnant)			<6	
Alpha-fetoprotein, nonmaternal (ng/ml)	<6.1	1.1 (ref <7.5)		1.6	
Calcitonin (pg/ml)		<2.0 (ref 0–5.0)			
Parathyroid hormone (pg/ml)	10–60	<3 (ref 12–65)		8	
Parathyroid hormone–related protein (pmol/liter)	≤4.7	4.2 (ref 0.0–1.5)		<2.5	
Thyroxine (μg/dl)		8.9 (ref 5.5–11.0)			
Thyrotropin (μU/ml)	0.40–5.00			3.82	
1,25-Dihydroxyvitamin D (pg/ml)		28.3 (ref 15.9–55.6)			
25-Hydroxyvitamin D (ng/ml)	>32 (desired)			34	
Inhibin (pg/ml)	1.8–17.3 (early follicular)			5.9	
	3.5–31.7 (midfollicular)				
	9.8–90.3 (late follicular)				
	16.9–91.8 (midcycle)				
	16.1–97.5 (early luteal)				
	3.9–87.7 (midluteal)				
	2.7–47.1 (late luteal)				
CA-125 (U/ml)	0.0–35.0			55.4	
Lactate dehydrogenase (U/liter)	110–210			255	

* Ref denotes the reference range at the other hospital. To convert the values for calcium to millimoles per liter, multiply by 0.250. To convert the values for phosphorus to millimoles per liter, multiply by 0.3229. To convert the values for magnesium to milligrams per deciliter, divide by 0.4114. To convert the values for thyroxine to nanomoles per liter, multiply by 12.87.

† Reference values are affected by many variables, including the patient population and the laboratory methods used. The ranges used at Massachusetts General Hospital are for adults who are not pregnant and do not have medical conditions that could affect the results. They may therefore not be appropriate for all patients.

acid, ondansetron, and fluids were administered intravenously; results of repeat laboratory tests are in Table 1. The patient was transferred to this hospital.

Menarche had occurred at the age of 13 years; the patient's menstrual cycles were regular and of 4 days' duration. Her most recent menses had begun 23 days earlier, and flow was slightly lighter than normal. She had had an abnormal Papanicolaou smear 3 years earlier; colposcopy and cryosurgery were performed, and subsequent studies had reportedly been normal. She was sexually active with one male partner and had not used contraception for 8 months. She took no medications and was allergic to amoxicillin and penicillin. She lived with her partner, worked in an office, was a vegetarian, and did not smoke, drink, or use illicit drugs. Her parents and siblings were healthy. There was no family history of cancer.

On examination, the temperature was 36.6°C, the blood pressure 117/63 mm Hg, the pulse 78 beats per minute, the respiratory rate 16 breaths per minute, and the oxygen saturation 97% while the patient was breathing ambient air. The abdomen was soft, with no tenderness, rebound, or guarding; a mass (13 cm in diameter) was palpated in the midline. The remainder of the examination was normal. Levels of protein, albumin, globulin, total and direct bilirubin, and alkaline phosphatase and tests of renal and liver function were normal. Other results of laboratory tests are shown in Table 1. Furosemide, magnesium sulfate, potassium phosphate, and potassium chloride were administered intravenously, and magnesium hydroxide was given orally. Laboratory-test results are given in Table 1.

A diagnostic procedure was performed.

DIFFERENTIAL DIAGNOSIS

Dr. Robert H. Young: May we see the imaging studies?

Dr. Raul N. Uppot: Axial CT scans from the other hospital, with selected images of the pelvis (Fig. 1A), showed a large, complex cystic lesion in the right pelvis, extending upward into the midabdomen and displacing the uterus to the left. The lesion had a low-density component, representing fluid or necrotic tissue, and a thick rind of soft tissue along the left posterior edges. No

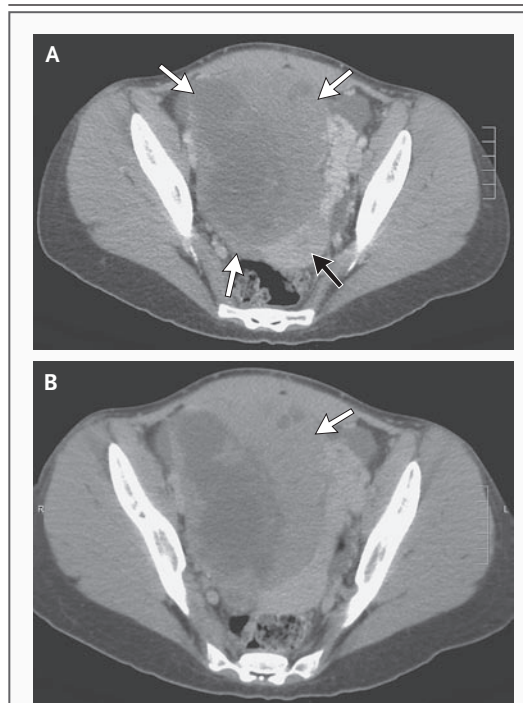


Figure 1. CT of the Pelvis with Intravenous and Oral Contrast.

A large, complex solid and cystic lesion in the right pelvis (Panel A, white arrows) displaces the uterus posteriorly and to the left (black arrow). Axial delayed-phase CT of the pelvis (Panel B) at the same level shows progressive enhancement of the solid components of the lesion and along its peripheral left lateral wall (arrow).

calcifications or areas of fat density were visualized within the lesion to suggest a benign teratoma. Delayed-phase images through the pelvis (Fig. 1B) showed progressive enhancement of the soft-tissue component of the lesion. These findings were suspicious for a complex, malignant ovarian tumor.

Dr. Young: I am aware of the diagnosis in this case, but it provides an opportunity to discuss an important topic — ovarian tumors in the young. The essence of this case is a uterine adnexal mass, almost certainly cancer, in a 22-year-old woman with symptoms (nausea, anorexia, polydipsia, polyuria, and nocturia) and laboratory evidence of hypercalcemia. The imaging and overall clinical findings are more consistent with a tumor arising in the ovary than in the other sites of adnexal neoplasia: the fallopian tube or paraovarian or paratubal tissues. The normal level of parathyroid hormone and the elevated

level of parathyroid hormone–related protein indicate that the hypercalcemia is most likely related to the ovarian neoplasm. Thus, the differential diagnosis requires a focus first on ovarian tumors in the young — broadly defined as women under 30 years of age — and then on ovarian tumors that are known to be associated with hypercalcemia.

OVARIAN TUMORS THAT OCCUR BEFORE 30 YEARS OF AGE

I have used the age of 30 years as a benchmark because there is an accelerated occurrence of benign, borderline, and malignant neoplasms of the ovarian surface epithelium starting when women are approximately 30 years of age. These neoplasms account for the majority of ovarian tumors in the middle-to-late years of life.¹ Germ-cell tumors account for about 75% of ovarian tumors in the first three decades; neoplasms of the surface epithelium and sex cord–stromal tumors each account for about 10%, and the final 5% are a heterogeneous group, including ovarian involvement by lymphoma or leukemia.

The differential diagnosis of ovarian tumors varies among the first three decades of life (Table 2). This patient is in her third decade. Primitive germ-cell tumors, which are uncommon in the first decade and peak in the second, remain common in the third decade. Sex cord–stromal tumors are common in all of the first three decades but are more common in the second and third than in the first. Occurrence of the Sertoli–Leydig cell tumor peaks at 25 years of age; oc-

currence of the retiform variant of the Sertoli–Leydig cell tumor peaks at 15 years of age.² Dermoid cysts, which are rare in the early years of the first decade, are an important consideration in the second and third decades. In this patient, the ovarian tumor appeared to be partially cystic, but definitive features of a dermoid cyst (e.g., fat or bone) were not seen. Tumors of the surface epithelium are seen with increased frequency in the latter years of the second decade, but the only one seen with appreciable frequency is the mucinous neoplasm; in this 22-year-old woman, a tumor of the surface epithelium is possible, especially in view of the large, complex mass seen on imaging. The occurrence of small-cell carcinoma of the hypercalcemic type³ begins in the second decade but peaks in the third decade at an average of approximately 24 years of age; the large mass seen in this patient would be consistent with this diagnosis.

Follicular cysts are frequent in the second decade of life, but may also occur in the third decade; a follicular cyst would not produce the large, complex mass seen in this patient. Follicular cysts, which have peak occurrences around the times of the menarche and menopause, have a third, minor peak in the neonatal era due to stimulation of the infant ovary by maternal hormones in utero. This can result in dramatic manifestations if the cyst twists or is large enough to be symptomatic in the first weeks of life.

Tumors that metastasize to the ovary from another site, which account for an important subgroup of ovarian tumors overall, are rare in pa-

Table 2. Selected Ovarian Masses and Their Approximate Relative Frequencies in the First Three Decades of Life.

Ovarian Tumor	First Decade	Second Decade	Third Decade
Primitive germ-cell tumors (dysgerminoma, immature teratoma, endodermal sinus tumor)	Uncommon	Most common at age of 18–20 yr	Decreasingly common
Mature cystic teratoma (dermoid cyst)	Occasional	More common	More common
Sex cord–stromal tumors (Sertoli–Leydig cell tumor, juvenile granulosa-cell tumor, thecoma, fibroma)	Occasional	More common: retiform variant of Sertoli–Leydig cell tumor peaks at age of 15 yr	Most common: Sertoli–Leydig cell tumor peaks at age of 25 yr
Surface epithelial tumors	Rare	Occasional (most commonly mucinous)	More common
Small-cell carcinoma with hypercalcemia	Rare	Occasional: likelihood increases with age	Most common: peaks at a mean age of 24 yr
Others (including metastases, lymphomas, and leukemias)	Rare	Occasional	More common
Follicular cysts (may be associated with torsion and acute symptoms)	Occasional in neonates	Common at menarche and after	Common

tients under 30 years of age but are seen more frequently in the second decade than in the first. Nevertheless, there are documented cases of Krukenberg tumors in teenagers,⁴ and some neoplasms that are relatively common in children, such as neuroblastoma, may spread to the ovaries in the first or second decade.⁵ A metastatic tumor, particularly carcinoma of the breast, would be more likely in this 22-year-old patient than in a patient in her first or second decade, although it would still be less likely than a primary ovarian tumor and less likely than in an older woman.

OVARIAN MASSES IN PREGNANCY

Another aspect to consider in a patient in the third decade (and occasionally in a patient in the second decade) is an ovarian mass during pregnancy. There are four distinctive features of ovarian masses in pregnancy: the occurrence of an ovarian pregnancy or a trophoblastic lesion in the ovary, specific tumorlike lesions of the ovary, alteration of the morphologic features of sex cord-stromal tumors, and clinical hormonal manifestations, usually androgenic, due to stromal luteinization of a variety of tumors.

Three mass lesions that are particular to pregnancy are a luteoma of pregnancy; hyperreactio luteinalis; and the so-called large, solitary, luteinized follicular cyst of pregnancy and the puerperium.⁶ Luteomas of pregnancy are often bilateral and multinodular and composed of large cells with abundant eosinophilic cytoplasm. They often have mitotic activity, which can lead to an erroneous diagnosis of a malignant tumor. Hyperreactio luteinalis, which is typically associated with a pregnancy in which there is an abnormally high level of human chorionic gonadotropin, is almost always bilateral and is multicystic. In contrast to a luteoma of pregnancy, which is typically seen at or near term, hyperreactio luteinalis may be seen at any time during pregnancy. These two lesions regress post partum. Giant follicular cysts are typically seen at term and are almost always a huge unilocular cyst, averaging about 25 cm in maximum dimension.⁶ In addition, sizable hemorrhagic masses may be seen in cases of ovarian pregnancy. Occasionally, a small embryo is found in the midst of a hemorrhagic mass that, before pathological examination, was suspicious for a neoplasm.

Intercellular edema may alter the morphologic features of sex cord-stromal tumors during

pregnancy, causing them to simulate other neoplasms, particularly yolk-sac tumors.⁷ Finally, stromal luteinization of an ovarian neoplasm, most often a primary mucinous cystic tumor or a metastatic carcinoma with signet-ring cells (a Krukenberg tumor), may occur during pregnancy and be associated with dramatic androgenic manifestations.⁸

In this patient, both a home pregnancy test and a laboratory test for human chorionic gonadotropin were negative. Thus, we can rule out all these pregnancy-related conditions.

SMALL-CELL CARCINOMA OF THE HYPERCALCEMIC TYPE

Of the ovarian tumors that occur in the first three decades, small-cell carcinoma of the hypercalcemic type merits particular consideration in this case because it is the only one regularly associated with hypercalcemia.³ The only other ovarian tumor in the young that has been associated with hypercalcemia with any frequency is dysgerminoma.⁹ Although lymphoma may be associated with hypercalcemia, I do not know of an example in which there was an ovarian mass.

The small-cell carcinoma was recognized as a specific entity because of its distinctive morphologic and clinical features. In contrast to most undifferentiated ovarian carcinomas, which are composed of large cells with abundant cytoplasm, this tumor is typically composed of small cells. This tumor was considered a highly malignant form of granulosa-cell tumor because of the presence of follicles, a minor feature in many cases. The presence of follicles usually leads to the placement of the small-cell tumor in the group of malignant granulosa-cell tumors. There is no conclusive evidence that small-cell carcinoma is related to the granulosa-cell family of neoplasms. Small-cell carcinoma lacks neuroendocrine differentiation, in contrast to the more common small-cell carcinomas typically arising in the lung. Its histogenesis remains an enigma.

Small-cell carcinomas of the hypercalcemic type are clinically distinctive and are associated with hypercalcemia in two thirds of cases. They account for less than 0.01% of ovarian neoplasms; approximately 400 cases have been reported. They occur in patients who are younger than most of the patients in whom undifferentiated carcinomas occur. Despite their rarity, the diagnosis merits consideration in persons who are 10 to 35 years of age.

DYSGERMINOMA

Dysgerminoma shares a number of features with small-cell carcinoma of the hypercalcemic type, including a white, fleshy, gross appearance in many cases and occurrence in persons who are in their first three decades.^{3,10} In addition, dysgerminoma may be associated with hypercalcemia,⁹ although much less frequently than are small-cell tumors. Nevertheless, dysgerminoma is much more common than small-cell carcinoma and is thus a consideration in a young patient with an ovarian tumor and hypercalcemia. Microscopically, there should be little difficulty distinguishing between these two types of lesions because of differences in their morphologic features; immunohistochemical staining can also aid in the distinction.

SUMMARY

I think the working diagnosis should be small-cell carcinoma of hypercalcemic type, but pathological evaluation is needed to determine the nature of the neoplasm, and it would not be possible to rule out a dysgerminoma. Other tumor types are unlikely.

Dr. Nancy Lee Harris (Pathology): Dr. Goodman, would you discuss your approach to the diagnosis and initial management of this patient's condition?

Dr. Annekathryn Goodman: Our presumptive preoperative diagnosis was a malignant ovarian tumor. The surgical standard of care is complete removal of the uterus, both ovaries, and the fallopian tubes and surgical staging by means of biopsies of pelvic and paraaortic lymph nodes, peritoneal biopsies, and omentectomy, with resection of all visible tumor. However, fertility-conserving surgery should always be considered in young women, if it does not compromise adequate cancer therapy.¹¹ If the cancer does not involve the contralateral adnexa and uterus, they can be preserved in young patients, even if there is metastasis to other areas, such as the lymph nodes.¹² Unilateral sampling of lymph nodes on the side of the tumor should be considered; although spread to contralateral nodes has been reported, the most common nodal spread will be on the side of the tumor.¹³ The consequences of bilateral pelvic and paraaortic lymphadenectomies can be a lifelong change in lymphatic circulation and disruption of the autonomic nerve plexus that

courses with the lymphatics, leading to lymphedema, neuropathy, and bowel changes such as chronic constipation.¹⁴ Preoperative counseling with this patient included an in-depth discussion of these surgical choices. We planned, if possible, to perform unilateral oophorectomy, with preservation of the contralateral ovary and uterus, and to obtain staging biopsy specimens after unilateral dissection of the pelvic and paraaortic lymph nodes.

There are several reports on survival and reproductive outcomes after fertility-conserving surgery for young women with ovarian cancer.¹⁵⁻¹⁸ Fertility rates appear to be approximately 75% after such surgery is followed by chemotherapy for malignant ovarian germ-cell tumors.^{15,16} Among patients with ovarian epithelial tumors, the rates vary from 10% to more than 75%.^{17,18} These reports support fertility-conserving surgery for germ-cell tumors, even in patients with advanced disease.

In this patient, we performed an exploration through a large, vertical midline incision. We found a liter of bloody ascites and a large mass involving the left ovary (rather than the right ovary, as suggested by imaging studies), which had a smooth surface; the mass had ruptured. We resected the mass and performed left salpingo-oophorectomy, dissection of the left pelvic and paraaortic nodes, omentectomy, and appendectomy. It was unclear whether the tumor had ruptured because of its rapid growth or whether the rupture was secondary to examination before or at the time of surgery. Because of the large volume of ascites, which had not been present on imaging studies a day earlier, I favored the theory of rapid growth.

CLINICAL DIAGNOSIS

Ovarian cancer, probably small-cell carcinoma, hypercalcemic type.

DR. ROBERT H. YOUNG'S DIAGNOSIS

Ovarian small-cell carcinoma, hypercalcemic type.

PATHOLOGICAL DISCUSSION

Dr. Rosemary H. Tambouret: The left adnexa were sent to the pathology frozen-section laboratory for intraoperative evaluation. The ovary was great-

ly enlarged, weighing 890 g and measuring 18 cm in diameter. The surface was smooth except for a 9-cm region of disruption overlying a hemorrhagic cavity, corresponding to the clinical impression of rupture (Fig. 2A). Sectioning revealed a fleshy, tan, focally hemorrhagic tumor (Fig. 2B). Examination of a frozen section revealed a small round-cell tumor, the differential diagnosis of which includes small-cell carcinoma, hypercalcemic type; granulosa-cell tumor; and small-cell carcinoma, pulmonary type. Permanent sections showed focal follicle formation (Fig. 2C), found in 80% of cases of small-cell carcinomas of hypercalcemic type. The tumor cells were small, with scant cytoplasm, irregular nuclei, and a high mitotic rate (Fig. 2D). Neither large cells nor mucinous differentiation was seen; large cells can be seen focally in up to 50% of small-cell carcinomas of the hypercalcemic type, and mucinous differentiation in up to 10%. Immunohistochemical staining showed that the tumor cells were negative for inhibin, which rules out the diagnosis of granulosa-cell tumor. The tumor cells were positive for Wilms' tumor gene 1 and focally positive for epithelial membrane antigen (dual positivity is consistent with small-cell carcinomas of the hypercalcemic type), and negative for chromogranin and parathyroid hormone. On electron microscopy, the cells had vesicular endoplasmic reticulum in the cytoplasm that was characteristic of small-cell carcinoma of the hypercalcemic type, with no neurosecretory granules (Fig. 2E and 2F). The final diagnosis was small-cell carcinoma of the hypercalcemic type.

The tumor extended into the capsule, but there was no intravascular or lymphatic spread. Although no tumor was found in the submitted lymph nodes or omentum, the pelvic wash did contain poorly preserved atypical cells that were worrisome for small-cell carcinoma.

DISCUSSION OF MANAGEMENT

Dr. Richard T. Penson: The goals of postoperative treatment are the eradication of micrometastases, the reduction of the risk of local recurrence, and the preservation of quality of life. There is no standard of care for this rare tumor. Although this tumor is distinct from pulmonary-type small-cell carcinoma, treatment has been similar to the treatment for small-cell lung cancer. In the larg-

est report of cases of small-cell carcinoma of the hypercalcemic type, seven patients treated with cisplatin-based multiagent combinations of chemotherapy had good outcomes.³ Arguably, the most helpful publication to date is the first publication from the Gynecologic Cancer Intergroup, a group established to evaluate rare gynecologic tumors.¹⁹ Among the 10 patients with stage I tumors, median survival had not been reached (7 of the 10 patients were still in remission), as compared with a median survival of only 6 months in patients with advanced disease. The authors concluded that both radiation therapy and cisplatin-based chemotherapy were associated with improved disease-free survival, as compared with that among patients treated in the past with no radiation or carboplatin-based chemotherapy.

The combination of etoposide and cisplatin remains the standard therapy for small-cell carcinoma of the lung. Studies have suggested that there may be a benefit to adding paclitaxel for patients with limited-stage disease, which we elected to do in this case.²⁰ For a dosing schedule, we decided on a modification of the regimen of bleomycin, etoposide, and cisplatin that was used by the European Organisation for Research and Treatment of Cancer and the Medical Research Council in a trial (EORTC 30983/MRC TE21) for intermediate-prognosis germ-cell tumors. We did not give the bleomycin and administered four cycles of paclitaxel (135 mg per square meter of body-surface area given by 24-hour infusion to minimize neurotoxicity) on day 1, cisplatin (50 mg per square meter) on days 2 and 3, and etoposide (165 mg per square meter) on days 1, 2, and 3, with pegfilgrastim on day 4.

Staging of this patient's tumor by means of CT scans of the chest, abdomen, and pelvis and magnetic resonance imaging of the brain suggested that she had early-stage disease; however, the tumor had ruptured. Large, early-stage tumors that have ruptured (stage IC) are associated with a very poor prognosis, with survival reportedly as low as 10%. The rapid doubling time of the tumor prompted us to give early, inpatient, postoperative adjuvant chemotherapy, starting on postoperative day 7, even though randomized, controlled trials have suggested that this may only increase the complication rate for epithelial ovarian tumors and may not significantly affect survival. She was discharged after the first cycle

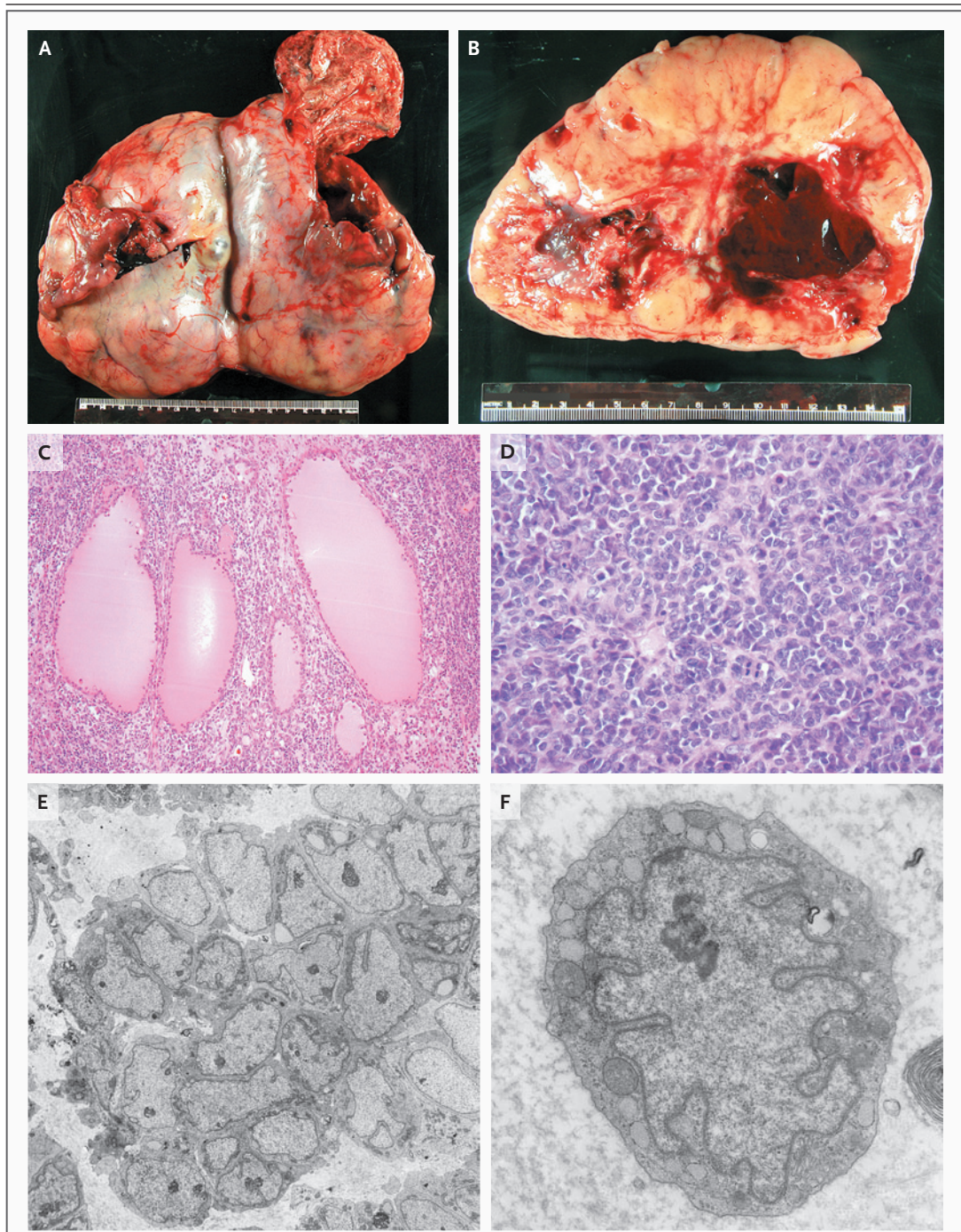


Figure 2. Ovarian Tumor.

The external surface of the ovary (Panel A) has a rough, red area of probable rupture on the right. The sectioned ovarian surface (Panel B) shows a tan, fleshy, vaguely lobulated tumor with central cavitation and hemorrhage. A histologic section (Panel C, hematoxylin and eosin, low magnification) shows small cells with scant cytoplasm and very rare follicle-like cystic spaces filled with eosinophilic fluid, features consistent with those seen in 80% of small-cell carcinomas of the hypercalcemic type. The tumor cells (Panel D, hematoxylin and eosin, high magnification) have scant cytoplasm, monotonous yet irregular nuclei, and brisk mitotic activity. An electron micrograph (Panel E) shows a grouped arrangement of the tumor cells, a feature consistent with carcinoma. On higher magnification (Panel F), no neurosecretory granules were identified; the dilated endoplasmic reticulum is often seen in small-cell carcinomas of the hypercalcemic type.

of chemotherapy, on the 12th hospital day, and received subsequent cycles also as an inpatient. She had no major complications.

Dr. Anthony H. Russell: Because of the rupture of the tumor, the entire peritoneal cavity was considered to be at risk for potential colonization by malignant cells. Thus, immediately following hematologic recovery after her fourth cycle of chemotherapy, consolidation radiotherapy was administered.¹⁹ Because of the large volume of normal tissues (bowel, liver, and kidneys) irradiated when the peritoneal cavity is targeted, whole-abdomen radiation is usually administered in fractions of 1.0 to 1.5 Gy (in contrast to the standard fractions of 1.8 to 2.0 Gy) to avoid excessive acute toxic effects. We were concerned that the slow rate of administration of conventional whole-abdomen radiation therapy would not keep pace with the proliferative potential of her rapidly doubling cancer. Since most reparable acute radiation damage is repaired within 6 hours, we decided to administer twice-daily fractions of 1.0 Gy, with a 6-hour intertreatment interval, to a total dose of 20 Gy within 12 days.²¹ To maintain hydration and to administer antiemetic and antidiarrheal medication, the patient was hospitalized during treatment. She had no complications.

Dr. Penson: In the search for a potential target for a consolidation strategy involving a new oral therapeutic agent, such as a tyrosine kinase in-

hibitor, Dr. John Iafrate (Pathology) performed a multiplex polymerase-chain-reaction assay and genotyping using the SNaPshot Multiplex System (Applied Biosystems). However, no genetic abnormality was identified.

It has now been 24 months since the patient's surgery, and she is in remission. She has a normal menstrual cycle, but her fertility has not been formally evaluated. Her fertility may have been compromised by radiation but is unlikely to have been affected by chemotherapy.

ANATOMICAL DIAGNOSIS

Ovarian small-cell carcinoma, hypercalcemic type.

This case was presented at the Obstetrics and Gynecology Grand Rounds, April 9, 2009.

Dr. Goodman reports delivering lectures in a Continuing Medical Education format for Symposia Medicus, and Dr. Penson, receiving research funding from Berlex Labs (now Bayer HealthCare Pharmaceuticals), PDL BioPharma, and Endocyte and serving on the scientific advisory boards of Abbott Laboratories and AstraZeneca. No other potential conflict of interest relevant to this article was reported. Disclosure forms provided by the authors are available with the full text of this article at NEJM.org.

We thank Drs. Elisabeth Baron, Obstetrics and Gynecology, and Elizabeth Munro, Fellow in Gynecologic Oncology — both at Massachusetts General Hospital — for their assistance in the care of the patient; Drs. Jonathan A. Ledermann, University College London, London, Michael Friedlander, University of New South Wales and Prince of Wales Hospital, Sydney, and Gordon Rustin, Mount Vernon Hospital, Northwood, United Kingdom, for advice on the chemotherapy regimen used; and Dr. Gillian M. Thomas, Toronto Sunnybrook Regional Cancer Centre, Toronto, for advice on the radiation treatment.

REFERENCES

- Lack EE, Young RH, Scully RE. Pathology of ovarian neoplasms in childhood and adolescence. *Pathol Annu* 1992;27:281-356.
- Young RH, Scully RE. Ovarian Sertoli-Leydig cell tumors with a retiform pattern: a problem in histopathologic diagnosis: a report of 25 cases. *Am J Surg Pathol* 1983;7:755-71.
- Young RH, Oliva E, Scully RE. Small cell carcinoma of the ovary, hypercalcemic type: a clinicopathological analysis of 150 cases. *Am J Surg Pathol* 1994;18:1102-16.
- Kiyokawa T, Young RH, Scully RE. Krukenberg tumors of the ovary: a clinicopathologic analysis of 120 cases with emphasis on their variable pathologic manifestations. *Am J Surg Pathol* 2006;30:277-99.
- Young RH, Kozakewich HP, Scully RE. Metastatic ovarian tumors in children: a report of 14 cases and review of the literature. *Int J Gynecol Pathol* 1993;12:8-19.
- Clement PB, Scully RE. Large solitary luteinized follicle cyst of pregnancy and puerperium: a clinicopathological analysis of eight cases. *Am J Surg Pathol* 1980;4:431-8.
- Young RH, Dudley AG, Scully RE. Granulosa cell, Sertoli-Leydig cell, and unclassified sex cord-stromal tumors associated with pregnancy: a clinicopathological analysis of thirty-six cases. *Gynecol Oncol* 1984;18:181-205.
- Scully RE, Morris JM. Functioning ovarian tumors. In: Meigs JV, Sturgis SH, eds. *Progress in gynecology*. Philadelphia: Grune & Stratton, 1957:20-34.
- Fleischhacker DS, Young RH. Dysgerminoma of the ovary associated with hypercalcemia. *Gynecol Oncol* 1994;52:87-90.
- Scully REYR, Clement PB. Tumors of the ovary, maldeveloped gonads, fallopian tube, and broad ligament. *Atlas Tumor Pathol* 1998;23:51-79.
- Zanetta G, Chiari S, Rota S, et al. Conservative surgery for stage I ovarian carcinoma in women of childbearing age. *Br J Obstet Gynaecol* 1997;104:1030-5.
- Dykgraaf RH, de Jong D, van Veen M, Ewing-Graham PC, Helmerhorst TJ, van der Burg ME. Clinical management of ovarian small-cell carcinoma of the hypercalcemic type: a proposal for conservative surgery in an advanced stage of disease. *Int J Gynecol Cancer* 2009;19:348-53.
- Walter AJ, Magrina JF. Contralateral pelvic and aortic lymph node metastasis in clinical stage I epithelial ovarian cancer. *Gynecol Oncol* 1999;74:128-9.
- Mittendorf EA, Hunt KK. Lymphatic interrupted: do we really understand the risks and consequences? *Ann Surg Oncol* 2009;16:1768-70.
- de La Motte Rouge T, Pautier P, Duville P, et al. Survival and reproductive function of 52 women treated with surgery and bleomycin, etoposide, cisplatin (BEP) chemotherapy for ovarian yolk sac tumor. *Ann Oncol* 2008;19:1435-41.
- Gershenson DM, Miller AM, Champion VL, et al. Reproductive and sexual function after platinum-based chemotherapy in long-term ovarian germ cell tumor survivors: a Gynecologic Oncology Group study. *J Clin Oncol* 2007;25:2792-7.

17. Muzii L, Palaia I, Sansone M, et al. Laparoscopic fertility-sparing staging in unexpected early stage ovarian malignancies. *Fertil Steril* 2009;91:2632-7.
18. Park JY, Kim DY, Suh DS, et al. Outcomes of fertility-sparing surgery for invasive epithelial ovarian cancer: oncologic safety and reproductive outcomes. *Gynecol Oncol* 2008;110:345-53.
19. Harrison ML, Hoskins P, du Bois A, et al. Small cell of the ovary, hypercalcemic type — analysis of combined experience and recommendation for management: a GCIg study. *Gynecol Oncol* 2006;100:233-8.
20. Reck M, von Pawel J, Macha HN, et al. Efficient palliation in patients with small-cell lung cancer by a combination of paclitaxel, etoposide and carboplatin: quality of life and 6-years'-follow-up results from a randomised phase III trial. *Lung Cancer* 2006;53:67-75.
21. Fein DA, Morgan LS, Marcus RB Jr, et al. Stage III ovarian carcinoma: an analysis of treatment results and complications following hyperfractionated abdominopelvic irradiation for salvage. *Int J Radiat Oncol Biol Phys* 1994;29:169-76.

Copyright © 2010 Massachusetts Medical Society.

LANTERN SLIDES UPDATED: COMPLETE POWERPOINT SLIDE SETS FROM THE CLINICOPATHOLOGICAL CONFERENCES

Any reader of the *Journal* who uses the Case Records of the Massachusetts General Hospital as a teaching exercise or reference material is now eligible to receive a complete set of PowerPoint slides, including digital images, with identifying legends, shown at the live Clinicopathological Conference (CPC) that is the basis of the Case Record. This slide set contains all of the images from the CPC, not only those published in the *Journal*. Radiographic, neurologic, and cardiac studies, gross specimens, and photomicrographs, as well as unpublished text slides, tables, and diagrams, are included. Every year 40 sets are produced, averaging 50-60 slides per set. Each set is supplied on a compact disc and is mailed to coincide with the publication of the Case Record.

The cost of an annual subscription is \$600, or individual sets may be purchased for \$50 each. Application forms for the current subscription year, which began in January, may be obtained from the Lantern Slides Service, Department of Pathology, Massachusetts General Hospital, Boston, MA 02114 (telephone 617-726-2974) or e-mail Pathphotoslides@partners.org.