



Differences in white matter reflect atypical developmental trajectory in autism: A Tract-based Spatial Statistics study#

Citation

Bakhtiari, Reyhaneh, Nicole R. Zürcher, Ophélie Rogier, Britt Russo, Loyse Hippolyte, Cristina Granziera, Babak Nadjar Araabi, Majid Nili Ahmadabadi, and Nouchine Hadjikhani. 2012. "Differences in white matter reflect atypical developmental trajectory in autism: A Tract-based Spatial Statistics study#." *NeuroImage : Clinical* 1 (1): 48-56. doi:10.1016/j.nicl.2012.09.001. <http://dx.doi.org/10.1016/j.nicl.2012.09.001>.

Published Version

doi:10.1016/j.nicl.2012.09.001

Permanent link

<http://nrs.harvard.edu/urn-3:HUL.InstRepos:11878928>

Terms of Use

This article was downloaded from Harvard University's DASH repository, and is made available under the terms and conditions applicable to Other Posted Material, as set forth at <http://nrs.harvard.edu/urn-3:HUL.InstRepos:dash.current.terms-of-use#LAA>

Share Your Story

The Harvard community has made this article openly available. Please share how this access benefits you. [Submit a story](#).

[Accessibility](#)



Differences in white matter reflect atypical developmental trajectory in autism: A Tract-based Spatial Statistics study[☆]



Reyhaneh Bakhtiari^{a,b,c}, Nicole R. Zürcher^c, Ophélie Rogier^c, Britt Russo^c, Loyse Hippolyte^c, Cristina Granziera^c, Babak Nadjar Araabi^{a,b}, Majid Nili Ahmadabadi^{a,b}, Nouchine Hadjikhani^{c,d,*}

^a Control and Intelligent Processing Center of Excellence, School of Electrical and Computer Engineering, College of Engineering, University of Tehran, Tehran, Iran

^b Department of Cognitive Sciences, Institute for Research in Fundamental Sciences (IPM), Tehran, Iran

^c Brain Mind Institute, Ecole Polytechnique Fédérale, Lausanne, Switzerland

^d Athinoula A. Martinos Center for Biomedical Imaging, Massachusetts General Hospital, Harvard Medical School, Charlestown, MA, USA

ARTICLE INFO

Article history:

Received 9 July 2012

Received in revised form 20 August 2012

Accepted 3 September 2012

Available online 12 September 2012

Keywords:

Diffusion Tensor Imaging
Autism spectrum disorder
Brain connectivity
Fractional anisotropy
Brain development
Brain maturation

ABSTRACT

Autism is a neurodevelopmental disorder in which white matter (WM) maturation is affected. We assessed WM integrity in 16 adolescents and 14 adults with high-functioning autism spectrum disorder (ASD) and in matched neurotypical controls (NT) using diffusion weighted imaging and Tract-based Spatial Statistics. Decreased fractional anisotropy (FA) was observed in adolescents with ASD in tracts involved in emotional face processing, language, and executive functioning, including the inferior fronto-occipital fasciculus and the inferior and superior longitudinal fasciculi. Remarkably, no differences in FA were observed between ASD and NT adults.

We evaluated the effect of age on WM development across the entire age range. Positive correlations between FA values and age were observed in the right inferior fronto-occipital fasciculus, the left superior longitudinal fasciculus, the corpus callosum, and the cortical spinal tract of ASD participants, but not in NT participants.

Our data underscore the dynamic nature of brain development in ASD, showing the presence of an atypical process of WM maturation, that appears to normalize over time and could be at the basis of behavioral improvements often observed in high-functioning autism.

© 2012 The Authors. Published by Elsevier Inc. All rights reserved.

1. Introduction

Autism Spectrum Disorders (ASD) are complex neurodevelopmental disorders affecting as many as 1 in 88 children (CDC 2012). Individuals with ASD are characterized by early onset impairments in communication and reciprocal social interaction as well as by the presence of repetitive and stereotyped behaviors.

Abbreviations: ADOS, Autism Diagnostic Observation Schedule; ADI-R, Autism Diagnostic Interview-Revised; AQ, Autism Quotient; ASD, Autism Spectrum Disorders; ATR, anterior thalamic radiations; CC, corpus callosum; CT, corticospinal tract; DTI, Diffusion Tensor Imaging; DTT, Diffusion Tensor Tractography; EF, executive functions; FA, fractional anisotropy; IFOF, inferior fronto-occipital fasciculus; ILF, inferior longitudinal fasciculus; NT, neurotypical; PIQ, Performance Intelligence Quotient; SLF, superior longitudinal fasciculus; TBSS, Tract-based Spatial Statistics; TFCE, Threshold-free Cluster Enhancement; TE, echo time; TR, repetition time; UNC, uncinate fasciculus; VBM, Voxel-Based Morphometry; VBS, Voxel based Statistics of FA Images (VBM-like); WM, white matter.

[☆] This is an open-access article distributed under the terms of the Creative Commons Attribution-NonCommercial-ShareAlike license, which permits non-commercial use, distribution, and reproduction in any medium, provided the original author and source are credited.

* Corresponding author at: MGH/HMS/HST Athinoula A. Martinos Center for Biomedical Imaging, 149 13th Street, Charlestown, MA 02129. Tel.: +1 617 724 5625; fax: +1 530 309 4973.

E-mail address: nouchine@nmr.mgh.harvard.edu (N. Hadjikhani).

There is evidence that brain development in individuals with ASD follows a different trajectory than that of neurotypicals (NT). At birth, brain size of individuals later diagnosed with ASD is normal (Courchesne et al., 2003; Lainhart et al., 1997). However, in contrast to typically developing children, brain size rapidly increases during the first few years of life up to ages 2 to 4 years in children with autism, particularly in frontal regions (Courchesne et al., 2001; Hazlett et al., 2011; Sparks et al., 2002). The observed increase tends to stabilize during adolescence, resulting in a normal brain size in adulthood (Redcay and Courchesne, 2005), but see Piven et al. (1996). Brain enlargement has been associated with increases in WM volume (Ben Bashat, 2011; Hazlett et al., 2011; Herbert et al., 2004).

WM developmental changes have been studied using Diffusion Tensor Imaging (DTI), a method based on local microstructural characteristics of water diffusion (Basser and Jones, 2002; Basser and Pierpaoli, 1996; Le Bihan et al., 2001). Direction-dependent diffusivity of water molecules is reflected in fractional anisotropy (FA) (Basser and Pierpaoli, 1996), a quantitative index which is sensitive to developmental and pathological differences, such as axon myelination, diameter distribution, axon density, and architecture of WM fibers (Beaulieu, 2002; Pierpaoli et al., 2001).

To date, three main approaches have been used to analyze DTI data (Jones, 2010). The first method, widely used in autism research,

Table 2

Regions with significant ($p < 0.05$, corrected for multiple comparisons) reduced fractional anisotropy (FA) in adolescents with ASD vs. NT, after correction for age, gender, and brain size.

		MNI coordinates		
		x	y	z
Inferior fronto-occipital fasciculus	L	-28	13	4
	R	36	-29	0
Inferior longitudinal fasciculus	L	-41	-24	-5
	R	39	-25	-2
Superior longitudinal fasciculus	L	-35	-20	30
	R	33	-17	33
Uncinate fasciculus	L	-29	12	-4
	R	33	0	-10
Anterior thalamic radiation	L	-6	-7	0
	R	11	-23	-10
Cingulum (hippocampus)	R	26	-29	-13
	L	-7	4	33
Cortico-spinal tract	R	9	-5	35
	L	-26	-18	34
Genu of corpus callosum	R	25	-19	14
	L	-1	21	13
Body of corpus callosum	R	15	22	20
	L	-13	-5	32
Splenium of corpus callosum	R	16	-14	35
	L	-19	-36	29
Forceps major	R	15	-35	25
	L	26	-53	7
Forceps minor	L	14	26	17

tensor is expressed in terms of three eigenvectors and eigenvalues. FA was calculated using eigenvalues of tensor: $\lambda_1 > \lambda_2 > \lambda_3$. Subjects' FA data were aligned into a common space using the nonlinear registration tool FNIRT (Andersson et al., 2007a, b), which uses a b-spline representation of the registration warp field (Rueckert et al., 1999). In the next step, the mean FA image was created and thinned to create a mean FA skeleton representing the centers of all tracts common to the whole study group. To exclude gray matter or CSF,

the mean FA skeleton was thresholded at 0.2. This threshold parameter also controls for cross-subject variability. Each subject's aligned FA data was then projected onto this WM skeleton. First, between-group analyses were conducted in adolescents and adults. The skeletonized FA data were fed into voxel-wise cross subject statistics. Age, brain size, and gender were entered as additional covariates, in order to remove potential effects due to differences in those factors between the two groups (ASD vs. NT). To calculate brain size, total intracranial volume (TIV) was used. TIV was found after deleting non-brain tissue from T1-image of the whole head, using FSL Brain Extraction Tool (BET) (Smith, 2002). Given that previous studies have shown that the distribution of FA data is substantially non-Gaussian (Jones et al., 2005; Smith et al., 2006), a non-parametric two-sample permutation test was performed to study between-group (ASD vs. NT) differences using the randomise tool available in FSL (<http://www.fmrib.ox.ac.uk/fsl/randomise/index.html>), using 5000 permutations. Threshold-free Cluster Enhancement (TFCE) was performed in order to enhance cluster-like structures without prior definition of a cluster-forming threshold or extensive data smoothing (Smith and Nichols, 2009). In order to control for multiple voxel-wise comparisons, family-wise error correction was performed and the resulting significance threshold was $p < 0.05$, corrected for multiple comparisons.

In order to assess whether WM maturation was different between groups (ASD and NT), we tested if an interaction $\text{group} \times \text{age}$ was present. A model was created such that age was entered as a covariate split according to groups, but demeaned across groups. The contrasts of interest, which consisted of the positive correlations between FA and age for each group [ASD: 0 0 1 0; NT: 0 0 0 1], and the $\text{group} \times \text{age}$ interactions [ASD > NT: 0 0 1 -1; ASD < NT: 0 0 -1 1] were computed using a 2-sample *t*-test.

In order to examine the relationships between WM integrity and behavior, we looked at correlations between FA values and scores in the ADOS and the ADI-R in adolescents and adults, separately.

Finally, to assess the influence of autism traits, measured with AQ, we examined the correlations between FA and AQ values in the entire population studied (ASD and NT, across all ages).

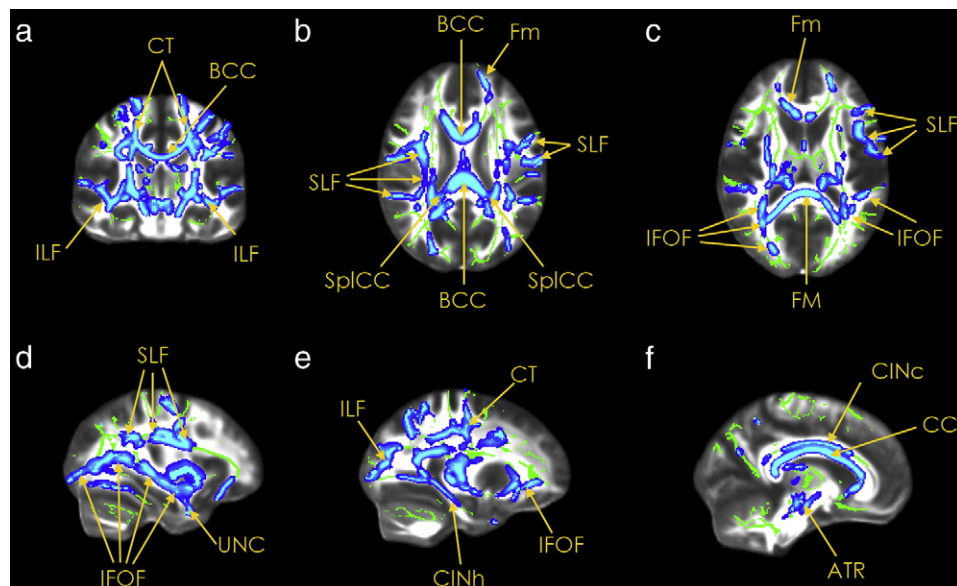


Fig. 1. Coronal (panel a), horizontal (panels b,c) and sagittal (panels d,e,f) sections showing areas of significantly decreased FA ($p < 0.05$, corrected) in ASD adolescents compared with age-matched controls, displayed on the MNI template brain. There are no regions where FA is significantly higher in the ASD group. Regions of decreased FA in ASD are highlighted on the mean FA skeleton (green) in colored voxels (scale ranging from blue to light blue). For visualization purposes, the stats images are 'thickened' with `tbss_fill`. MNI coordinates of each panel are as follows: a: $y = 106$; b: $z = 96$ c: $z = 86$; d: $x = 123$; e: $x = 64$; and f: $x = 81$. CT: cortico-spinal tract; BCC: body of corpus callosum; ILF: inferior longitudinal fasciculus; SLF: superior longitudinal fasciculus; SplCC: splenium of corpus callosum; Fm: forceps minor; FM: forceps major; IFOF: inferior fronto-occipital fasciculus; UNC: uncinate; CINh: cingulum, hippocampal region; CINc: cingulum, cingulate region; CC: corpus callosum.

Table 3

Regions in which fractional anisotropy (FA) is positively correlated with age across the entire age range (combined adolescents and adults), and group (ASD and NT) × age interaction.

Group			MNI coordinates			t-Peak	Size	
			x	y	z			
ASD	R	Anterior thalamic radiation	11	-9	10	7.05	466	
	L		-3	-11	4	6.66	465	
	R	Cingulum (hippocampus)	23	-27	-14	4.04	141	
	L		-19	-40	-5	5.21	130	
	R	Inferior fronto-occipital fasciculus	33	8	-1	4.90	136	
	L	Superior longitudinal fasciculus	-50	-10	19	3.69	104	
	L	Corticospinal tract	-21	-21	-2	5.72	52	
	R		18	-15	-6	3.02	32	
	R	Cingulum (cingulate)	8	-20	34	4.01	37	
	L	Body of corpus callosum	-8	-28	25	4.26	33	
	R		15	-22	31	4.26	23	
		Splenium of corpus callosum	6	-37	11	5.31	32	
	NT	L	Anterior thalamic radiation	-9	-17	8	5.15	502
		R		8	-12	16	6.37	303
R		Cingulum (hippocampus)	27	-21	-22	4.67	45	
L			-20	-35	-10	4.04	42	
L		Cingulum (cingulate gyrus)	-9	9	30	4.84	37	
R		9	8	31	4.46	26		
<i>Group × age</i>								
ASD > NT	R	Body of corpus callosum	13	-15	32	4.38	84	
	L	Superior longitudinal fasciculus	-42	-40	31	4.28	30	
	R		28	-32	35	3.89	32	
ASD < NT	None							

Significance threshold was $p < 0.001$, corresponding to a t value > 3.0 , combined with a cluster size ≥ 23 voxels (5000 permutations without variance smoothing.)

Anatomical location was determined using the JHU White-Matter Tractography and JHU ICBM-DTI-81 White-Matter Labels atlases.

3. Results

3.1. Between-group (ASD vs. NT) FA analysis

3.1.1. Adolescents (Table 2, Fig. 1)

Adolescents with ASD showed decreased FA values bilaterally over a very large region (1 cluster of 35,405 voxels) compared to NT. Within this large cluster, peaks showing significant differences compared to NT were observed in tracts specified in Table 2. Decreased FA values were found bilaterally in the inferior fronto-occipital

fasciculus (IFOF), the inferior longitudinal fasciculus (ILF), the superior longitudinal fasciculus (SLF), the uncinate fasciculus (UNC), the anterior thalamic radiation (ATR), the cingulum in its cingulate section, the corticospinal tract (CT) and in the corpus callosum (CC), as well as in the right forceps major and minor, and in the right hippocampus section of the cingulum (see Fig. 1).

3.1.2. Adults

Remarkably, there were no significant differences in FA values in any tract between ASD and NT adults.

3.1.3. Age group comparisons (adolescents vs. adults)

In addition, a direct comparison was conducted between the two age groups in both NT and in ASD.

In NT, significant differences between adolescents and adults were found in several large clusters located bilaterally in the ATR, the CT, the IFOF as well as in the left ILF and SLF.

In ASD, significant differences between adolescents and adults were found bilaterally in the ATR, CT, cingulum (cingulate) IFOF, ILF, SLF, UNC, body and splenium of CC, as well as in the right cingulum (hippocampus), the right genu of CC, the forceps major and the forceps minor.

3.2. Developmental changes of FA – correlation between FA and age (Table 3, Fig. 2)

We examined the interaction between FA and age in ASD and NT, across the entire age range. In NT, positive correlations between FA values and age were found bilaterally in the ATR, as well as in the hippocampal and the cingulate divisions of the cingulum.

In participants with ASD, positive correlations between FA values and age were observed bilaterally in the ATR, the cingulum (hippocampus), the CT, the body and splenium of the CC, as well as in the right cingulum (cingulate) and IFOF, and the left SLF.

Significant group × age interactions were found for the contrast ASD > NT. They were located in the body of the CC and the SLF (see Fig. 2).

3.3. Correlations between FA and behavioral measures

3.3.1. ASD adolescents

In adolescents with ASD, FA values in the IFOF were negatively correlated with communication scores in both ADOS and ADI-R. In

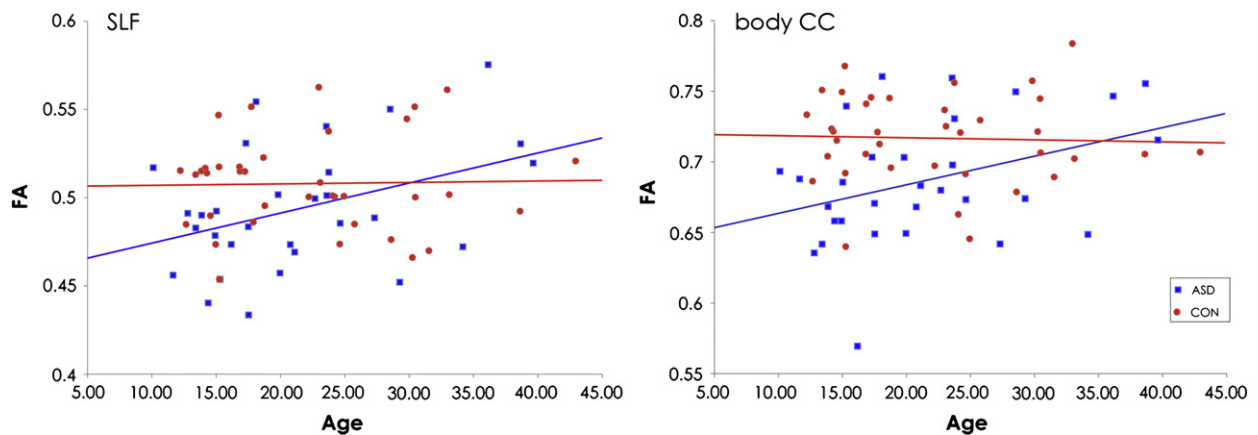


Fig. 2. Correlations between age and FA in ASD and NT in the body of CC and the SLF. Blue squares and line represent values for ASD, red circles and line represent value for NT (CON). Left panel: SLF, ASD: $r = 0.41$, $p = 0.03$; NT: $r = 0.02$, $p = ns$. Right panel: body of CC, ASD: $r = 0.38$, $p = 0.04$; NT: $r = -0.04$, $p = ns$.

Table 4
Regions in which fractional anisotropy (FA) is negatively correlated with ADI and ADOS scores in ASD adolescents.

Behavioral score		Correlation		MNI coordinates			t-Peak	Size
				x	y	z		
ADOS(COM)	Negative	R	Inferior fronto-occipital fasciculus	40	−40	−4	5.17	23
ADOS(SOC)	Negative	L	Inferior longitudinal fasciculus	−42	−39	−7	5.39	59
		R		41	−44	−3	4.05	25
ADI-R(COM)	Negative	L	Corticospinal tract	−23	−19	37	3.86	65
		L	Superior longitudinal fasciculus	−29	−28	38	4.76	63
		L	Inferior fronto-occipital fasciculus	−35	−27	−1	4.64	29
ADI-R(SOC)	Negative	L	Corticospinal tract	−22	−18	37	4.9	71
		L	Hippocampus	−28	−25	−23	4.02	40
		R	Inferior longitudinal fasciculus	38	−53	−2	4.26	28

addition, the left SLF was also negatively correlated with communication scores in the ADI-R. The ILF FA values were negatively correlated with social scores in both ADOS and ADI-R (Table 4).

3.3.2. ASD adults

In adults with ASD, FA values in the IFOF were negatively correlated with communication scores in the ADOS, and with social scores in the ADOS and the ADI-R. The FA values in the ILF were negatively correlated with social scores in the ADOS, and those of the splenium of the CC with the ADI-R communication scores (Table 5).

3.3.3. ASD and NT, all ages, correlation with AQ

Higher AQ scores, corresponding to a higher presence of autistic traits, were correlated with lower FA in the right SLF (48, −45, −5; $t = 4.06$), the left cingulum (hippocampus) (−18, −39, −5; $t = 3.02$) and the left CT (−23, −19, 43; $t = 3.35$) (Table 6).

4. Discussion

In this study, we examined neurodevelopmental changes in WM tracts in adolescents and adults with high-functioning ASD compared to age- and IQ-matched NT controls, using TBSS, an automated tract-based analysis. To our knowledge, this is the first TBSS study investigating WM maturation and integrity in both adults and adolescents with ASD.

DTI studies using other approaches than TBSS in adults with ASD are limited to a few reports (Bloemen et al., 2010; Catani et al., 2008; Pugliese et al., 2009; Thakkar et al., 2008; Thomas et al., 2011). Absence of differences in FA measurements in adults with ASD (Thomas et al., 2011) and Asperger syndrome (Pugliese et al.,

2009), and decreased FA values in the cerebellum have been reported (Catani et al., 2008), using DTT. Using whole brain approach and VBS, reduced FA in large clusters in the brain has been described (Bloemen et al., 2010). However, as underlined by the authors, this method does not allow associations with specific tracts.

In the present study, we observed an alteration of WM reflected by a decreased FA in adolescents with ASD in several tracts including the IFOF, ILF and SLF. In adults, however, no significant differences were observed between groups. These findings suggest the presence of an abnormal pattern of WM development in ASD that normalizes over time.

In addition, positive correlation between FA value and age persisting into adulthood was observed in individuals with ASD, in the right IFOF, the left SLF, the bilateral CT and CC, while this was not the case in NT.

Finally, we showed that behavioral difficulties in the social and communicative domains were correlated with the FA values in specific tracts sustaining these functions.

4.1. Processing and regulation of emotions

Decreased FA was found in adolescents with ASD bilaterally in the ILF, a pathway connecting the occipital cortex with the anterior temporal lobes and amygdala. FA values in the ILF were negatively correlated with ADOS social scores in both adolescents and adults. Decreased FA was also found in the IFOF, connecting the occipital cortex through the uncinate fasciculus, and terminating in the orbitofrontal cortex (Catani et al., 2002; Catani et al., 2003), and a negative correlation between FA in IFOF was found with ADOS and ADI-R communication scores in adolescents and in adults. These

Table 5
Regions in which fractional anisotropy (FA) is correlated with ADI and ADOS scores in adults with ASD.

Behavioral score		Correlation		MNI coordinates			t-Peak	Size
				x	y	z		
ADOS(COM)	Negative	R	Forceps major	16	−85	22	4.4	73
		L	Inferior fronto-occipital fasciculus	−40	−23	−10	5.35	42
		R		37	−22	−7	4.35	39
ADOS(SOC)	Negative	L	Inferior longitudinal fasciculus	−46	−9	−14	8.53	46
		R	Forceps major	16	−85	22	4.35	38
		R	Inferior fronto-occipital fasciculus	38	−22	−8	5.24	23
ADI-R(COM)	Positive	L	Corticospinal tract	−22	−24	30	4.67	95
	Negative	R	Splenium of corpus callosum	21	−46	7	5.47	43
ADI-R(SOC)	Positive	L	Corticospinal tract	−22	−28	46	8.6	46
		R		19	−27	53	6.4	37
	Negative	R	Inferior fronto-occipital fasciculus	20	−87	−4	3.75	51
		L	Hippocampus	−23	−28	−16	3.13	23

Table 6

Regions in which fractional anisotropy (FA) is correlated with AQ scores in the entire population studied (NT and ASD, across all ages).

Behavioral score	Correlation			MNI coordinates			t-Peak	Size
				x	y	z		
AQ	Negative	L	Corticospinal tract	−23	−19	43	3.35	50
		R	Superior longitudinal fasciculus (temporal part)	48	−45	−5	4.06	30
		L	Hippocampus	−18	−39	−5	3.02	27

pathways play an important role in the feed-forward cascade of face information conveyed from the occipito-temporal regions, including the Fusiform Face Area (FFA) anteriorly to emotion-related regions, including the amygdala and the orbitofrontal cortex (Philippi et al., 2009). The right ILF plays an important role in the recognition of emotional facial expressions (Kleinbans et al., 2008; Pugliese et al., 2009) and damages to the right ILF after a stroke have been associated with emotion recognition impairments (Philippi et al., 2009). Damage to the right IFOF results in overall facial emotion recognition impairment, specifically for sadness, anger and fear, and it has been suggested that impairment in fear recognition can result from a damage to the IFOF (Philippi et al., 2009).

In line with previous studies (Barnea-Goraly et al., 2010; Jou et al., 2011; Noriuchi et al., 2010; Shukla et al., 2011a, but see Weinstein et al., 2011), we found a reduced FA in the cingulum in adolescents with ASD. The cingulum is medial to the cingulate gyrus and connects the medial frontal cortex to the posterior cingulate (part of the limbic system), precuneus, and thalamus (van den Heuvel et al., 2008), and plays a key role as a mediator between the different components of the limbic system and in emotion regulation.

4.2. Language processing

A decreased FA was found in adolescents with ASD bilaterally in the ILF. Abnormalities in the ILF in ASD have been observed in other studies (Brito et al., 2009; Jou et al., 2011; Pugliese et al., 2009; Shukla et al., 2011a; Sundaram et al., 2008). The left ILF is involved in language (Mandonnet et al., 2007). Decreased ILF volume has been reported in high-functioning children with ASD (Waiter et al., 2005), and a decreased FA in this region was reported by Jou et al. in children with ASD (Jou et al., 2010; Jou et al., 2011).

In adolescents with ASD, alterations in myelin structure were also observed bilaterally in the SLF, a pathway connecting the frontal lobes to temporal and parietal lobes (Wakana et al., 2004). The SLF is involved in the integration of the auditory and speech areas of the brain. The left SLF is important for information exchange between Broca's and Wernicke's areas. Slower neural transmission in this region, due to altered myelin structure, has been reported in recent studies (Shukla et al., 2011b; Weinstein et al., 2011), and may be at the basis of language deficits in ASD (Levy et al., 2010). In adolescents, FA values in the left SLF were positively correlated with ADI-R communication scores. Abnormalities in the right SLF have also been associated with attention deficits (Konrad et al., 2010). Our findings replicate data from other groups showing abnormalities in the SLF in children with ASD (Barnea-Goraly et al., 2010; Jou et al., 2010; Noriuchi et al., 2010; Weinstein et al., 2011). In addition, we observed that across all participants, FA values in the right SLF were correlated with autistic traits.

4.3. Executive functioning

A positive correlation between FA in the SLF and executive function (EF) performance has been shown in typically developing children, independent of age (Vestergaard et al., 2011). Executive

functions (EF) include skills required for action planning and execution, inhibition, organization, self-monitoring, cognitive flexibility and set-shifting. The EF hypothesis is one of the proposed theories to explain the triad of impairments in autism (Hughes and Russell, 1993; Ozonoff et al., 1991), and EF impairments have been documented in ASD (Benetto et al., 1996; Hughes et al., 1994; Just et al., 2007; Minshew et al., 2002; Ozonoff and Jensen, 1999; Ozonoff and McEvoy, 1994; Ozonoff et al., 1991). A few studies have investigated the nature and extent of developmental changes in EF. In a 3-year follow-up study, no significant improvements were observed in planning efficiency and perseverative responses of young children with autism (mean age 12.4 years) (Ozonoff and McEvoy, 1994). Griffith et al., reported the same finding regarding perseverative errors in autistic children (mean age 4.3 years) over a 1-year period (Griffith et al., 1999). In a recent study examining a 3-year period, Pellicano showed that children (mean age 5.6 years) with ASD obtained significantly lower planning scores than typical controls. Over time, although EF abilities improved significantly in both groups, children with ASD made significantly more gains in planning tasks than typical children (Pellicano, 2010). In line with the behavioral developmental results described above, we observed WM differences in the SLF in the younger group. Those differences were absent in the adult group, pointing to a maturational aspect, rather than to persistent structural abnormalities.

A reduced FA in the CT, also reported in Brito et al. (2009) and Shukla et al. (2011a) may be related to the clumsiness often reported in ASD.

In accordance with several DTI studies (Alexander et al., 2007; Brito et al., 2009; Keller et al., 2007; Kumar et al., 2010; Noriuchi et al., 2010; Shukla et al., 2011a), we observed a reduced FA in adolescents with ASD in the genu, body and splenium of the CC. Differences in callosal size has been reported in children with autism, with the rostral body tending to normalize by mid-adolescence (Frazier et al., 2012). Here we also found a negative correlation between the splenium of the CC and the ADI-R communication scores in adults. Correlation with age in the CC was significantly different between groups when considering the entire age range. The corpus callosum is involved in the interhemispheric connection of multiple brain areas and is important for motor coordination, as well as for higher-order cognition and emotional and social functioning (Paul et al., 2007).

Developmental studies report a gradual increase of the FA from childhood until twenties in the CC, the ILF, the SLF and the IFOF in typical development (Lebel et al., 2008; Snook et al., 2005). Maturation of the brain is heterogeneous and variable during post-natal development (Gogtay et al., 2004; Golarai et al., 2007; Luna et al., 2004; Scherf et al., 2007) and may be especially sensitive to factors affecting the speed of neuronal maturation as well as myelin development, which may play a major role in autism etiology (Chomiak et al., 2010; Rodier, 2004). Our data indicate that in adolescents with ASD, the substrate of higher integrative functions (including areas involved in speech processing, executive functions, and the processing and regulation of emotions) may be particularly altered during development. A recent comprehensive review reporting the results of all DTI studies in autism between 2004 and 2012 (Travers et al., 2012) underlines the atypical developmental trajectory of white matter in autism.

5. Conclusion

During typical development, maturation of WM tracts is accompanied by an increase in FA. Our data showed a reduced FA in WM in adolescents with ASD compared with age-matched controls. Additionally, DTI indices of fiber tracts involved in language, executive functions, as well as in facial and emotional processing showed a clear positive correlation with age in ASD. Differences of WM were however absent in adults. Several studies report a decrease of the behavioral difficulties experienced by high-functioning individuals with ASD as they enter adulthood (Howlin et al., 2004; Seltzer et al., 2003; Shattuck et al., 2007). The present results, showing a normalization of diffusion indices over time, may represent one of the mechanisms underlying this behavioral amelioration. Moreover, the present data suggest that it is the time trajectory, rather than a qualitative difference, that differentiates brain maturation in ASD. Further histological studies should confirm that normalization observed in the MRI parameters corresponds to WM normalization.

Acknowledgments

We thank K. Métrailler for her support in participants' recruitment, C. Burget for her administrative assistance, and A. Lissot for his help with data analysis and technical support. Funding: This work was supported by the Swiss National Foundation grant # PP00P3-130191/PPOOB-110741 to NH, and by the Centre d'Imagerie BioMédicale (CIBM) of the University of Lausanne (UNIL), the Swiss Federal Institute of Technology Lausanne (EPFL), the University of Geneva (UniGe), the Centre Hospitalier Universitaire Vaudois (CHUV), the Hôpitaux Universitaires de Genève (HUG) and the Leenaards and the Jeantet Foundations.

References

- Abe, O., Yamasue, H., Aoki, S., Suga, M., Yamada, H., Kasai, K., Masutani, Y., Kato, N., Kato, N., Ohtomo, K., 2008. Aging in the CNS: comparison of gray/white matter volume and diffusion tensor data. *Neurobiology of Aging* 29, 102–116.
- Alexander, A.L., Lee, J.E., Lazar, M., Boudos, R., DuBray, M.B., Oakes, T.R., Miller, J.N., Lu, J., Jeong, E.K., McMahon, W.M., Bigler, E.D., Lainhart, J.E., 2007. Diffusion tensor imaging of the corpus callosum in autism. *NeuroImage* 34, 61–73.
- Ameis, S.H., Fan, J., Rockel, C., Voineskos, A.N., Lobaugh, N.J., Soorya, L., Wang, A.T., Hollander, E., Anagnostou, E., 2011. Impaired structural connectivity of socio-emotional circuits in Autism Spectrum Disorders: a diffusion tensor imaging study. *PLoS One* 6, e28044.
- Andersson, J.L.R., Jenkinson, M., Smith, S., 2007a. Non-linear optimisation. *FMRIB Technical Report TR07JA1*.
- Andersson, J.L.R., Jenkinson, M., Smith, S., 2007b. Non-linear registration, aka spatial normalisation. *FMRIB Technical Report TR07JA2*.
- Barnea-Goraly, N., Menon, V., Eckert, M., Tamm, L., Bammer, R., Karchemskiy, A., Dant, C.C., Reiss, A.L., 2005. White matter development during childhood and adolescence: a cross-sectional diffusion tensor imaging study. *Cerebral cortex (New York, N.Y.: 1991)* 15, 1848–1854.
- Barnea-Goraly, N., Lotspeich, L.J., Reiss, A.L., 2010. Similar white matter aberrations in children with autism and their unaffected siblings: a diffusion tensor imaging study using tract-based spatial statistics. *Archives of General Psychiatry* 67, 1052–1060.
- Baron-Cohen, S., Hoekstra, R.A., Knickmeyer, R., Wheelwright, S., 2006. The Autism-Spectrum Quotient (AQ) – adolescent version. *Journal of Autism and Developmental Disorders* 36, 343–350.
- Barrick, T.R., Charlton, R.A., Clark, C.A., Markus, H.S., 2010. White matter structural decline in normal ageing: a prospective longitudinal study using tract-based spatial statistics. *NeuroImage* 51, 565–577.
- Basser, P.J., Jones, D.K., 2002. Diffusion-tensor MRI: theory, experimental design and data analysis – a technical review. *NMR in Biomedicine* 15, 456–467.
- Basser, P.J., Pierpaoli, C., 1996. Microstructural and physiological features of tissues elucidated by quantitative-diffusion-tensor MRI. *Journal of Magnetic Resonance. Series B* 111, 209–219.
- Beaulieu, C., 2002. The basis of anisotropic water diffusion in the nervous system – a technical review. *NMR in Biomedicine* 15, 435–455.
- Ben Bashat, D., 2011. Abnormal developmental trajectories of white matter in autism: the contribution of MRI. In: *InTech (Ed.), Autism – A Neurodevelopmental Journey from Genes to Behavior*.
- Ben Bashat, D., Kronfeld-Duenias, V., Zachor, D.A., Ekstein, P.M., Hender, T., Tarrasch, R., Even, A., Levy, Y., Ben Sira, L., 2007. Accelerated maturation of white matter in young children with autism: a high b value DWI study. *NeuroImage* 37, 40–47.
- Bennetto, L., Pennington, B.F., Rogers, S.J., 1996. Intact and impaired memory functions in autism. *Child Development* 67, 1816–1835.
- Bloemen, O.J., Deeley, Q., Sundram, F., Daly, E.M., Barker, G.J., Jones, D.K., van Amelsvoort, T.A., Schmitz, N., Robertson, D., Murphy, K.C., Murphy, D.G., 2010. White matter integrity in Asperger syndrome: a preliminary diffusion tensor magnetic resonance imaging study in adults. *Autism Research* 3, 203–213.
- Brito, A.R., Vasconcelos, M.M., Domingues, R.C., Hygino da Cruz Jr., L.C., Rodrigues Lde, S., Gasparetto, E.L., Calcada, C.A., 2009. Diffusion tensor imaging findings in school-aged autistic children. *Journal of Neuroimaging* 19, 337–343.
- Catani, M., Howard, R.J., Pajevic, S., Jones, D.K., 2002. Virtual in vivo interactive dissection of white matter fasciculi in the human brain. *NeuroImage* 17, 77–94.
- Catani, M., Jones, D.K., Donato, R., Pfyfche, D.H., 2003. Occipito-temporal connections in the human brain. *Brain* 126, 2093–2107.
- Catani, M., Jones, D.K., Daly, E., Embiricos, N., Deeley, Q., Pugliese, L., Curran, S., Robertson, D., Murphy, D.G.M., 2008. Altered cerebellar feedback projections in Asperger syndrome. *NeuroImage* 41, 1184–1191.
- CDC, 2012. Prevalence of Autism Spectrum Disorders - Autism and Developmental Disabilities Monitoring Network, 14 sites, United States, 2008. *Morbidity and Mortality Weekly Report (MMWR)* 61, 1–19.
- Cheng, Y., Chou, K.H., Chen, I.Y., Fan, Y.T., Decety, J., Lin, C.P., 2010. Atypical development of white matter microstructure in adolescents with Autism Spectrum Disorders. *NeuroImage* 50, 873–882.
- Cheung, C., Chua, S.E., Cheung, V., Khong, P.L., Tai, K.S., Wong, T.K., Ho, T.P., McAlonan, G.M., 2009. White matter fractional anisotropy differences and correlates of diagnostic symptoms in autism. *Journal of Child Psychology and Psychiatry* 50, 1102–1112.
- Chomiak, T., Karnik, V., Block, E., Hu, B., 2010. Altering the trajectory of early postnatal cortical development can lead to structural and behavioural features of autism. *BMC Neuroscience* 11, 102.
- Conturo, T.E., Williams, D.L., Smith, C.D., Gultepe, E., Akbudak, E., Minshew, N.J., 2008. Neuronal fiber pathway abnormalities in autism: an initial MRI diffusion tensor tracking study of hippocampo-fusiform and amygdalo-fusiform pathways. *Journal of the International Neuropsychological Society* 14, 933–946.
- Courchesne, E., Karns, C.M., Davis, H.R., Ziccardi, R., Carper, R.A., Tigue, Z.D., Chisum, H.J., Moses, P., Pierce, K., Lord, C., Lincoln, A.J., Pizzo, S., Schreibman, L., Haas, R.H., Akshoomoff, N.A., Courchesne, R.Y., 2001. Unusual brain growth patterns in early life in patients with autistic disorder: an MRI study. *Neurology* 57, 245–254.
- Courchesne, E., Carper, R., Akshoomoff, N., 2003. Evidence of brain overgrowth in the first year of life in autism. *Journal of the American Medical Association* 290, 337–344.
- Frazier, T.W., Keshavan, M.S., Minshew, N.J., Hardan, A.Y., 2012. A two-year longitudinal MRI Study of the corpus callosum in autism. *Journal of Autism and Developmental Disorders* Feb 18 (Epub ahead of print) PMID: 22350341.
- Gao, W., Lin, W., Chen, Y., Gerig, G., Smith, J.K., Jewells, V., Gilmore, J.H., 2009. Temporal and spatial development of axonal maturation and myelination of white matter in the developing brain. *AJNR. American Journal of Neuroradiology* 30, 290–296.
- Gogtay, N., Giedd, J.N., Lusk, L., Hayashi, K.M., Greenstein, D., Vaituzis, A.C., Nugent III, T.F., Herman, D.H., Clasen, L.S., Toga, A.W., Rapoport, J.L., Thompson, P.M., 2004. Dynamic mapping of human cortical development during childhood through early adulthood. *Proceedings of the National Academy of Sciences of the United States of America* 101, 8174–8179.
- Golarai, G., Ghahremani, D.G., Whitfield-Gabrieli, S., Reiss, A., Eberhardt, J.L., Gabrieli, J.D., Grill-Spector, K., 2007. Differential development of high-level visual cortex correlates with category-specific recognition memory. *Nature Neuroscience* 10, 512–522.
- Griffith, E.M., Pennington, B.F., Wehner, E.A., Rogers, S.J., 1999. Executive functions in young children with autism. *Child Development* 70, 817–832.
- Groen, W.B., Buitelaar, J.K., van der Gaag, R.J., Zwiers, M.P., 2010. Pervasive microstructural abnormalities in autism: a DTI study. *Journal of Psychiatry & Neuroscience* 36, 32–40.
- Hazlett, H.C., Poe, M.D., Gerig, G., Styner, M., Chappell, C., Smith, R.G., Vachet, C., Piven, J., 2011. Early brain overgrowth in autism associated with an increase in cortical surface area before age 2 years. *Archives of General Psychiatry* 68, 467–476.
- Herbert, M.R., Ziegler, D.A., Makris, N., Filipek, P.A., Kemper, T.L., Normandin, J.J., Sanders, H.A., Kennedy, D.N., Caviness Jr., V.S., 2004. Localization of white matter volume increase in autism and developmental language disorder. *Annals of Neurology* 55, 530–540.
- Hermoye, L., Saint-Martin, C., Cosnard, G., Lee, S.-K., Kim, J., Nassogne, M.-C., Menten, R., Clapuyt, P., Donohue, P.K., Hua, K., Wakana, S., Jiang, H., van Zijl, P.C.M., Mori, S., 2006. Pediatric diffusion tensor imaging: normal database and observation of the white matter maturation in early childhood. *NeuroImage* 29, 493–504.
- Howlin, P., Goode, S., Hutton, J., Rutter, M., 2004. Adult outcome for children with autism. *Journal of Child Psychology and Psychiatry* 45, 212–229.
- Hughes, C., Russell, J., 1993. Autistic children's difficulty with mental disengagement from an object: its implications for theories of autism. *Developmental Psychology* 29, 498–510.
- Hughes, C., Russell, J., Robbins, T.W., 1994. Evidence for executive dysfunction in autism. *Neuropsychologia* 32, 477–492.
- Jones, D.K., 2010. Challenges and limitations of quantifying brain connectivity in vivo with diffusion MRI. *Imaging in Medicine* 2, 341–355.
- Jones, D.K., Symms, M.R., Cercignani, M., Howard, R.J., 2005. The effect of filter size on VBM analyses of DT-MRI data. *NeuroImage* 26, 546–554.
- Jou, R.J., Jackowski, A.P., Papademetris, X., Rajeevan, N., Staib, L.H., Volkmar, F.R., 2010. Diffusion tensor imaging in Autism Spectrum Disorders: preliminary evidence of abnormal neural connectivity. *The Australian and New Zealand Journal of Psychiatry* 45, 153–162.
- Jou, R.J., Mateljevic, N., Kaiser, M.D., Sugrue, D.R., Volkmar, F.R., Pelphrey, K.A., 2011. Structural neural phenotype of autism: preliminary evidence from a diffusion tensor imaging study using tract-based spatial statistics. *AJNR. American Journal of Neuroradiology* 32, 1607–1613.

- Just, M.A., Cherkassky, V.L., Keller, T.A., Kana, R.K., Minshew, N.J., 2007. Functional and anatomical cortical underconnectivity in autism: evidence from an fMRI study of an executive function task and corpus callosum morphometry. *Cerebral Cortex* 17, 951–961.
- Ke, X., Tang, T., Hong, S., Hang, Y., Zou, B., Li, H., Zhou, Z., Ruan, Z., Lu, Z., Tao, G., Liu, Y., 2009. White matter impairments in autism, evidence from Voxel-Based Morphometry and diffusion tensor imaging. *Brain Research* 1265, 171–177.
- Keller, T.A., Kana, R.K., Just, M.A., 2007. A developmental study of the structural integrity of white matter in autism. *Neuroreport* 18, 23–27.
- Kleinmans, N.M., Richards, T., Sterling, L., Stegbauer, K.C., Mahurin, R., Johnson, L.C., Greenson, J., Dawson, G., Aylward, E., 2008. Abnormal functional connectivity in Autism Spectrum Disorders during face processing. *Brain* 131, 1000–1012.
- Knaus, T.A., Silver, A.M., Kennedy, M., Lindgren, K.A., Dominick, K.C., Siegel, J., Tager-Flusberg, H., 2009. Language laterality in autism spectrum disorder and typical controls: a functional, volumetric, and diffusion tensor MRI study. *Brain and Language* 112, 113–120.
- Konrad, A., Dielentheis, T.F., El Masri, D., Bayerl, M., Fehr, C., Gesierich, T., Vucurevic, G., Stoeter, P., Winterer, G., 2010. Disturbed structural connectivity is related to inattention and impulsivity in adult attention deficit hyperactivity disorder. *The European Journal of Neuroscience* 31, 912–919.
- Kumar, A., Sundaram, S.K., Sivaswamy, L., Behen, M.E., Makki, M.I., Ager, J., Janisse, J., Chugani, H.T., Chugani, D.C., 2010. Alterations in frontal lobe tracts and corpus callosum in young children with autism spectrum disorder. *Cerebral Cortex* 20, 2103–2113.
- Lainhart, J.E., Piven, J., Wzorek, M., Landa, R., Santangelo, S.L., Coon, H., Folstein, S.E., 1997. Macrocephaly in children and adults with autism. *Journal of the American Academy of Child and Adolescent Psychiatry* 36, 282–290.
- Le Bihan, D., Mangin, J.F., Poupon, C., Clark, C.A., Pappata, S., Molko, N., Chabriat, H., 2001. Diffusion tensor imaging: concepts and applications. *Journal of Magnetic Resonance Imaging* 13, 534–546.
- Lebel, C., Walker, L., Leemans, A., Phillips, L., Beaulieu, C., 2008. Microstructural maturation of the human brain from childhood to adulthood. *NeuroImage* 40, 1044–1055.
- Lee, J.E., Bigler, E.D., Alexander, A.L., Lazar, M., DuBray, M.B., Chung, M.K., Johnson, M., Morgan, J., Miller, J.N., McMahon, W.M., Lu, J., Jeong, E.K., Lainhart, J.E., 2007. Diffusion tensor imaging of white matter in the superior temporal gyrus and temporal stem in autism. *Neuroscience Letters* 424, 127–132.
- Levy, Y., Ben Bashat, D., Ben Sira, L., Hendler, T., Ben Itzhak, E., Kronfeld-Duenias, V., Zachor, D., 2010. Abnormal White Matter in Language-Related Brain Tracts in Non-Verbal Children with Autism: a case study of four toddlers. *International Journal of Public Health* 2, 135–144.
- Lord, C., Rutter, M., Le Couteur, A., 1994. Autism Diagnostic Interview-Revised: a revised version of a diagnostic interview for caregivers of individuals with possible pervasive developmental disorders. *Journal of Autism and Developmental Disorders* 24, 659–685.
- Lord, C., Risi, S., Lambrecht, L., Cook Jr., E.H., Leventhal, B.L., DiLavore, P.C., Pickles, A., Rutter, M., 2000. The Autism Diagnostic Observation Schedule-generic: a standard measure of social and communication deficits associated with the spectrum of autism. *Journal of Autism and Developmental Disorders* 30, 205–223.
- Luna, B., Garver, K.E., Urban, T.A., Lazar, N.A., Sweeney, J.A., 2004. Maturation of cognitive processes from late childhood to adulthood. *Child Development* 75, 1357–1372.
- Madden, D.J., Whiting, W.L., Huettel, S.A., White, L.E., MacFall, J.R., Provenzale, J.M., 2004. Diffusion tensor imaging of adult age differences in cerebral white matter: relation to response time. *NeuroImage* 21, 1174–1181.
- Mandonnet, E., Nouet, A.I., Gatignol, P., Capelle, L., Duffau, H., 2007. Does the left inferior longitudinal fasciculus play a role in language? A brain stimulation study. *Brain* 130, 623–629.
- Minshew, N.J., Meyer, J., Goldstein, G., 2002. Abstract reasoning in autism: a dissociation between concept formation and concept identification. *Neuropsychology* 16, 327–334.
- Noriuchi, M., Kikuchi, Y., Yoshiura, T., Kira, R., Shigetoh, H., Hara, T., Tobimatsu, S., Kamio, Y., 2010. Altered white matter fractional anisotropy and social impairment in children with autism spectrum disorder. *Brain Research* 1362, 141–149.
- Ozonoff, S., Jensen, J., 1999. Brief report: specific executive function profiles in three neurodevelopmental disorders. *Journal of Autism and Developmental Disorders* 29, 171–177.
- Ozonoff, S., McEvoy, R.E., 1994. A longitudinal study of executive function and theory of mind development in autism. *Development and Psychopathology* 6, 415–431.
- Ozonoff, S., Pennington, B.F., Rogers, S.J., 1991. Executive function deficits in high-functioning autistic individuals: relationship to theory of mind. *Journal of Child Psychology and Psychiatry, and Allied Disciplines* 32, 1081–1105.
- Paul, L.K., Brown, W.S., Adolphs, R., Tyszka, J.M., Richards, L.J., Mukherjee, P., Sherr, E.H., 2007. Agenesis of the corpus callosum: genetic, developmental and functional aspects of connectivity. *Nature Reviews Neuroscience* 8, 287–299.
- Pellicano, E., 2010. The development of core cognitive skills in autism: a 3-year prospective study. *Child Development* 81, 1400–1416.
- Pfefferbaum, A., Sullivan, E.V., 2003. Increased brain white matter diffusivity in normal adult aging: relationship to anisotropy and partial voluming. *Magnetic Resonance in Medicine* 49, 953–961.
- Philippi, C.L., Mehta, S., Grabowski, T., Adolphs, R., Rudrauf, D., 2009. Damage to association fiber tracts impairs recognition of the facial expression of emotion. *The Journal of Neuroscience* 29, 15089–15099.
- Pierpaoli, C., Barnett, A., Pajevic, S., Chen, R., Penix, L.R., Virts, A., Basser, P., 2001. Water diffusion changes in Wallerian degeneration and their dependence on white matter architecture. *NeuroImage* 13, 1174–1185.
- Piven, J., Arndt, S., Bailey, J., Andreasen, N., 1996. Regional brain enlargement in autism: a magnetic resonance imaging study. *Journal of the American Academy of Child and Adolescent Psychiatry* 35, 530–536.
- Pugliese, L., Catani, M., Ameis, S., Dell'Acqua, F., Thiebaut de Schotten, M., Murphy, C., Robertson, D., Deeley, Q., Daly, E., Murphy, D.G., 2009. The anatomy of extended limbic pathways in Asperger syndrome: a preliminary diffusion tensor imaging tractography study. *NeuroImage* 47, 427–434.
- Redcay, E., Courchesne, E., 2005. When is the brain enlarged in autism? A meta-analysis of all brain size reports. *Biological Psychiatry* 58, 1–9.
- Rodier, P.M., 2004. Environmental causes of central nervous system maldevelopment. *Pediatrics* 113, 1076–1083.
- Rueckert, D., Sonoda, L.I., Hayes, C., Hill, D.L., Leach, M.O., Hawkes, D.J., 1999. Nonrigid registration using free-form deformations: application to breast MR images. *IEEE Transactions on Medical Imaging* 18, 712–721.
- Sahyoun, C.P., Belliveau, J.W., Mody, M., 2010a. White matter integrity and pictorial reasoning in high-functioning children with autism. *Brain and Cognition* 73, 180–188.
- Sahyoun, C.P., Belliveau, J.W., Soulieres, I., Schwartz, S., Mody, M., 2010b. Neuroimaging of the functional and structural networks underlying visuospatial vs. linguistic reasoning in high-functioning autism. *Neuropsychologia* 48, 86–95.
- Scherf, K.S., Behrmann, M., Humphreys, K., Luna, B., 2007. Visual category-selectivity for faces, places and objects emerges along different developmental trajectories. *Developmental Science* 10, F15–F30.
- Schmithorst, V.J., Yuan, W., 2010. White matter development during adolescence as shown by diffusion MRI. *Brain and Cognition* 72, 16–25.
- Schmithorst, V.J., Wilke, M., Dardzinski, B.J., Holland, S.K., 2002. Correlation of white matter diffusivity and anisotropy with age during childhood and adolescence: a cross-sectional diffusion-tensor MR imaging study. *Radiology* 222, 212–218.
- Seltzer, M.M., Krauss, M.W., Shattuck, P.T., Orsmond, G., Swe, A., Lord, C., 2003. The symptoms of Autism Spectrum Disorders in adolescence and adulthood. *Journal of Autism and Developmental Disorders* 33, 565–581.
- Shattuck, P.T., Seltzer, M.M., Greenberg, J.S., Orsmond, G.I., Bolt, D., Kring, S., Lounds, J., Lord, C., 2007. Change in autism symptoms and maladaptive behaviors in adolescents and adults with an autism spectrum disorder. *Journal of Autism and Developmental Disorders* 37, 1735–1747.
- Shukla, D.K., Keehn, B., Muller, R.A., 2011a. Tract-specific analyses of diffusion tensor imaging show widespread white matter compromise in autism spectrum disorder. *Journal of Child Psychology and Psychiatry* 52, 286–295.
- Shukla, D.K., Keehn, B., Smylie, D.M., Muller, R.A., 2011b. Microstructural abnormalities of short-distance white matter tracts in autism spectrum disorder. *Neuropsychologia* 49, 1378–1382.
- Smith, S.M., 2002. Fast robust automated brain extraction. *Human Brain Mapping* 17, 143–155.
- Smith, S.M., Nichols, T.E., 2009. Threshold-Free Cluster Enhancement: addressing problems of smoothing, threshold dependence and localisation in cluster inference. *NeuroImage* 44, 83–98.
- Smith, S.M., Jenkinson, M., Woolrich, M.W., Beckmann, C.F., Behrens, T.E., Johansen-Berg, H., Bannister, P.R., De Luca, M., Drobnjak, I., Flitney, D.E., Niazy, R.K., Saunders, J., Vickers, J., Zhang, Y., De Stefano, N., Brady, J.M., Matthews, P.M., 2004. Advances in functional and structural MR image analysis and implementation as FSL. *NeuroImage* 23 (Suppl 1), S208–S219.
- Smith, S.M., Jenkinson, M., Johansen-Berg, H., Rueckert, D., Nichols, T.E., Mackay, C.E., Watkins, K.E., Ciccarelli, O., Cader, M.Z., Matthews, P.M., Behrens, T.E.J., 2006. Tract-based spatial statistics: voxelwise analysis of multi-subject diffusion data. *NeuroImage* 31, 1487–1505.
- Snook, L., Paulson, L.-A., Roy, D., Phillips, L., Beaulieu, C., 2005. Diffusion tensor imaging of neurodevelopment in children and young adults. *NeuroImage* 26, 1164–1173.
- Sparks, B.F., Friedman, S.D., Shaw, D.W., Aylward, E.H., Echelard, D., Artru, A.A., Maravilla, K.R., Giiedd, J.N., Munson, J., Dawson, G., Dager, S.R., 2002. Brain structural abnormalities in young children with autism spectrum disorder. *Neurology* 59, 184–192.
- Sullivan, E.V., Pfefferbaum, A., 2006. Diffusion tensor imaging and aging. *Neuroscience and Biobehavioral Reviews* 30, 749–761.
- Sullivan, E.V., Adalsteinsson, E., Hedeus, M., Ju, C., Moseley, M., Lim, K.O., Pfefferbaum, A., 2001. Equivalent disruption of regional white matter microstructure in ageing healthy men and women. *Neuroreport* 12, 99–104.
- Sundaram, S.K., Kumar, A., Makki, M.I., Behen, M.E., Chugani, H.T., Chugani, D.C., 2008. Diffusion tensor imaging of frontal lobe in autism spectrum disorder. *Cerebral Cortex* 18, 2659–2665.
- Thakkar, K.N., Polli, F.E., Joseph, R.M., Tuch, D.S., Hadjikhani, N., Barton, J.J., Manoach, D.S., 2008. Response monitoring, repetitive behaviour and anterior cingulate abnormalities in Autism Spectrum Disorders (ASD). *Brain* 131, 2464–2478.
- Thomas, C., Humphreys, K., Jung, K.J., Minshew, N., Behrmann, M., 2011. The anatomy of the callosal and visual-association pathways in high-functioning autism: a DTI 753 tractography study. *Cortex* 47, 863–873.
- Travers, B.G., Adluru, N., Ennis, C., Tromp, D.P., Destiche, D., Doran, S., Bigler, E.D., Lange, N., Lainhart, J.E., Alexander, A.L., 2012. Diffusion tensor imaging in autism spectrum disorder: a review. *Autism Research*. <http://dx.doi.org/10.1002/aur.1243> (Epub ahead of print) PMID: 22786754.
- van den Heuvel, M., Mandl, R., Luigjes, J., Hulshoff Pol, H., 2008. Microstructural organization of the cingulum tract and the level of default mode functional connectivity. *The Journal of Neuroscience* 28, 10844–10851.
- Vestergaard, M., Madsen, K.S., Baare, W.F., Skimminge, A., Ejersbo, L.R., Ramsøy, T.Z., Gerlach, C., Akeson, P., Paulson, O.B., Jernigan, T.L., 2011. White matter microstructure in superior longitudinal fasciculus associated with spatial working memory performance in children. *Journal of Cognitive Neuroscience* 23, 2135–2146.

- Waiter, G.D., Williams, J.H.G., Murray, A.D., Gilchrist, A., Perrett, D.I., Whiten, A., 2005. Structural white matter deficits in high-functioning individuals with autistic spectrum disorder: a voxel-based investigation. *NeuroImage* 24, 455–461.
- Wakana, S., Jiang, H., Nagae-Poetscher, L.M., van Zijl, P.C.M., Mori, S., 2004. Fiber tract-based atlas of human white matter anatomy. *Radiology* 230, 77–87.
- Wechsler, D., 1997. Wechsler Memory Scale, third ed. The Psychological Corporation, San Antonio, TX.
- Wechsler, D., Naglieri, J., 2006. Wechsler nonverbal scale of ability. PsychCorp Edition, A Brand of Harcourt Assessment, Pearson, San Antonio, TX.
- Weinstein, M., Ben-Sira, L., Levy, Y., Zachor, D.A., Itzhak, E.B., Artzi, M., Tarrasch, R., Eksteine, P.M., Hendler, T., Bashat, D.B., 2011. Abnormal white matter integrity in young children with autism. *Human Brain Mapping* 32, 534–543.
- Woodbury-Smith, M.R., Robinson, J., Wheelwright, S., Baron-Cohen, S., 2005. Screening adults for Asperger syndrome using the AQ: a preliminary study of its diagnostic validity in clinical practice. *Journal of Autism and Developmental Disorders* 35, 331–335.
- Woolrich, M.W., Jbabdi, S., Patenaude, B., Chappell, M., Makni, S., Behrens, T., Beckmann, C., Jenkinson, M., Smith, S.M., 2009. Bayesian analysis of neuroimaging data in FSL. *NeuroImage* 45, S173–S186.