



# High-dose-rate Interstitial Brachytherapy Boost with a Pedicled Latissimus Dorsi Myocutaneous Flap for Myxofibrosarcoma of the Arm

## Citation

Lane, Jordan D., Bohdan Pomahac, Chandrajit P. Raut, Elizabeth H. Baldini, and Phillip M. Devlin. 2014. "High-dose-rate Interstitial Brachytherapy Boost with a Pedicled Latissimus Dorsi Myocutaneous Flap for Myxofibrosarcoma of the Arm." *Plastic and Reconstructive Surgery Global Open* 2 (10): e229. doi:10.1097/GOX.000000000000188. <http://dx.doi.org/10.1097/GOX.000000000000188>.

## Published Version

doi:10.1097/GOX.000000000000188

## Permanent link

<http://nrs.harvard.edu/urn-3:HUL.InstRepos:13454790>

## Terms of Use

This article was downloaded from Harvard University's DASH repository, and is made available under the terms and conditions applicable to Other Posted Material, as set forth at <http://nrs.harvard.edu/urn-3:HUL.InstRepos:dash.current.terms-of-use#LAA>

## Share Your Story

The Harvard community has made this article openly available.  
Please share how this access benefits you. [Submit a story](#).

[Accessibility](#)

# High-dose-rate Interstitial Brachytherapy Boost with a Pedicled Latissimus Dorsi Myocutaneous Flap for Myxofibrosarcoma of the Arm

Jordan D. Lane, BS\*  
 Bohdan Pomahac, MD\*†  
 Chandrajit P. Raut, MD,  
 MSc\*‡§  
 Elizabeth H. Baldini, MD,  
 MPH\*§||  
 Phillip M. Devlin, MD, FACP,  
 FASTRO\*§||

**Summary:** A 71-year-old man was found to have a 7.4×2.9×7.0 cm myxofibrosarcoma of the right medial arm close to neurovascular structures. He received 50 Gray (Gy) of preoperative external beam radiation. Radical resection resulted in a 15×10 cm defect. Nine brachytherapy catheters were placed, and a pedicled latissimus dorsi myocutaneous flap was used in reconstruction. Final pathology confirmed myxofibrosarcoma, high grade. The tumor was <1 mm from 2 margins. A total of 17.5 Gy of brachytherapy was delivered to the surgical bed from postoperative days 7 to 9. The flap developed fat necrosis distally which eventually required surgical debridement on postoperative day 58. It subsequently healed well and maintained good function of the limb. The patient remains under surveillance without evidence of recurrence. (*Plast Reconstr Surg Glob Open* 2014; 2: e229; doi: 10.1097/GOX.000000000000188; Published online 9 October 2014).

It can be difficult to obtain sufficient margins for extremity soft tissue sarcomas (ESTS) in proximity to important structures even when preoperative external beam radiation therapy (EBRT) is used. Postoperative brachytherapy can be added in an attempt to decrease the risk of local recurrence. High-dose-rate brachytherapy using computer optimized treatment planning provides a uniform dose to the target and very low doses to nearby radiosensitive tissues.

Rates of major wound complications following preoperative EBRT range from 19% to 52% for patients with ESTS who receive a vascularized flap.<sup>1-3</sup> It is possible that adding postoperative brachytherapy might make this rate higher. However, the desire to prevent recurrence and retain a functional limb may justify this risk.

## METHODS

A 71-year-old man presented to his primary care physician with a nontender subcutaneous mass of the right medial arm. Magnetic resonance imaging (MRI) showed a 7.4×2.9×7.0 cm mass which abutted the biceps muscle, brachial artery, and median nerve. Incisional biopsy demonstrated myxofibrosarcoma, intermediate grade. Chest computed tomography scan showed no evidence of metastatic disease. He was staged as G2T2aN0M0, stage IIB.

### External Beam Radiation

Due to the high propensity for myxofibrosarcoma to recur locally<sup>4</sup> and the lesion's proximity to neurovascular structures, preoperative EBRT was offered. A dose of 50 Gy in 2 Gy daily fractions was given over

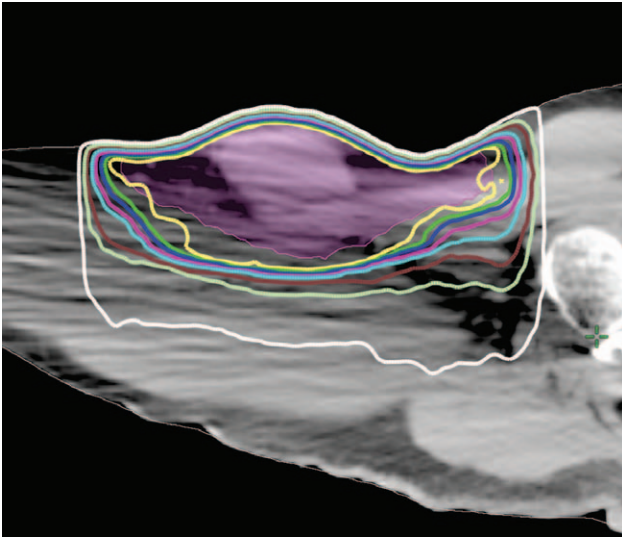
From the \*Harvard Medical School, Boston, Mass.; †Division of Plastic Surgery and ‡Department of Surgery, Brigham and Women's Hospital, Boston, Mass.; §Center for Sarcoma and Bone Oncology, Dana-Farber Cancer Institute, Boston, Mass.; and ||Department of Radiation Oncology, Brigham and Women's Hospital, Boston, Mass.

Received for publication April 30, 2014; accepted July 29, 2014.

Copyright © 2014 The Authors. Published by Lippincott Williams & Wilkins on behalf of The American Society of Plastic Surgeons. PRS Global Open is a publication of the American Society of Plastic Surgeons. This is an open-access article distributed under the terms of the Creative Commons Attribution-NonCommercial-NoDerivatives 3.0 License, where it is permissible to download and share the work provided it is properly cited. The work cannot be changed in any way or used commercially.

DOI: 10.1097/GOX.000000000000188

**Disclosure:** The authors have no financial interest to declare in relation to the content of this article. The Article Processing Charge was paid for by the authors.

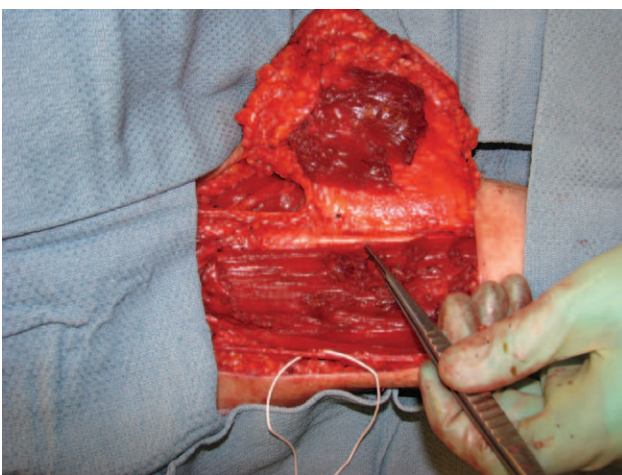


**Fig. 1.** External beam radiation dose distribution.

5 weeks (Fig. 1). The only side effects were mild, in-field skin erythema, and ipsilateral axillary alopecia.

**Surgical Resection**

Five weeks after completion of EBRT, the patient underwent radical resection of the right arm mass. A 2-cm margin of skin was encompassed beyond radiographic extent of the tumor based on MRI and extended circumferentially 1–2 cm into subcutaneous tissue. A portion of the superficial biceps muscle was excised as part of the deep margin. The brachial artery and basilic vein were spared. The closest margin was the medial aspect of the deep margin over the spared median, medial antebrachial cutaneous, and ulnar nerves. There was no macroscopic involvement of any of the margins. The postresection defect measured 15 × 10 cm (Fig. 2).



**Fig. 2.** Intraoperative photography demonstrates the tumor reflected en bloc exposing the brachial artery (forceps), partially resected biceps muscle, and basilic vein (loop).

**Brachytherapy Catheter Placement**

Intraoperative frozen sections suggested that the median nerve margin was <2 mm. Nine 6F brachytherapy catheters were serially introduced through the skin with blunt trocars from an inferior lateral approach (Fig. 3). They were fixed to the tumor bed with chromic gut interrupted suture. The external portions were secured to the skin using buttons, spacers, and interrupted 3-0 nylon suture. They were gathered together with a Penrose drain (Cardinal Health, Dublin, OH) and covered with Xeroform gauze (Covidien, Mansfield, MA).

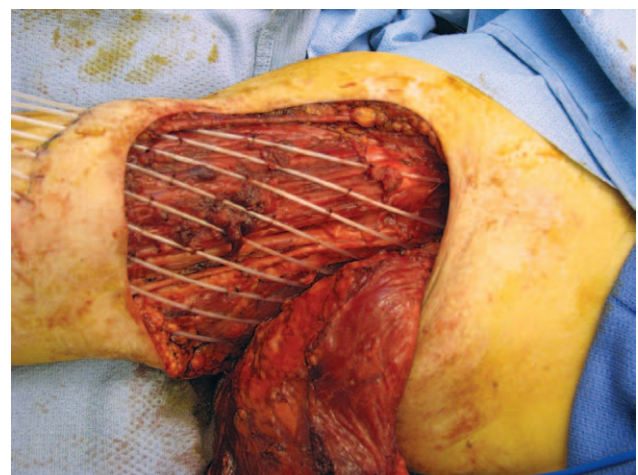
**Reconstruction**

A latissimus dorsi myocutaneous flap was designed intraoperatively to fill the defect and cover the exposed neurovascular structures while preserving motion of the extremity. The flap was elevated and tunneled through the axilla. Two 15F Blake drains were placed at the donor site which was primarily closed. The patient was then repositioned for reconstruction of the defect.

The recipient site was undermined laterally and posteriorly to accommodate redundant bulk of the muscle in the flap. A 0.5-in Penrose drain was placed under the flap via the axilla. The skin island was trimmed distally to accommodate the insertion of the flap, and the recipient site was closed in layered fashion with interrupted then running 3-0 Monocryl (Ethicon, Somerville, NJ). The flap was pink and viable leaving the operating room.

**Pathology**

The tumor measured 5.5 × 4.0 × 2.0 cm. Microscopic analysis confirmed myxofibrosarcoma, high grade. The tumor invaded beyond the fascia and was



**Fig. 3.** Brachytherapy catheters on the tumor bed. Nine catheters were inserted through the skin inferior to the defect and secured to the tumor bed and skin before flap placement.

<1 mm from the deep/posterior margin. The tumor was also <1 mm from the median nerve margin but bounded by fascia. The lateral margin was 2.1 cm, inferior margin 0.6 cm, and proximal margin 2.1 cm.

Five days postoperatively, the case was presented at multidisciplinary sarcoma pathology conference, where brachytherapy boost was recommended.

### Brachytherapy

A complex computed tomography target plan was designed to deliver a total of 17.5 Gy in fractions of 3.5 Gy to the surgical bed with a 2-cm peripheral margin and a depth of 5 mm (Fig. 4). Including preoperative EBRT, this represented a total radiobiologically equivalent dose of 70 Gy. Brachytherapy was delivered in 5 mm steps using a Nucletron HDR MicroSelectron Apparatus (Elektra, Norcross, GA) twice a day from postoperative days 7 to 9.

### Wound Management

At discharge, the distal portion of the flap was slightly dusky. Hyperbaric oxygen was prescribed, but delayed and interrupted. One month following resection, the flap developed erythema around the edge and a draining area of fat necrosis undermined the distal, dusky area. This was managed conservatively, but eventually required surgical debridement on postoperative day 58. A 5 × 2 × 2 cm area of the distal flap was debrided, and a vacuum-assisted closure was placed. Hyperbaric oxygen treatments con-

tinued, totaling 20, and the vacuum-assisted closure was removed after 27 days with great improvement. The wound subsequently healed (Fig. 5).

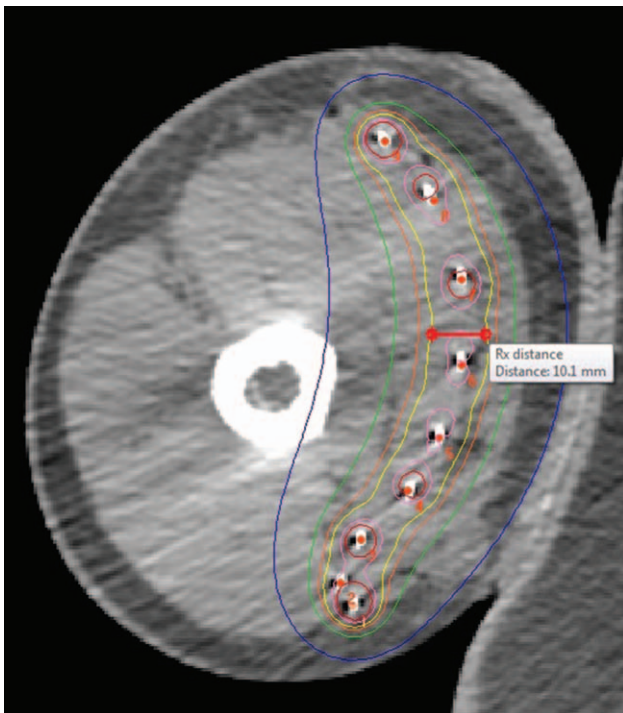
The patient is currently under surveillance.

## DISCUSSION

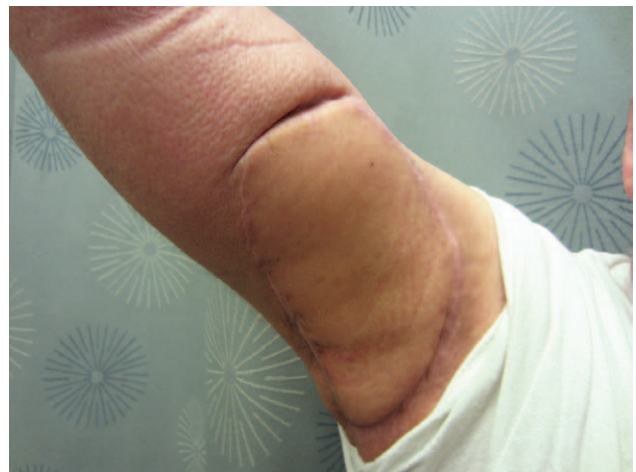The chance of a major wound complication was high for this patient. However, preoperative EBRT with postoperative brachytherapy was thought to provide the best chance of local control and functional limb preservation in this high-risk situation. Poor healing required return to the operating room, but the flap remained viable. There are only a few reports in the literature describing patients treated with EBRT, surgical resection, primary reconstructive flap closure, and boost brachytherapy for primary treatment of ESTS.<sup>1,5</sup> Although these cases demonstrate that reconstruction can be successful with acceptable complications, the risks and benefits are not certain. A multi-institution registry may be warranted to better track outcomes because the low number of like patients limits possible studies.

## CONCLUSIONS

This report describes a 71-year-old man with a high-grade myxofibrosarcoma of the upper arm abutting neurovascular structures who was treated with 50 Gy of preoperative EBRT, radical resection, a primary latissimus dorsi flap, and 17.5 Gy boost of HDR brachytherapy. The postoperative course was complicated by partial flap necrosis requiring operative debridement; however, the flap remained viable, and he retained excellent function of the arm. An MRI at 3 months postresection showed no evidence of local recurrence. This case demonstrates that even with the use of preoperative radiation and



**Fig. 4.** Highly conformal brachytherapy dose distribution. Yellow indicates the 100% isodose line.



**Fig. 5.** Follow-up photography at 5 months after resection demonstrates excellent healing, range of motion, and no evidence of recurrence.

boost brachytherapy, a vascular flap can remain viable, allowing for limb salvage with good function. We feel the potential morbidities of this technique are justified for patients at very high risk for local recurrence and potential subsequent loss of limb.

**Phillip M. Devlin, MD, FACR, FASTRO**

Division of Brachytherapy  
Brigham and Women's Hospital  
75 Francis Street, Boston  
MA 02115  
E-mail: pdevlin@lroc.harvard.edu

#### REFERENCES

1. Baldini EH, Lapidus MR, Wang Q, et al. Predictors for major wound complications following preoperative radiotherapy and surgery for soft-tissue sarcoma of the extremities and trunk: importance of tumor proximity to skin surface. *Ann Surg Oncol*. 2013;20:1494–1499.
2. Barwick WJ, Goldberg JA, Scully SP, et al. Vascularized tissue transfer for closure of irradiated wounds after soft tissue sarcoma resection. *Ann Surg*. 1992;216:591–595.
3. O'Sullivan B, Davis AM, Turcotte R, et al. Preoperative versus postoperative radiotherapy in soft-tissue sarcoma of the limbs: a randomised trial. *Lancet*. 2002;359:2235–2241.
4. Haglund KE, Raut CP, Nascimento AF, et al. Recurrence patterns and survival for patients with intermediate- and high-grade myxofibrosarcoma. *Int J Radiat Oncol Biol Phys*. 2012;82:361–367.
5. Papagelopoulos PJ, Mavrogenis AF, Mastorakos DP, et al. Free vascularised tissue transfer and brachytherapy for soft-tissue sarcomas of the extremities. *Injury*. 2008;39 Suppl 3:S83–S89.