



Bilateral Simultaneous Anterior Cruciate Ligament Injury: A Case Report and National Survey of Orthopedic Surgeon Management Preference

Citation

Saadat, Ehsan, Emily J. Curry, Xinning Li, and Elizabeth G. Matzkin. 2014. "Bilateral Simultaneous Anterior Cruciate Ligament Injury: A Case Report and National Survey of Orthopedic Surgeon Management Preference." *Orthopedic Reviews* 6 (4): 5551. doi:10.4081/or.2014.5551. <http://dx.doi.org/10.4081/or.2014.5551>.

Published Version

doi:10.4081/or.2014.5551

Permanent link

<http://nrs.harvard.edu/urn-3:HUL.InstRepos:13890773>

Terms of Use

This article was downloaded from Harvard University's DASH repository, and is made available under the terms and conditions applicable to Other Posted Material, as set forth at <http://nrs.harvard.edu/urn-3:HUL.InstRepos:dash.current.terms-of-use#LAA>

Share Your Story

The Harvard community has made this article openly available.
Please share how this access benefits you. [Submit a story](#).

[Accessibility](#)

Bilateral simultaneous anterior cruciate ligament injury: a case report and national survey of orthopedic surgeon management preference

Ehsan Saadat,^{1,2} Emily J. Curry,²
Xinning Li,³ Elizabeth G. Matzkin²

¹Harvard Combined Orthopedic Residency Program, Boston; ²Department of Orthopedic Surgery, Brigham and Women's Hospital, Boston; ³Boston University School of Medicine, MA, USA

Abstract

Unilateral anterior cruciate ligament (ACL) tear is a common injury seen by sports medicine orthopedic surgeons. However, a bilateral simultaneous ACL injury is extremely rare and has been reported only three times in the literature. We present a young female skier with simultaneous bilateral ACL tears that were managed with staged ACL reconstruction. We then conducted a nationwide survey (United States) to determine the prevalence of simultaneous bilateral ACL tear and preferred management strategies by sports medicine orthopedic surgeons. Sports medicine fellowship directors were contacted and asked to send an 8-item survey to colleagues (sports medicine fellowship trained surgeons) asking about overall number of ACL reconstructions performed, number of bilateral simultaneous ACL injuries seen and optimal management strategies of such an injury. Out of 43 responses, only 22 (51.2%) surgeons had seen a bilateral simultaneous ACL injury. Of these, 16 (76.2%) preferred staged reconstruction. Graft choice was mixed between autograft and allograft, but a large majority preferred either patellar tendon autograft (58%) or hamstring autograft (41%) were the most common choice. Staged reconstruction is the treatment of choice by surgeons surveyed in our study.

Introduction

Approximately 100,000 ACL injuries are documented in the United States annually;¹ however, only three bilateral simultaneous ACL injuries have been reported in the literature as case reports.²⁻⁴ This particular injury lacks defined guidelines for optimal management. While both staged and simultaneous ACL reconstructions are considered appropriate strategies for the management of bilateral ACL

injuries,⁵⁻⁸ no study has been conducted to compare the outcome of these two-treatment options. Furthermore, the follow-up in the three cases published in the literature is short.²⁻⁴ We present a case of bilateral simultaneous ACL rupture in a 23-year-old skier with two and half year follow-up. In addition, we performed a national survey of orthopedic surgery sports medicine fellowship program directors (United States) on their experience or preference in the management of patients when faced with a simultaneous bilateral ACL injury.

Case Report

Our patient is a healthy 23-year-old woman who sustained bilateral knee injuries with a fall while skiing. She reported hearing a pop in both knees and was unable to bear weight on her left lower extremity. The right lower extremity was not immediately bothersome and was only painful with pivoting motions. She was initially evaluated by an emergency medicine physician, given ice, anti-inflammatories and crutches, and referred to our center for further management.

Physical examination of the left knee revealed a large effusion and range of motion of 10-70° degrees, 2B Lachman and 2+ laxity with valgus stress at 30 degrees. Posterior drawer, varus stress and dial test was negative. Plain radiographs revealed an avulsion fracture of the left fibular styloid process and a calcified fragment proximal to the fibular styloid process.

Physical examination of the right knee revealed a significant effusion and range of motion of 10-90°, lateral joint line tenderness to palpation, 2B Lachman and 2+ laxity with valgus stress. Posterior drawer, varus stress and dial test was negative. Right knee radiographs were unremarkable except for evidence of a large effusion. Bilateral lower extremities were neurovascularly intact.

Bilateral knee MRI's were obtained, revealing complete mid-substance ACL ruptures, partial thickness radial tear of the posterior horn of the lateral menisci, MCL sprain, subchondral fractures of the lateral femoral condyles, and interstitial tears of the proximal gastrocnemius muscle bilaterally. In addition, the left knee MRI showed a non-displaced fibular head fracture. After extensive discussion, our patient elected for a staged ACL reconstructions with tibialis anterior allograft two months apart. The decision to proceed with staged reconstructions was a mutual agreement between surgeon and patient. Reconstruction of the left ACL was performed approximately one week after initial injury, and the right ACL was reconstructed 8 weeks

Correspondence: Xinning Li, Division of Sports Medicine and Shoulder Surgery, Boston University School of Medicine, 720 Harrison Ave. Suite 808, Boston, MA 02118, USA.
E-mail: xinning.li@gmail.com

Key words: anterior cruciate ligament; sports medicine; bilateral anterior cruciate ligament injury.

Contributions: the authors contributed equally.

Conflict of interests: the authors declare no potential conflict of interests.

Received for publication: 15 July 2014.
Revision received: 30 September 2014.
Accepted for publication: 4 October 2014.

This work is licensed under a Creative Commons Attribution NonCommercial 3.0 License (CC BY-NC 3.0).

©Copyright E. Saadat et al., 2014
Licensee PAGEPress, Italy
Orthopedic Reviews 2014; 6:5551
doi:10.4081/or.2014.5551

post-injury. Postoperative recovery from the left ACL reconstruction was unremarkable. Our patient returned to the elliptical and bicycle approximately 7 months post left ACL reconstruction. The left knee has continued to do well at last follow-up. Postoperative recovery from the right ACL reconstruction was complicated by a 10° flexion contracture and pain with ambulation and tenderness over the tibial tunnel at 5 months. MRI demonstrated a small Cyclops lesion. The patient was taken back to the operating room for right knee manipulation under anesthesia, arthroscopy with debridement of a small Cyclops lesion within the notch. At 2 months post-right knee debridement she was doing very well with 0-130° range of motion; she returned to skiing 8 months postoperatively. Our patient continues to do well 2.5 years after bilateral ACL reconstructions and is back to skiing. Our patient gave permission for publication of her case report.

National survey of orthopedic surgeon preferences in treatment of simultaneous bilateral anterior cruciate ligament ruptures

Survey methods

In order to determine the prevalence of simultaneous bilateral ACL ruptures, along with preferred management strategies for

these patients, a national survey of sports medicine orthopedic surgeons in the United States was conducted. All sports medicine fellowship directors in the United States were contacted via e-mail and were asked to distribute an 8-item survey (Table 1) to sports medicine-trained orthopedic surgeons within their departments. One reminder e-mail was sent requesting survey completion two weeks after the initial e-mail. Our local Institutional Review Board deemed this research study exempt from review.

Survey results

One hundred and seven surgeons were successfully contacted. Of these, 43 responded, yielding a response rate of 40.2%. The senior author was excluded from the survey results. The average year-in-practice for study respondents was 18 years (SD: 10.4; Range: 0.5-40). Twenty-two (51.2%) surgeons had not cared for a patient with simultaneous ACL ruptures and were only asked how they would manage a patient of this kind if presented with a case. Of the remainder, 8 (18.6%) had cared for one, 6 (14.0%) had cared for two, and 7 surgeons (16.3%) had cared for three or more patients with bilateral simultaneous ACL ruptures (Figure 1). Surgeons that had not seen a simultaneous ACL rupture were in practice for an average of 16.3 years (SD: 10.1), while surgeons that had seen a simultaneous ACL rupture were in practice for an average of 19.0 years (SD: 10.4). Of those who had treated one or more patients with a bilateral simultaneous ACL injury, 16 (76.2%) preferred a staged procedure. Of those who had not treated any patients with this injury, 20 (90.1%) preferred a staged reconstruction. While sex did not affect the decision of staged *vs.* simultaneous reconstruction, 8 (38.1%) of respondents who

had cared for a simultaneous bilateral injury reported that age did affect the decision to pursue a simultaneous versus a staged repair. Of those who had treated one or more patients with a bilateral simultaneous ACL injury, graft choice varied considerably when offered a choice between staged versus simultaneous reconstructions (Figure 2). Of those that preferred performing a simultaneous reconstruction, 3 (60%) surgeons preferred a hamstring autograft, 1 (20%) preferred bone-patellar tendon-bone autograft, and 1 (20%) preferred an allograft (not otherwise specified). Of those

that preferred a staged reconstruction, 10 (62.5%) preferred a bone-patellar tendon-bone autograft, and 6 (37.5%) preferred a hamstring autograft.

Discussion and Conclusions

Despite the otherwise abundant literature regarding the management of ACL injuries and the optimal reconstructive technique, very little information exists regarding the optimal

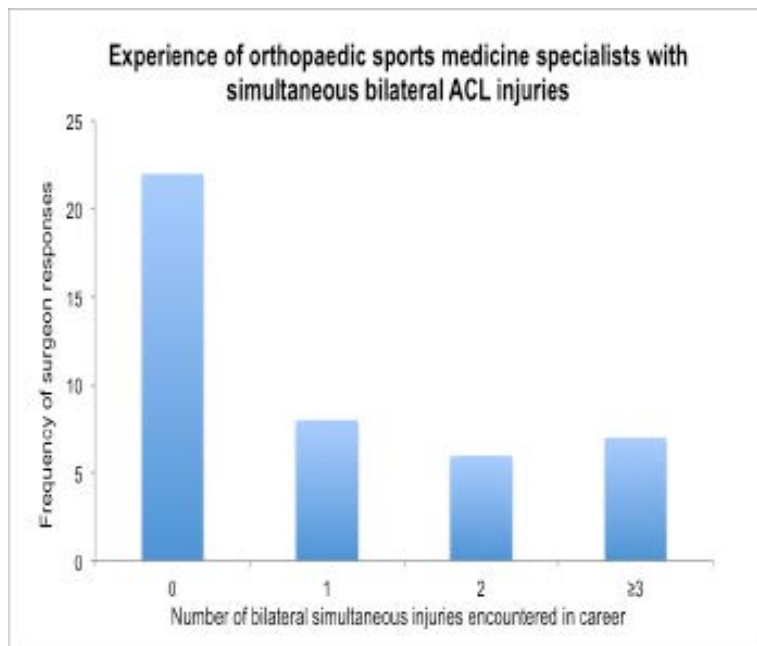


Figure 1. Experience of orthopedic sports medicine specialists with simultaneous bilateral anterior cruciate ligament injuries.

Table 1. Questions asked within 8-item survey depending upon bilateral simultaneous anterior cruciate ligament injury experience.

Questions	Answers
Number of years in practice	Numeric value response
Number of ACL reconstructions performed annually	Numeric value response
The number of bilateral simultaneous ACL tears you have seen in your career	0, 1, 2, 3, 4, 5, more than 5
When (if for response 0 in #3) presented with a patient with bilateral simultaneous ACL tears, what is your reconstruction preference?	Simultaneous; Staged reconstruction
Do you think that simultaneously repairing bilateral ACL tears has an effect on the time needed for rehabilitation?*	Increases rehabilitation time; Decreases rehabilitation time; Same amount of time required regardless of repair choice
Does sex affect your decision to perform a simultaneous versus staged reconstruction?*	Yes; No
Does age affect your decision to perform a simultaneous versus staged reconstruction?*	Yes; No
Do you prefer a different graft choice when performing a simultaneous versus staged repair? (Choose one graft choice for simultaneous and one for staged)*	Simultaneous reconstruction: patellar tendon graft; Staged reconstruction: patellar tendon graft; Simultaneous reconstruction: hamstring graft; Staged reconstruction: hamstring graft; Simultaneous reconstruction: Allograft; Staged reconstruction: allograft; Simultaneous reconstruction: other; Staged reconstruction: other

*Questions asked if #3 response was ≥1. ACL, anterior cruciate ligament.

treatment strategy for patients with simultaneous bilateral ACL rupture. We are able to identify only three case reports that present the management of simultaneous bilateral ACL ruptures,²⁻⁴ with differing treatment strategies with respect to timing and graft choice, and all with relatively short follow-up times. Controversy exists with regards to optimal strategy management of bilateral ACL deficient knees. All existing studies in the literature examine outcomes of bilateral ACL reconstructions of injuries that were sustained at different times. Most studies suggest that simultaneous reconstruction is time and cost-effective and leads to less total rehabilitation time before return to sports. Larson *et al.*⁷ reported outcome in 11 patients who underwent single-setting bilateral ACL reconstruction using either patella tendon autograft or allograft. They demonstrated no increased incidence of complications when compared to a unilateral procedure. Similarly, Jari and Shelbourne⁹ reported a series of 28 patients who underwent single-setting sequential bilateral ACL reconstruction using ipsilateral patella tendon autograft and compared their results to a group of matched controls undergoing unilateral procedures. They reported no significant difference in postoperative pain and analgesic requirements, although overall blood loss was higher in the bilateral group, no patient required transfusion. Hechtman *et al.*¹⁰ compared the results of simultaneous bilateral ACL reconstruction to those of staged bilateral ACL reconstruction and reported similar functional outcomes. Simultaneous bilateral reconstruction was more time and cost-effective than staged bilateral ACL reconstruction. The total time in rehabilitation prior to clearance for unlimited athletic activity was significantly less in the simultaneous bilateral reconstruction group.

Given the paucity of literature and data on the optimal management of bilateral simultaneous ACL injuries, we conducted a national survey of practicing orthopedic sports medicine specialists (Sports Medicine Fellowship Directors and Sports Medicine Fellowship trained surgeons in the United States) to determine treatment preferences and graft choices. Bilateral simultaneous ACL rupture appears to be a rare injury: the majority of experienced sports medicine specialists surveyed have never encountered a patient with bilateral simultaneous ACL ruptures, and of those that have, most have only seen a single case during their career. The majority of survey respondents favored staged reconstructions, and while sex did not affect this decision, age was frequently cited as a factor in pursuing a staged *vs.* simultaneous reconstruction. Interestingly, and contrary to what the literature would suggest, about half of the surgeons with experience in treating bilateral

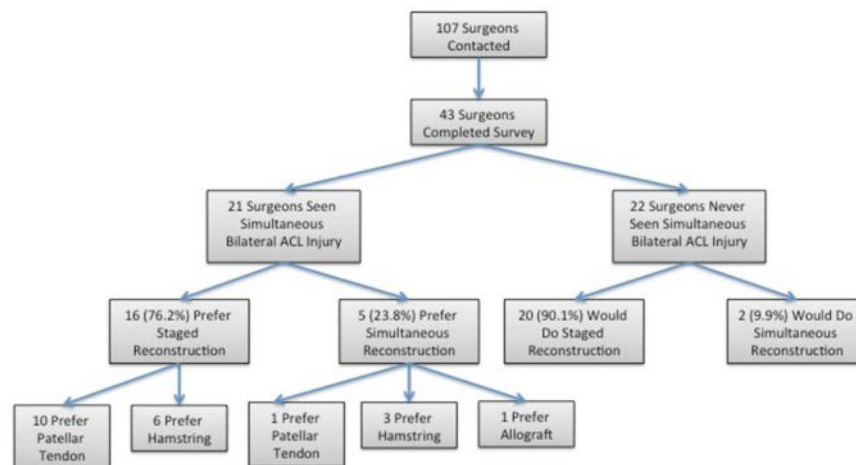


Figure 2. Results of a national survey of orthopedic sports medicine specialists' preferences for treatment of simultaneous bilateral anterior cruciate ligament injuries.

ACL injuries believed that simultaneous reconstruction increases rehabilitation time. No clear preference was identified with regards to graft choice, but most preferred either hamstring or patellar tendon autograft (Figure 2).

The results behind our survey may be multifactorial. Despite the current literature findings supporting the use of simultaneous ACL reconstruction, the majority of surgeons surveyed preferred a staged reconstruction. Reasons behind selecting a staged reconstruction may be due to fear of increased complications, difficulties with rehabilitation, and re-injury rate. While the current literature shows that these reasons are unfounded, they still may contribute to the decision to pursue a staged ACL reconstruction, as was the case with our patient. Our patient underwent staged ACL reconstructions with tibialis anterior allograft. The decision-making was shared between the senior author and the patient. In this case, the left knee was more symptomatic and, given the senior author's concern regarding difficulty of rehabilitation of a bilateral procedure, the procedures were staged and the more symptomatic knee was addressed first. We did not have a preference for graft choice as either autograft or allograft would be reasonable options for this patient. Our results were complicated by the development of a small Cyclops lesion in the right knee requiring revision, and a prolonged rehabilitation time; however our patient has returned to high-level skiing and continues to do very well at the last follow-up, 2.5 years since last operation.

Bilateral simultaneous ACL injuries are rare and presently no definitive guidelines for prop-

er management exist. This particular population remains a rare and difficult population to manage. Most sports medicine experts surveyed in our study considered staged reconstruction to be a viable treatment option over a simultaneous reconstruction, due to the concern with the duration of surgery and rehabilitation difficulties associated with a simultaneous bilateral ACL reconstruction. However, majority of the literature have reported favorable outcome with patients after simultaneous bilateral ACL reconstruction. In patients that present with bilateral ACL ruptures, both simultaneous and staged reconstruction can be an option for the patient. Most importantly, it is essential for the patient to understand the risk and benefits of each management options, especially regarding the post-operative rehabilitation and restrictions.

References

1. Sadoghi P, Von Keudell A, Vavken P. Effectiveness of anterior cruciate ligament injury prevention training programs. *J Bone Joint Surg Am* 2012;94:769-76.
2. Sanchis-Alfonso V, Tinto-Pedrerol M. Simultaneous bilateral anterior cruciate ligament tears in a female beginner skier. *Knee Surg Sports Traumatol Arthrosc* 2000;8:241-3.
3. Tifford CD, Jackson DW. Simultaneous bilateral anterior cruciate ligament ruptures in a cheerleader. *Arthroscopy* 2001;17:E17.

4. Maywood RM, Hechtman KS. Simultaneous bilateral anterior cruciate ligament tears. *Am J Knee Surg* 1995;8:134-6.
5. Jari S, Shelbourne KD. Simultaneous bilateral anterior cruciate ligament reconstruction. *Am J Sports Med* 2002;30:891-5.
6. Saithna A, Arbuthnot J, Carey-Smith R, Spalding T. Simultaneous bilateral anterior cruciate ligament reconstruction: a safe option. *Knee Surg Sports Traumatol Arthrosc* 2010;18:1071-4.
7. Larson CM, Fischer DA, Smith JP, Boyd JL. Bilateral anterior cruciate ligament reconstruction as a single procedure: evaluation of cost and early functional results. *Am J Sports Med* 2004;32:197-200.
8. Shelbourne KD, Patel DV. Timing of surgery in anterior cruciate ligament-injured knees. *Knee Surg Sports Traumatol Arthrosc* 1995;3:148-56.
9. Jari S, Shelbourne KD. Staged bilateral anterior cruciate ligament reconstruction with use of contralateral patellar tendon autograft: a case report. *Am J Sports Med* 2002;30:437-40.
10. Hechtman KS, Tjin-Tsoi EW, Uribe JW, et al. Simultaneous vs staged bilateral anterior cruciate ligament reconstruction with endoscopic technique. *Arthroscopy* 1998;14:S17.