



The importance of prevention of calciphylaxis in patients who are at risk and the potential fallibility of calcimimetics in the treatment of calciphylaxis for patients with secondary hyperparathyroidism

Citation

Khalpey, Zain, Matthew A. Nehs, Andrew W. ElBardissi, Marcus Semel, and Stefan G. Tullius. 2009. "The importance of prevention of calciphylaxis in patients who are at risk and the potential fallibility of calcimimetics in the treatment of calciphylaxis for patients with secondary hyperparathyroidism." *NDT Plus* 3 (1): 68-70. doi:10.1093/ndtplus/sfp120. <http://dx.doi.org/10.1093/ndtplus/sfp120>.

Published Version

[doi:10.1093/ndtplus/sfp120](https://doi.org/10.1093/ndtplus/sfp120)

Permanent link

<http://nrs.harvard.edu/urn-3:HUL.InstRepos:16120866>

Terms of Use

This article was downloaded from Harvard University's DASH repository, and is made available under the terms and conditions applicable to Other Posted Material, as set forth at <http://nrs.harvard.edu/urn-3:HUL.InstRepos:dash.current.terms-of-use#LAA>

Share Your Story

The Harvard community has made this article openly available. Please share how this access benefits you. [Submit a story](#).

[Accessibility](#)

Case Report

The importance of prevention of calciphylaxis in patients who are at risk and the potential fallibility of calcimimetics in the treatment of calciphylaxis for patients with secondary hyperparathyroidism

Zain Khalpey, Matthew A. Nehs, Andrew W. ElBardissi, Marcus Semel and Stefan G. Tullius

Division of Transplantation Surgery, Department of Surgery, Brigham & Women's Hospital, Harvard Medical School, 75 Francis Street, Boston, MA 02115, USA

Correspondence and offprint requests to: Stefan G. Tullius; E-mail: stullius@partners.org

Abstract

A 43-year-old African American with end-stage renal disease (ESRD) associated with membranous nephropathy and a previously failed renal transplant had received cinacalcet to treat his secondary hyperparathyroidism. Serum calcium and phosphorus levels remained within normal limits, and serum parathyroid levels had dropped significantly following treatment initiation. However, within 7 months, the patient experienced extensive necrotic bilateral medial thigh ulcers. These were biopsied and found to be a result of calciphylaxis. The patient ultimately required an urgent subtotal parathyroidectomy and recovered well with completely healed ulcers.

Keywords: calciphylaxis; cinacalcet; hyperparathyroidism; sensipar

The case

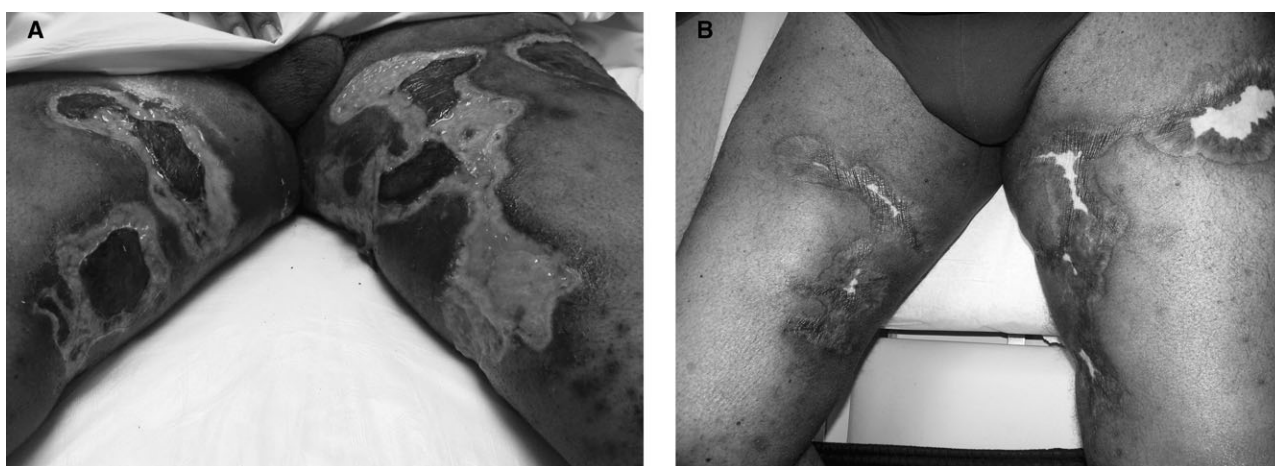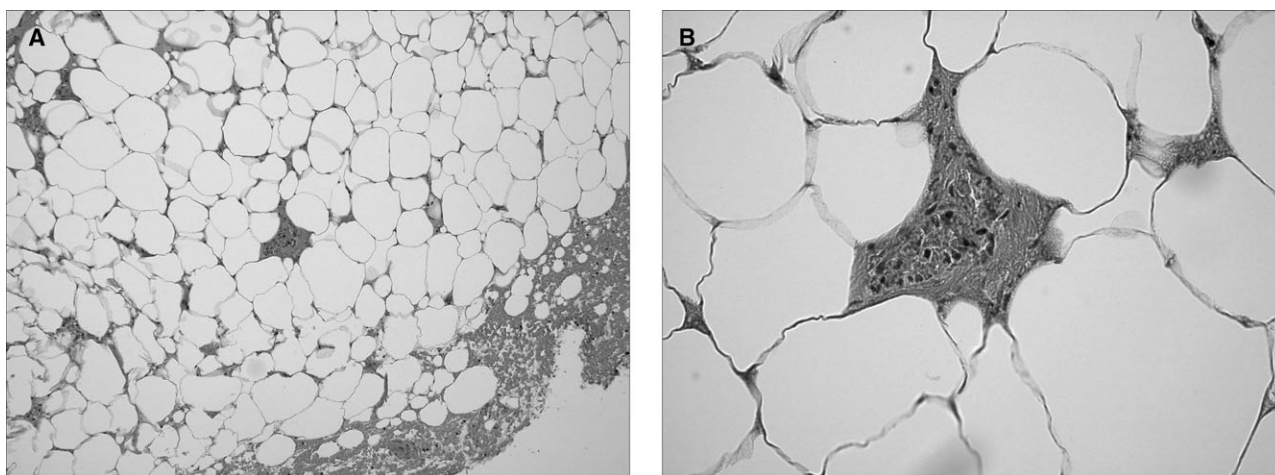
The patient was a 43-year-old obese African American male with a past medical history significant for end-stage renal disease (ESRD) secondary to membranous nephropathy and pulmonary embolism requiring anticoagulation with warfarin. He underwent a cadaveric renal transplantation that had failed because of non-reversible ATN in the setting of hypotension from cytokine release syndrome while taking thymoglobulin. Shortly after transplant failure, the patient re-initiated haemodialysis and was started on cinacalcet 30 mg orally per day (Table 1). At that time, the patient had normal serum calcium in the presence of highly elevated parathyroid hormone (PTH) levels (max: 2516 pg/mL). His Ca × PO₄ product was elevated (68) at the initiation of treatment. As per outpatient pharmacy records, the patient's prescriptions were filled regularly, and he confirmed that he was taking his medications as prescribed. During the 7 months, following the initiation of cinacalcet, the patient was seen closely in the outpatient setting and denied any weakness, fatigue, constipation, nausea or abdominal pain. In the following months, the patient's cal-

cium level remained within normal limits, and his PTH serum level dropped to 361 pg/mL. As such, the determination was made that cinacalcet treatment in this patient was effective, and the patient continued on this regimen.

Eight months after initiation of cinacalcet, the patient complained of superficial ulcerations on his inner thighs bilaterally (Figure 1a). A biopsy was performed and revealed epidermal necrosis and ulceration with a dermal acute inflammatory infiltrate. No histologic evidence of calciphylaxis was seen, and von Kossa stain was negative for calcium at that time. Despite normal serum calcium levels, the patient was titrated up on his cinacalcet dose from 30 mg orally daily to 60 mg orally twice daily after identification of the ulcers; PTH at this time was 361.5 pg/mL, and the Ca × PO₄ product had increased to 75. The lesions developed rapidly over the following weeks to several large eschars over the inner aspect of his thighs with increasing pain. The eschar on his left inner thigh began draining significant amounts of clear fluid, saturating his dressing. Empiric antibiotics (ciprofloxacin and metronidazole) were begun prior to the return of wound culture data that ultimately revealed a significant growth of *staphylococcus aureus*. It was noted that the previously tender brown papules had progressed to areas of sclerotic and ulcerated plaques with a black necrotic base. Two weeks after this initial evaluation as an outpatient, the patient was admitted with an elevated white count and low-grade fevers concerning for infection. The patient was started on intravenous vancomycin, ceftazidime and metronidazole for broad spectrum coverage. The ulcer was cultured and confirmed the growth of coagulase negative *S. aureus*, which was suggestive of skin flora. A subsequent biopsy of the necrotic lesions revealed microcalcific deposits in the walls of small subcutaneous vessels associated with extensive intraluminal thrombosis (Figure 2a and b). The larger deep dermal vessels demonstrated prominent calcium deposits and obliterative intraluminal thrombi. The subcutis, dermis and epidermis exhibited changes of ischaemic infarction. Of note, at the time of biopsy-proven calciphylaxis, the patient's PTH was 394.2 pg/mL with a serum calcium of 9.0 mg/dL.

Table 1. Results of patient laboratory investigations before and after treatment with cinacalcet

	Initiation of treatment	Development of ulcerations	Prior to surgery	Recovery	Four months post-surgery
PTH	361.5	361.5	394.2	<Assay range	4.2
Calcium	8.5	8.7	7.9	8.6	6.3
HCO ₃ ⁻	25	24	28	25	25
Phosphorus	8	8.6	5.6	3.5	4.4
Magnesium	2.1	2.3	2.3	2.1	1.4
Albumin	3.1	3.3	3.3	2.8	3.8
Na	137	136	136	142	143
K	5.2	3.9	4.6	4.1	4.4
Cl	96	93	93	99	103
BUN	68	43	48	35	71
Cr	18.06	12.29	10.03	5.54	6.72
Glucose	76	75	84	98	185
Ca × PO ₄ product	68	74.8	44	30.1	27.7

**Fig. 1.** (a) Proximal calciphylaxis: bilateral inner thighs (while on cinacalcet). (b) Resolving calciphylaxis: 8 weeks after stopping cinacalcet and following sub-total parathyroidectomy.**Fig. 2.** (a) Tissue biopsy of calciphylaxis highlighting calcium phosphate deposition (×10 magnification). (b) Tissue biopsy of calciphylaxis highlighting calcium phosphate deposition (×40 magnification).

IV antibiotic treatment was continued and the patient underwent an urgent and uneventful subtotal parathyroidectomy. Histological evaluation of the parathyroid glands showed hyperplasia. Cinacalcet treatment was discontinued and the thigh lesions continued to improve over the next 8 months following subtotal parathyroidectomy with conservative wound therapy (Figure 1b). His PTH, serum calcium and phosphate returned to normal levels.

Discussion

Calciphylaxis, or calcific uraemic arteriopathy, is a rare disorder of vascular calcification that primarily affects patients with a history of end-stage renal disease, including patients who have undergone renal transplantation [1]. While the pathogenesis of the disorder is not fully elucidated, the likely mechanism is small blood vessel occlusion and local ischaemia resulting in infarction of the involved tissues, which is responsible for the characteristic skin ulcerations [2]. There are several predisposing factors associated with this condition including renal failure, uraemia, diabetes mellitus, warfarin use, obesity, hyperparathyroidism, and elevated calcium–phosphate product [2]. It is likely that these conditions disrupt calcium homeostasis and favour the precipitation and deposition of calcium in small blood vessels leading to the disorder; however, no single risk factor is necessary or sufficient to produce the clinical features of calciphylaxis [3,4].

Therapeutic options for calciphylaxis are limited and clearly unsatisfactory given the continued high mortality of the disease. The mainstay of therapy includes prevention with calcium and phosphate control in patients at risk, avoidance of skin trauma and local wound care when ulcerations develop [5]. In addition to local wound care, medical therapy with sodium thiosulfate has been reported with success [6,7], and Vassa *et al.* have used hyperbaric oxygen in the treatment of calciphylaxis ulcers [8,9]. More recently, calcimimetics have been used in the treatment of calciphylaxis. Cinacalcet, a type II calcimimetic, increases the sensitivity of parathyroid cells to extracellular calcium and thereby reduces the secretion of PTH. In 2004, the US Food and Drug Administration (FDA) approved cinacalcet-HCl (Sensipar[®], Amgen) for the treatment of secondary hyperparathyroidism in patients with chronic kidney disease on dialysis. The drug was also approved for the treatment of hypercalcaemia in patients with a parathyroid carcinoma at the recommended oral starting dose of 30 mg once daily. Cinacalcet has also been suggested as an alternative treatment for patients with primary or secondary hyperparathyroidism who do not meet the criteria for parathyroidectomy or in whom parathyroidectomy has failed [10,11].

Experience with calcimimetics in the treatment of calciphylaxis is sparse and limited to a few case reports. Velasco *et al.* reported a case of distal calciphylaxis successfully treated with cinacalcet as an alternative to parathyroidectomy [12]. In his report, treatment with cinacalcet 60–120 mg/day for a period of 9 months reduced PTH levels with resolution of the distal leg ulcers. In our patient,

however, cinacalcet reduced PTH values significantly and normalized serum calcium levels but failed to produce a clinical response. He was on cinacalcet for 8 months prior to the development of the thigh ulcers. After identification of the ulcers, our patient's cinacalcet dose was uptitrated to 60 mg orally twice daily for a period of 4 weeks; however, the thigh ulcers did not improve. Sub-total parathyroidectomy has been used in cases of refractory calciphylaxis, which was required in our patient and resulted in a dramatic clinical improvement in his thigh ulcers over time (Figure 1b).

In summary, our patient demonstrated a case of clinical resistance to cinacalcet for the pharmaceutical treatment of proximal bilateral calciphylaxis in the setting of secondary hyperparathyroidism secondary to renal failure. He had several predisposing factors to the development of this condition including ESRD, obesity, high Ca × PO₄ product and warfarin use. Despite a significant decrease in PTH, discontinuation of warfarin, and continued cinacalcet therapy, he progressed to calciphylaxis ulcerations and required a subtotal parathyroidectomy. This case underscores the importance of prevention of calciphylaxis in patients who are at risk for the condition and the potential fallibility of calcimimetics in the treatment of calciphylaxis for patients with secondary hyperparathyroidism.

Conflict of interest statement. None declared.

References

- Egbuna OI, Taylor JG, Bushinsky DA *et al.* Elevated calcium phosphate product after renal transplantation is a risk factor for graft failure. *Clin Transplant* 2007; 21: 558–566
- Guldbakke K, Khachemoune A. Calciphylaxis. *Int J Dermatol* 2007; 46: 231–238
- Nigwekar SU, Wolf M, Sterns RH *et al.* Calciphylaxis from nonuremic causes: a systematic review. *Clin J Am Soc Nephrol* 2008; 3: 1139–1143
- Bright T, Joukhadar R. Calciphylaxis in primary hyperparathyroidism: a case report and brief review. *South Med J* 2009; 102: 318–321
- Don BR, Chin AI. Strategy for the treatment of calcific uremic arteriopathy (calciphylaxis) employing a combination of therapies. *Clin Nephrol* 2003; 59: 463–467
- Araya CE, Fennell RS, Neiberger RE *et al.* Sodium thiosulfate treatment for calcific uremic arteriopathy in children and young adults. *Clin J Am Soc Nephrol* 2006; 1: 1161–1166
- Bruculeri M, Cheigh J, Bauer G *et al.* Long-term intravenous sodium thiosulfate in the treatment of a patient with calciphylaxis. *Semin Dial* 2005; 18: 431–434
- Vassa N, Twardowski ZJ, Campbell J *et al.* hyperbaric oxygen therapy in calciphylaxis induced necrosis in peritoneal dialysis patients. *Am J Kidney Dis* 1994; 23: 878–881
- Basile C, Montanaro A, Masi M *et al.* Hyperbaric oxygen therapy for calcific uraemic arteriopathy: a case series. *J Nephrol* 2002; 15: 676–680
- Barman Balfour JA, Scott LJ. Cinacalcet hydrochloride. *Drugs* 2005; 65: 271–281
- Joy MS, Kshirsagar AV, Franceschini N. Calcimimetics and the treatment of primary and secondary hyperparathyroidism. *Ann Pharmacother* 2004; 38: 1871–1880
- Velasco N, Mac Gregor MS, Innes A *et al.* Successful treatment of calciphylaxis with cinacalcet—an alternative to parathyroidectomy? *Nephrol Dial Transplant* 2006; 21: 1999–2004

Received for publication: 6.7.09; Accepted in revised form: 6.8.09