



Simulated Activity But Real Trauma: A Systematic Review on Nintendo Wii Injuries Based on a Case Report of an Acute Anterior Cruciate Ligament Rupture

Citation

Müller, Sebastian A., Patrick Vavken, and Geert Pagenstert. 2015. "Simulated Activity But Real Trauma: A Systematic Review on Nintendo Wii Injuries Based on a Case Report of an Acute Anterior Cruciate Ligament Rupture." *Medicine* 94 (12): e648. doi:10.1097/MD.0000000000000648. <http://dx.doi.org/10.1097/MD.0000000000000648>.

Published Version

doi:10.1097/MD.0000000000000648

Permanent link

<http://nrs.harvard.edu/urn-3:HUL.InstRepos:23474044>

Terms of Use

This article was downloaded from Harvard University's DASH repository, and is made available under the terms and conditions applicable to Other Posted Material, as set forth at <http://nrs.harvard.edu/urn-3:HUL.InstRepos:dash.current.terms-of-use#LAA>

Share Your Story

The Harvard community has made this article openly available.
Please share how this access benefits you. [Submit a story](#).

[Accessibility](#)

Simulated Activity But Real Trauma: A Systematic Review on Nintendo Wii Injuries Based on a Case Report of an Acute Anterior Cruciate Ligament Rupture

Sebastian A. Müller, MD, Patrick Vavken, MD, MSc, and Geert Pagenstert, MD

Abstract: Video gaming injuries are classically regarded as eccentric accidents and novelty diagnoses. A case of an anterior cruciate ligament (ACL) tear sustained during Wii boxing spurred us to review the literature for other Wii-related injuries and Wii-based posttraumatic rehabilitation.

The English literature listed in PubMed was systematically reviewed by searching for “Wii (trauma or injury or fracture).” Full-text articles were included after duplicate, blinded review. The type and treatment of injury as well as the Wii-based rehabilitation programs found were analyzed. Additionally, a new case of an acute ACL tear-sustained playing, Wii boxing, is additionally presented.

After exclusion of irrelevant articles, 13 articles describing Wii-related injuries were included reporting on 3 fractures, 6 nonosseous, 2 overuse injuries, and 2 rehabilitation programs using Wii for posttraumatic rehabilitation. Among the presented Wii-related injuries, only 12.5% were treated conservatively, whereas 87.5% underwent either surgical or interventional treatment.

Because of the reported case, the literature search was limited to Wii-related injuries excluding other video games. Another limitation of this article lies in the fact that mainly case reports but no controlled trials exist on the topic. Assumingly, primarily the more severe injuries are reported in the literature with an unknown number of possibly minor injuries.

Motion-controlled video games, such as Wii, are becoming increasingly popular as a recreational entertainment. Because of their wide acceptance and entertaining nature, they are also increasingly recognized as a tool in rehabilitation. However, although the activity is simulated, injuries are real. Our systematic review shows that Wii gaming can lead to severe injuries, sometimes with lasting limitations.

(*Medicine* 94(12):e648)

Abbreviations: ACL = anterior cruciate ligament, MPFL = medial patella femoral ligament.

Editor: Stuart Barry Polinsner.

Received: January 14, 2015; revised: February 19, 2015; accepted: February 20, 2015.

From the Department of Orthopedic Surgery (SAM, PV, GP), University of Basel, Basel, Switzerland; and Division of Sports Medicine (PV), Boston Children's Hospital, Harvard Medical School, Boston, Massachusetts.

Correspondence: Sebastian A. Müller, Department of Orthopedic Surgery, University of Basel, Spitalstrasse 21, Basel 4031, Switzerland (e-mail: sebastian.mueller@usb.ch).

The authors have no funding and conflicts of interest to disclose.

Copyright © 2015 Wolters Kluwer Health, Inc. All rights reserved.

This is an open access article distributed under the Creative Commons Attribution-NonCommercial-NoDerivatives License 4.0, where it is permissible to download, share and reproduce the work in any medium, provided it is properly cited. The work cannot be changed in any way or used commercially.

ISSN: 0025-7974

DOI: 10.1097/MD.0000000000000648

INTRODUCTION

The popular Nintendo Wii (Nintendo, Kyoto, Japan) is a so-called “motion-controlled” game console, played by imitating real 3-dimensional sport movements encouraging the protagonist to get up off the couch. Although such motion-controlled home entertainment has the additional benefit of physical activity, this “more active type” of computer gaming is also associated with a higher risk for injuries. Classic overuse injuries have already been reported with sit-down consoles. In 1990, Brasington¹ described “Nintendinitis,” an inflammation of the extensor pollicis longus tendon caused by repetitive button pressing during video gaming. Later, in 2000, Koh² reported ulcerations caused by excessively using joysticks as “ulcerative Nintendinitis.” However, with this new type of entertainment, injuries have spread from overuse of the hand and fingers to the rest of the musculoskeletal apparatus. Thus, even though the activity is simulated, the resulting injury is all too real.

We have recently encountered a 44-year-old female patient with an anterior cruciate ligament (ACL) rupture, sustained playing Wii boxing. The patient felt instability immediately after injury. Nonoperative treatment including physical therapy was initiated. Because of the remaining instability, she heavily twisted here knee after 6 months again resulting in a medial meniscus tear (Figure 1A and B). Finally, we performed an arthroscopic partial meniscectomy and an ACL reconstruction using an autologous semitendinosus graft (Figure 1C and D), followed by an uneventful recovery.

This experience has led us to wonder about the epidemiology of Wii-associated musculoskeletal injury. An aggravating circumstance is that Wii is increasingly being used as a tool in physiotherapy and rehabilitation, that is, promoting Wii-associated injuries from eccentricities to a, may be legally relevant, complication of a recommended treatment. For these reasons, we conducted this systematic review to describe the Wii-related injuries and the current use of Wii gaming in posttraumatic rehabilitation.

MATERIALS AND METHODS

We performed a systemic review of the English literature in PubMed (May 2014) searching for “Wii,” “Wii Nintendo,” “Wii AND (trauma or injury or fracture or rehabilitation),” “Wii AND (trauma or injury or fracture),” “Wii injury,” “Wii trauma,” or “Wii fracture.” Eligible studies reported on the use of Wii in rehabilitation or injuries associated with Wii. Other motion-controlled consoles were not included because of heterogeneous terminology rendering systematic search unreliable. All studies were reviewed in duplicate and independently for eligibility of inclusion and content. All results are presented descriptively and divided into 2 sections: Wii injury and use of Wii in posttraumatic rehabilitation. Because of the considerable mathematical and clinical heterogeneity, no formal quantitative

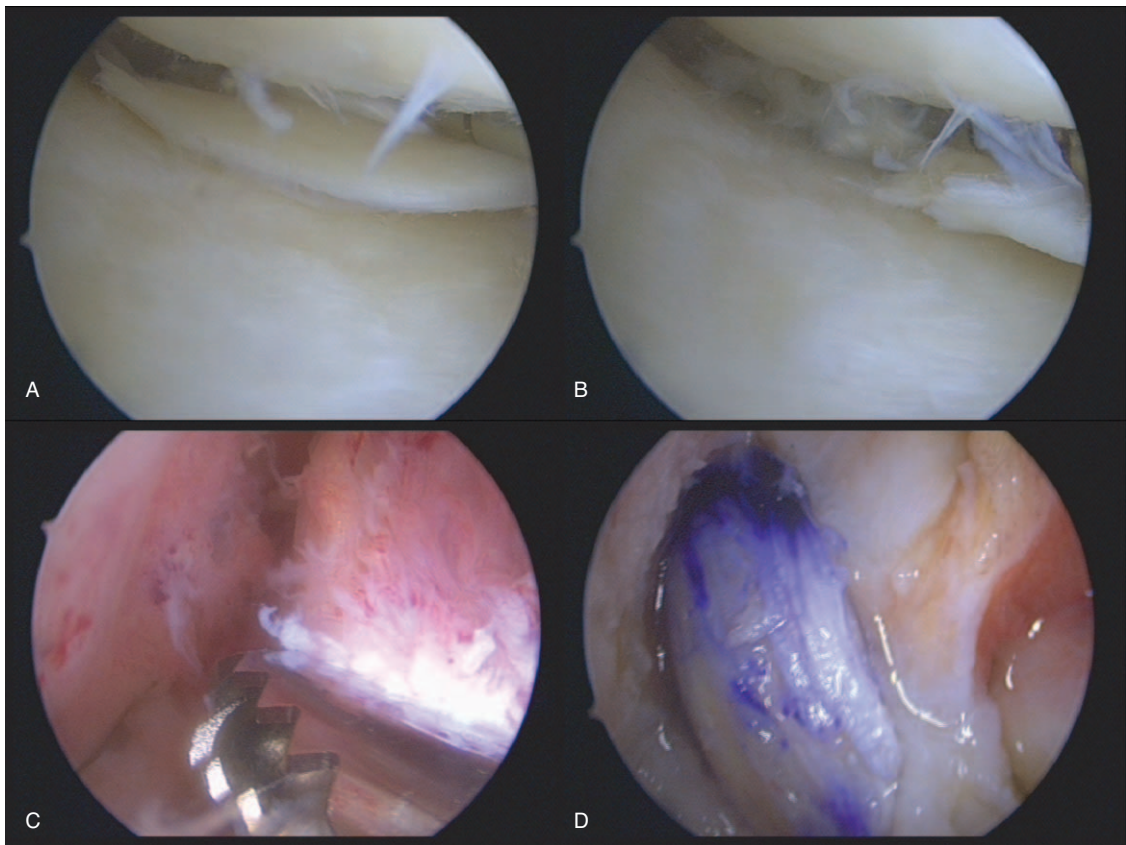


FIGURE 1. (A and B) Arthroscopic image showing the torn meniscus, (C) the ACL tear at its origin with corresponding inflammation before debridement, and (D) the new ACL graft in place. ACL = anterior cruciate ligament.

data synthesis was aspired, but published cases were quantitatively assessed for type of treatment: conservative, interventional, or surgical.

No approval by the local ethics committee was requested, neither for the systematic review of the literature nor the completely anonymously presented case.

RESULTS

Our search produced 766 results depending on the searched term (Table 1). Based on our traumatic case, we have systematically analyzed the 44 articles found by the search for “Wii

(trauma or injury or fracture).” After exclusion of irrelevant articles, 13 articles remained (Figure 2). Among these, 3 describe a fracture, 6 an injury other than fracture, 2 an overuse, and 2 the rehabilitation potential of Wii in patients after injury (Table 2).

TABLE 1. Searched Terms and Corresponding Number of Results (n)

| Searched Term | n |
|------------------------------------------------------|-----|
| Wii fracture | 6 |
| Wii trauma | 36 |
| Wii injury | 37 |
| Wii (trauma or injury or fracture) | 44 |
| Wii (trauma or injury or fracture or rehabilitation) | 131 |
| Wii Nintendo | 173 |
| Wii | 339 |
| Total | 766 |

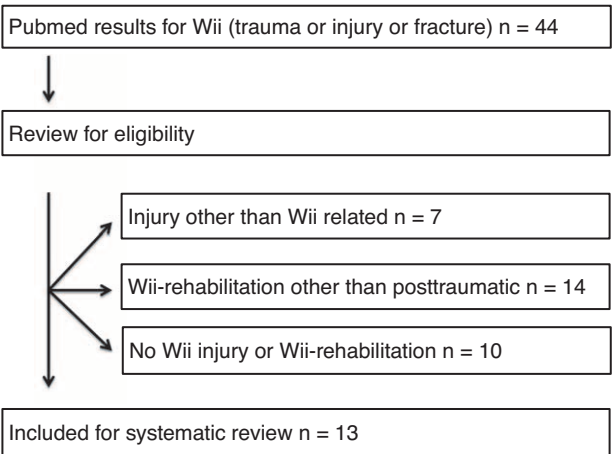


FIGURE 2. Selection process for PubMed results on “Wii (trauma or injury or fracture).”

TABLE 2. Reviewed Articles After Exclusion of Irrelevant Papers*

| Authors | Year | Title | Journal | Design | Profile | Treatment | n |
|---------------------------------|------|-------------------------------------------------------------------------------------------------------------------------------------------|---------------------|-----------------------------|----------------|----------------------------------|----|
| Brown and McKenna ³ | 2009 | A Wii-related clay-shovelers' fracture | Sci World J | Case report | Fracture | Conservative/secondary operative | 1 |
| Eley ⁴ | 2010 | A Wii fracture | N Engl J Med | Case report | Fracture | Conservative | 1 |
| Galanopoulos et al ⁵ | 2012 | A Wii virtual activity severe thumb metacarpal injury | BMJ Case Rep | Case report | Fracture | Operative | 1 |
| Robinson et al ⁶ | 2008 | Wii knee | Emerg Radiol | Case report | Injury | Operative | 1 |
| Faivre et al ⁷ | 2009 | Internal carotid artery dissection occurring during intensive practice with Wii video sports games | Neurology | Case report | Injury | Intravenous thrombolysis | 2 |
| Bhangu et al ⁸ | 2009 | Wimbledon or bust: Nintendo Wii-related rupture of the extensor pollicis longus tendon | J Hand Surg Eur Vol | Case report | Injury | Operative | 1 |
| Almedghio et al ⁹ | 2009 | Wii knee revisited: meniscal injury from 10-pin bowling | BMJ Case Rep | Case report | Injury | Operative | 1 |
| Razavi and Lam ¹⁰ | 2011 | Wii eye injury: self-inflicted globe rupture and vision loss in a 7-year-old boy from a video game accident | J AAPOS | Case report | Injury | Operative | 1 |
| Khan et al ¹¹ | 2013 | Acute hemial strangulation following Wii fit exercises | Acta Chir Belg | Case report | Injury | Operative | 1 |
| Rubin ¹² | 2010 | Triad of spinal pain, spinal joint dysfunction, and extremity pain in 4 pediatric cases of "Wii-itis": a 21st century pediatric condition | J Chiropr Med | Case report | Overuse | Conservative (chiropractic) | 4 |
| Baxter and Madhok ¹³ | 2011 | A case of arm swelling and muscle pain | Scott Med J | Case report | Overuse | Conservative | 1 |
| Yohannan et al ¹⁴ | 2012 | The utilization of Nintendo® Wii™ during burn rehabilitation: a pilot study | J Burn Care Res | Randomized controlled study | Rehabilitation | Rehabilitation program | 23 |
| Sims et al ¹⁵ | 2013 | Exergaming and static postural control in individuals with a history of lower limb injury | J Athl Train | Randomized controlled study | Rehabilitation | Rehabilitation program | 28 |

*The number of patients (n) is given for each article. Order by profile of injury and rehabilitation, respectively.

Fractures

Brown and McKenna³ first described a Wii-related fracture in 2009. A 38-year-old man sustained an acute C7 spinous process fracture after heavily swinging his Wii game console. After 3 months of conservative treatment, the posterior fracture fragment had to be resected due to persistent posterior neck pain.

Eley⁴ reported on a 14-year-old girl with a proximal fifth metatarsal fracture after falling off the Wii Fit balance board and sustaining an inversion injury. The fracture healed well after conservative treatment.

The third fracture case was described by Galanopoulos et al⁵ in 2012. A 54-year-old teacher sustained a Rolando fracture of the first metacarpal base while playing Wii bowling and hitting his right hand against a glass coffee table. The fracture needed to be operatively reduced and internally fixed with a plate.

Nonosseous Trauma

Robinson et al⁶ presented a 16-year-old boy with lateral patella dislocation, osteochondral lesion of the lateral femur condyle, and complete rupture of the medial patella femoral ligament (MPFL) after twisting the knee while playing Wii. The patient underwent surgical fixation of the osteochondral fragment along with repair of the MPFL and progressed well postoperatively.

Faivre et al⁷ reported on a 47-year-old woman and a 14-year-old boy with an acute ischemic stroke due to an internal carotid dissection after 3 hours of Wii tennis and Wii running, respectively. Being in good health before, both patients presented with acute onset of headache followed by hemiplegia. Both were treated by an intravenous thrombolysis. The boy recovered completely, whereas the woman was still dependent after 3 months.

Bhangu et al⁸ described an acute rupture of the extensor pollicis longus tendon while playing tennis and hitting her hand to a wall requiring tendon surgery.

Almedghio et al⁹ treated a 23-year-old woman who sustained a tear of her medial meniscus while playing Wii bowling. The patient underwent partial medial meniscectomy and recovered well afterward.

A severe eye injury was reported by Razavi and Lam¹⁰ in 2011. While playing tennis, a 7-year-old boy struck his left eye with the controller in his right hand and suffered a globe rupture and nearly complete loss of vision. The same day the prolapsed uvea was repositioned and the corneal-scleral laceration repaired. The case was complicated by a total hyphema and later by a central corneal scar and a cataract. Ten months after injury, vision remained impaired and an ultrasound revealed a detached retina. However, the parents refused any further surgery.

Khan et al¹¹ described the first abdominal trauma after Wii sports. A patient with a preexisting paraumbilical hernia presented with acute strangulation of her small bowel after completing her aerobic exercises on Wii Fit. The patient required emergency laparotomy including small bowel resection of the infarcted part.

Overuse

Rubin¹² described 4 children aged 3 to 9 years presenting to a chiropractic clinic with spinal pain, spinal joint dysfunction (subluxation), and related extremity pain after excessive gaming. All children were successfully treated with chiropractic manipulations.

Baxter and Madhok¹³ presented another case of overuse in a patient with acute arm swelling associated with a rise in serum creatine kinase to >8000 U/L after excessive Wii gaming. Conservative treatment and rest was initiated and the symptoms resolved soon.

Rehabilitation

The systematic search produced 2 studies describing the rehabilitation potential of Wii computer games after different types of injuries.

Yohannan et al¹⁴ investigated the benefit of Nintendo Wii for burn victim rehabilitation in a randomized controlled study; 23 patients were randomized according to their burn localization into Wii and control treatment groups. Comparable results were found in both the groups. However, the Wii group seemed to experience less pain ($P=0.07$) and to be more enjoyable.

In 2013, Sims et al¹⁵ presented a single blinded randomized controlled trial on 28 patients after lower limb injury undergoing a Wii Fit-based rehabilitation program, traditional physical therapy, or control. Both therapy groups resulted in almost equally improved static postural control with opened and closed eyes ($P<0.05$) compared with the control group.

Quantitative analysis

Quantitative analysis regarding treatment type could only be performed for the 11 articles on Wii injuries with the presented ACL rupture (16 patients in total) but not for the 2 articles on posttraumatic Wii rehabilitation; 50% of Wii-related injuries (8 patients) required surgical treatment, 12.5% (2 patients) interventional IV thrombolysis, and 25% (4 patients) underwent chiropractic intervention. Only 12.5% of the presented patients (2) were treated in a truly conservative manner.

DISCUSSION

The popular computer console Wii has been sold >100 million times. While gaming, the Wii user is supposed to actively participate with the whole body comparably to real sports. Furthermore, the affected population has been considered to deviate toward the less well-trained end of the Gaussian bell. Thus, some of the training intensities are comparable or even more extensive to those of conventional sports and can result in injuries as severe as acute carotid dissection after 3 hours of Wii running or Wii tennis. It is unlikely that players prepare or warm up for extended Wii sport session. An adequate warm up is mentioned in none of the cited publications on Wii injuries. However, this kind of physical activity has a real risk of injury.

Even if the published number of severe injuries is very little compared with the tremendous number of sold Wii consoles, our systematic review has revealed severe injuries that mainly needed interventional or surgical treatment. Among these are one potentially life-threatening injury (acute strangulation of small bowel) and several injuries with potential long-lasting consequences such as a globe rupture leading to loss of vision, an osteochondral lesion of the knee, a meniscus tear, or an ACL rupture described by us. All of the 3 latter are known for an increased risk of posttraumatic osteoarthritis. Beside these, a number of overuse injuries is mentioned in the literature. However, for all injury types, a considerable publication bias has to be assumed as “Wii use” is not classically collected and documented as injury mechanism.

Even if Nintendo advertises its Wii for the entire family from 5 to 95 years, the game console is probably most prevalent

among children and adolescents. However, also typical injuries of the elderly are thinkable, for example, a femoral neck fracture of the grandparents' generation.

On the contrary, Wii has a major potential for rehabilitation of posttraumatic patients. Especially in younger populations, video games are well accepted and thus met with much less skepticism and malcompliance than traditional rehabilitation. The rehabilitation potential of patients with neurologic disorders, such as multiple sclerosis or Parkinson's disease, children with coordination problems, and athletes (eg, ACL reconstruction) is described in the literature extensively. This rehabilitation potential stands in contrast with the risk for injury by playing active games. Yet, in case of rehabilitation, it could be assumed that the risk of injury is decreased as usually professional therapists supervise the rehabilitation programs. Moreover, the use of computer games for special rehabilitation programs would probably be restricted if the incident rate was high for this population.

The limitations of this article lie in the sole focus on Wii-related injuries preset by the presented case, excluding other video game-sustained injuries. However, the used search criteria yielded a category of rehabilitation programs using Wii games for patients with certain injuries. The used search criteria excluded successful rehabilitation regimens other than post-traumatic and the large number of overuses by computer gaming mainly known as "Nintendonitis." Unfortunately, this review is mainly based on case reports as no controlled studies concerning Wii injuries exist. Presumably, only the extraordinary severe injuries are described in the literature and an uncertain number of minor injuries is not reported.

In summary, motion-controlled video games are becoming increasingly popular as a recreational entertainment. Because of their wide acceptance and entertaining nature, they are also increasingly recognized as a tool in rehabilitation. However, although the activity is simulated, injuries are real. Our systematic review shows that Wii gaming can lead to severe injuries, sometimes with lasting limitations. Thus, awareness of potential risks of Wii overuse or abuse should be created, as Wii-related injuries are increasingly likely to show up in our clinics.

REFERENCES

1. Brasington R. Nintendinitis. *N Engl J Med*. 1990;322:1473–1474.
2. Koh TH. Ulcerative "nintendinitis": a new kind of repetitive strain injury. *Med J Aust*. 2000;173:671.
3. Brown CN, McKenna P. A Wii-related clay-shoveler's fracture. *Sci World J*. 2009;9:1190–1191.
4. Eley KA. A Wii fracture. *N Engl J Med*. 2010;362:473–474.
5. Galanopoulos I, Garlapati AK, Ashwood N, et al. A Wii virtual activity severe thumb metacarpal injury. *BMJ Case Rep*. 2012; doi:10.1136/bcr-2012-007224.
6. Robinson RJ, Barron DA, Grainger AJ, et al. Wii knee. *Emerg Radiol*. 2008;15:255–257.
7. Faivre A, Chapon F, Combaz X, et al. Internal carotid artery dissection occurring during intensive practice with Wii video sports games. *Neurology*. 2009;73:1242–1243.
8. Bhangu A, Lwin M, Dias R. Wimbledon or bust: Nintendo Wii related rupture of the extensor pollicis longus tendon. *J Hand Surg Eur Vol*. 2009;34:399–400.
9. Almedghio SM, Shablahidis O, Rennie W, et al. Wii knee revisited: meniscal injury from 10-pin bowling. *BMJ Case Rep*. 2009; doi:10.1136/bcr.11.2008.1189.
10. Razavi H, Lam G. Wii eye injury: self-inflicted globe rupture and vision loss in a 7-year-old boy from a video game accident. *J AAPOS*. 2011;15:491–492.
11. Khan OA, Parvaiz AC, Vassallo DJ. Acute hernial strangulation following Wii Fit exercises. *Acta Chir Belg*. 2013;113:58–59.
12. Rubin D. Triad of spinal pain, spinal joint dysfunction, and extremity pain in 4 pediatric cases of "Wii-itis": a 21st century pediatric condition. *J Chiropr Med*. 2010;9:84–89.
13. Baxter RD, Madhok RM. A case of arm swelling and muscle Wii-knees. *Scott Med J*. 2011;56:236.
14. Yohannan SK, Tufaro PA, Hunter H, et al. The utilization of Nintendo® Wii™ during burn rehabilitation: a pilot study. *J Burn Care Res*. 2012;33:36–45.
15. Sims J, Cosby N, Saliba EN, et al. Exergaming and static postural control in individuals with a history of lower limb injury. *J Athl Train*. 2013;48:314–325.