



Meniscus Injuries Alter the Kinematics of Knees With Anterior Cruciate Ligament Deficiency

Citation

Hosseini, Ali, Jing-Sheng Li, Thomas J. Gill, and Guoan Li. 2014. "Meniscus Injuries Alter the Kinematics of Knees With Anterior Cruciate Ligament Deficiency." *Orthopaedic Journal of Sports Medicine* 2 (8): 2325967114547346. doi:10.1177/2325967114547346. <http://dx.doi.org/10.1177/2325967114547346>.

Published Version

doi:10.1177/2325967114547346

Permanent link

<http://nrs.harvard.edu/urn-3:HUL.InstRepos:23845276>

Terms of Use

This article was downloaded from Harvard University's DASH repository, and is made available under the terms and conditions applicable to Other Posted Material, as set forth at <http://nrs.harvard.edu/urn-3:HUL.InstRepos:dash.current.terms-of-use#LAA>

Share Your Story

The Harvard community has made this article openly available.
Please share how this access benefits you. [Submit a story](#).

[Accessibility](#)

Meniscus Injuries Alter the Kinematics of Knees With Anterior Cruciate Ligament Deficiency

Ali Hosseini,* PhD, Jing-Sheng Li,*[†] MS, Thomas J. Gill IV,* MD, and Guoan Li,*[‡] PhD

Investigation performed at the Bioengineering Laboratory, Massachusetts General Hospital/ Harvard Medical School, Boston, Massachusetts, USA

Background: Most knee joint biomechanics studies have involved knees with an isolated anterior cruciate ligament (ACL) injury. However, a large portion of patients with injured ACLs have accompanied meniscus tearing. In this study, the in vivo alteration of knee biomechanics after tearing the ACL with or without combined medial or lateral meniscus tear was investigated during stair-ascending activity.

Hypothesis: The kinematic behavior of ACL-deficient knees changes with a combined medial or lateral meniscus tear.

Study Design: Controlled laboratory study.

Methods: Twenty-one patients with injured ACLs (contralateral side intact) were recruited before undergoing ACL reconstruction. Among these patients, 5 had isolated ACL injuries (group I), 8 had combined ACL and medial meniscus injuries (group II), and 8 had combined ACL and lateral meniscus injuries (group III). Bilateral magnetic resonance scans were obtained on each patient to construct 3-dimensional anatomic knee models. Both knees were then scanned during stair-climbing activity using a dual fluoroscopic imaging system. The knee kinematics during stair climbing were reproduced using a bone model image matching method. Anteroposterior and mediolateral translations and axial tibial rotation of the knee during stair ascent were then compared between the injured and intact contralateral knees of the patients.

Results: On average, injured knees in groups I and III showed more than 2 mm increased anterior tibial translation close to full knee extension. In group II, no statistically significant difference was observed between the injured and contralateral side in anteroposterior translation. Near full extension, in groups I and III, injured knees had less than 1 mm of increased medial tibial translation compared with the contralateral side, whereas in group II, a 1.0-mm increase in lateral tibial shift was observed in the injured knees. With regard to axial tibial rotation, group I showed an increased external tibial rotation (approximately 5°), group II had little variation, whereas group III had increased internal tibial rotation (approximately 3°).

Conclusion: The results of this study demonstrate that a combined ACL/meniscus injury could alter the kinematics of ACL-injured knees in a different way compared with knees with isolated ACL tears, depending on the pattern of the meniscus tear. Considering the varying effect of meniscus injuries on knee joint kinematics, future studies might focus on specific treatment of patients with combined ACL and meniscus injuries to protect the joint from abnormal kinematics and subsequent postoperative cartilage degeneration.

Keywords: anterior cruciate ligament (ACL); ACL deficiency; meniscus injury; isolated ACL injury; medial meniscus injury; lateral meniscus injury; kinematics; fluoroscopy

[‡] Address correspondence to Guoan Li, PhD, Bioengineering Laboratory, Massachusetts General Hospital/Harvard Medical School, 55 Fruit Street, GRJ 1215, Boston, MA 02114, USA (e-mail: gli1@partners.org).

*Department of Orthopaedic Surgery, Bioengineering Laboratory, Massachusetts General Hospital and Harvard Medical School, Boston, Massachusetts, USA.

[†] College of Health and Rehabilitation Sciences, Boston University, Boston, Massachusetts, USA.

One or more of the authors has declared the following potential conflict of interest or source of funding: Financial support for this study was received from the National Institutes of Health (NIH) (Grant No. R01 AR055612).

The Orthopaedic Journal of Sports Medicine, 2(8), 2325967114547346

DOI: 10.1177/2325967114547346

© The Author(s) 2014

It is well known that anterior cruciate ligament (ACL) injury alters the kinematics of the knee joint.^{1,4,9,17,19} ACL-deficient knees tend to have more anterior tibial translation both under passive clinical examination and during physiologic activities.^{1,17} Increased medial tibial translation and internal tibial rotation are also associated with ACL deficiency.⁴ These changes in the kinematics of the tibiofemoral joint result in alteration in the articular cartilage contact behavior with a shift of contact points to a thinner cartilage zone, increased cartilage deformation, and decreased cartilage contact area.²⁶ ACL deficiency and the resultant knee joint instability have been reported to be clinically associated with increased incidence of joint degeneration,^{7,24} with faster progression of

osteoarthritis.¹³ Long-term joint degeneration has been observed in up to 62% of patients who have been surgically treated with ACL reconstruction.¹⁴

ACL injuries are commonly combined with other soft tissue injuries, such as collateral ligament injuries and meniscus tears. In the United States, approximately 40% to 80% of ACL injuries are combined with menisci injuries.^{6,10,23,27} Recent Swedish National Knee Ligament Registry data showed 40% of ACL ruptures were combined with menisci injuries.² Although contemporary ACL reconstructions are successful in restoration of anteroposterior stability of the knee,²⁵ the effect of combined injuries to the meniscus on the function of the knee joint is not well understood.³ Most research has investigated knee biomechanics with an isolated ACL injury only. Recently, in 2 independent studies of stair ascent in ACL-deficient patients, conflicting data on tibial rotation have been reported. Gao et al⁸ measured increased internal tibial rotation after ACL deficiency, whereas an increased external rotation was shown by Kozánek et al.¹⁵ Different injury patterns in other soft tissues besides the ACL in those studies might be a factor for the variation in measured kinematics.

In this study, the *in vivo* alteration of knee biomechanics after the ACL injury with or without combined medial or lateral meniscus tear was investigated. Stair-ascending activity was chosen since it is a demanding physiological activity for ACL-deficient patients. We hypothesized that the kinematic behavior of ACL-deficient knees changes with a combined medial or lateral meniscus tear.

METHODS

Twenty-one patients with injured ACLs and their contralateral knee intact were sequentially recruited before undergoing ACL reconstruction. Institutional review board approval was obtained. Among these patients, 5 had isolated ACL injuries (group I), 8 had combined ACL and medial meniscus injuries (group II), and 8 had combined ACL and lateral meniscus injuries (group III). Medial and/or lateral meniscus injuries were confirmed later during arthroscopic ACL reconstruction. The average period of time from injury to time of analysis was 2.2, 43.2,[§] and 6.2 months, respectively. No patient had participated in any rehabilitation program. All patients had a positive Lachman test during clinical evaluation. No patient had any symptoms of joint degeneration (pain, cartilage wear, etc). Detailed demographic data on participation subjects is presented in Table 1. Bilateral magnetic resonance imaging scans were obtained in both sagittal and coronal planes on each patient using a 3.0-T magnetic resonance scanner (Magnetom Trio; Siemens), with an image size of 160 × 160 mm and image resolution of 512 × 512 pixels. The images were imported into modeling software (Rhino; Robert McNeel & Associates) to construct 3-dimensional models of the tibia, femur, fibula, and patella.^{12,16}

The patients' knees were then scanned during stair-ascending activity (Figure 1) using a dual fluoroscopic imaging system. This system consists of 2 fluoroscopes (BV Pulsera; Philips) with image intensifiers positioned orthogonally relative to each other. The fluoroscopes were synchronized and set to take images in 30 Hz with an 8-ms pulse width (beam current, 5 mA; beam energy, 50 kVp). The patient was asked to stand on both legs in the field of view of both fluoroscopes and ascend a step in front of them. Laser-positioning devices, attached to the fluoroscopes, helped align the target knee within the field of view of the fluoroscopes during the activity. The activity was recorded from heel strike to full extension for both injured and healthy contralateral legs. The order of activities was randomly chosen by the patient. To minimize the amount of radiation exposure, the subjects were trained to first practice this activity 5 times, followed by recording 1 trial for each leg.

Next, the kinematics of the tibiofemoral joints were reproduced using a bone model image matching method.^{15,18} The paired images were imported into Rhinoceros software and placed in the calibrated planes that simulate the image intensifiers of the actual fluoroscopes.¹⁸ Corresponding virtual x-ray sources were created to reproduce the orientation of the fluoroscopes during the actual experiment. The 3-dimensional tibial and femoral models were imported into the virtual dual fluoroscopic system and manipulated independently to match the projections of the bony models to the outlined silhouettes of bones on a selected pair of fluoroscopic images captured during the experiment. This process was repeated at each 10% of the activity from the beginning (heel strike) to the end (full knee extension) of the stair-ascending activity.

A previously established coordinate system was used to measure the knee joint kinematics⁴ (Figure 2). Tibial translations (anteroposterior, mediolateral) and axial tibial rotation of the knee were measured in this study. The changes in the kinematics of the ACL-injured knee relative to the intact contralateral knee of each patient were calculated and compared among the 3 groups of patients (isolated ACL-injured, combined ACL and medial meniscus injuries, and combined ACL and lateral meniscus injuries).

The accuracy of the above procedure for reproducing knee joint kinematics has been extensively evaluated.^{4,18} Using standard geometries, the system has an accuracy of 0.1 mm in translation and 0.1° in rotation.¹⁸ Using cadaveric human knee specimens, the system has an accuracy of 0.1 mm in translation and a repeatability of 0.3° in rotation.⁴ A paired *t* test was used to compare the tibiofemoral kinematic changes of the ACL-injured knees relative to ACL-intact knees within each selected group of patients. In addition, analysis of variance (ANOVA) was used to compare the tibiofemoral kinematic changes of the ACL-injured relative to ACL-intact knees between the 3 groups of patients. The kinematic variables (anteroposterior translation, mediolateral translation, and axial rotation) were considered as dependent variables. Injury status was considered as the

[§]Group II had 2 patients with a >10-year time gap between injury and experiment.

TABLE 1
Patient Demographics^a

		Age, y	Sex	Height, cm	Weight, kg	BMI, kg/m ²	Injured Leg	Meniscal Injury		Time Between Injury and Experiment, mo	Step-up Time, s	
								Injury Side	Type and Location		Control	Injured
Group I	1	18	M	175	73	23.6	R	—	—	3.4	0.9	0.7
	2	32	F	165	72	26.3	R	—	—	1.2	0.8	1.0
	3	31	F	163	64	24.1	L	—	—	2.0	0.6	0.6
	4	34	M	178	86	27.3	L	—	—	3.5	1.2	1.3
	5	20	F	173	68	22.8	R	—	—	1.1	0.8	0.5
	Mean (SD)	27.0 (7.4)	2M/3F	171 (7)	72 (9)	24.8 (1.9)	3R/2L			2.2 (1.1)	0.9 (0.2)	0.8 (0.3)
Group II	1	44	M	173	86	28.9	L	Med	Small complex tear, middle horn	NA	0.6	0.5
	2	45	M	193	114	30.5	R	Med	Small oblique tear, posterior horn	2.1	0.7	0.9
	3	23	M	180	84	25.8	R	Med	Bucket-handle tear	3.1	0.7	0.8
	4	34	M	178	73	23.0	L	Med	Longitudinal tear, posterior horn	3.9	0.6	0.9
	5	44	F	164	61	22.7	R	Med	Displaced bucket-handle complex tear	141.0	0.9	0.7
	6	43	M	173	82	27.4	L	Med	Medial meniscus tear, posterior horn	1.7	1.1	0.9
	7	42	F	160	91	35.5	R	Med	Longitudinal tear, posterior horn	138.6	0.6	0.7
	8	42	M	185	114	33.3	R	Med	Complex tear	11.8	0.6	0.7
	Mean (SD)	39.6 (7.5)	6M/2F	176 (11)	88 (18)	28.4 (4.6)	5R/3L			43.2 (66.1)	0.7 (0.2)	0.8 (0.1)
Group III	1	21	M	170	73	25.1	L	Lat	Longitudinal tear, posterior horn	8.6	0.8	1.0
	2	38	M	183	89	26.5	R	Lat	Longitudinal tear, posterior horn	5.2	0.6	0.7
	3	59	M	185	89	25.8	R	Lat	Radial tear, middle horn	3.8	0.9	0.6
	4	31	F	170	73	25.1	L	Lat	Complex tear, middle and posterior horn	1.3	1.0	1.0
	5	32	M	175	73	23.6	R	Lat	Short oblique tear, along the posterior root and posterior horn	0.4	0.7	0.6
	6	27	F	163	68	25.8	L	Lat	Flap tear, posterior horn	1.6	0.8	1.0
	7	43	F	165	82	30.0	R	Lat	Complex tear with a radial component, middle horn	1.9	0.7	0.7
	8	41	M	189	125	34.9	R	Lat	Complex tear, posterior horn	26.7	0.5	0.5
	Mean (SD)	36.5 (11.7)	5M/3F	175 (10)	84 (18)	27.1 (3.6)	5R/3L			6.2 (8.7)	0.8 (0.1)	0.8 (0.2)

^aGroup I—isolated ACL deficiency; group II—combined ACL and medial meniscus injuries; group III—combined ACL and lateral meniscus injuries. ACL, anterior cruciate ligament; BMI, body mass index; F, female; L, left; Lat, lateral; M, male; Med, medial; R, right.

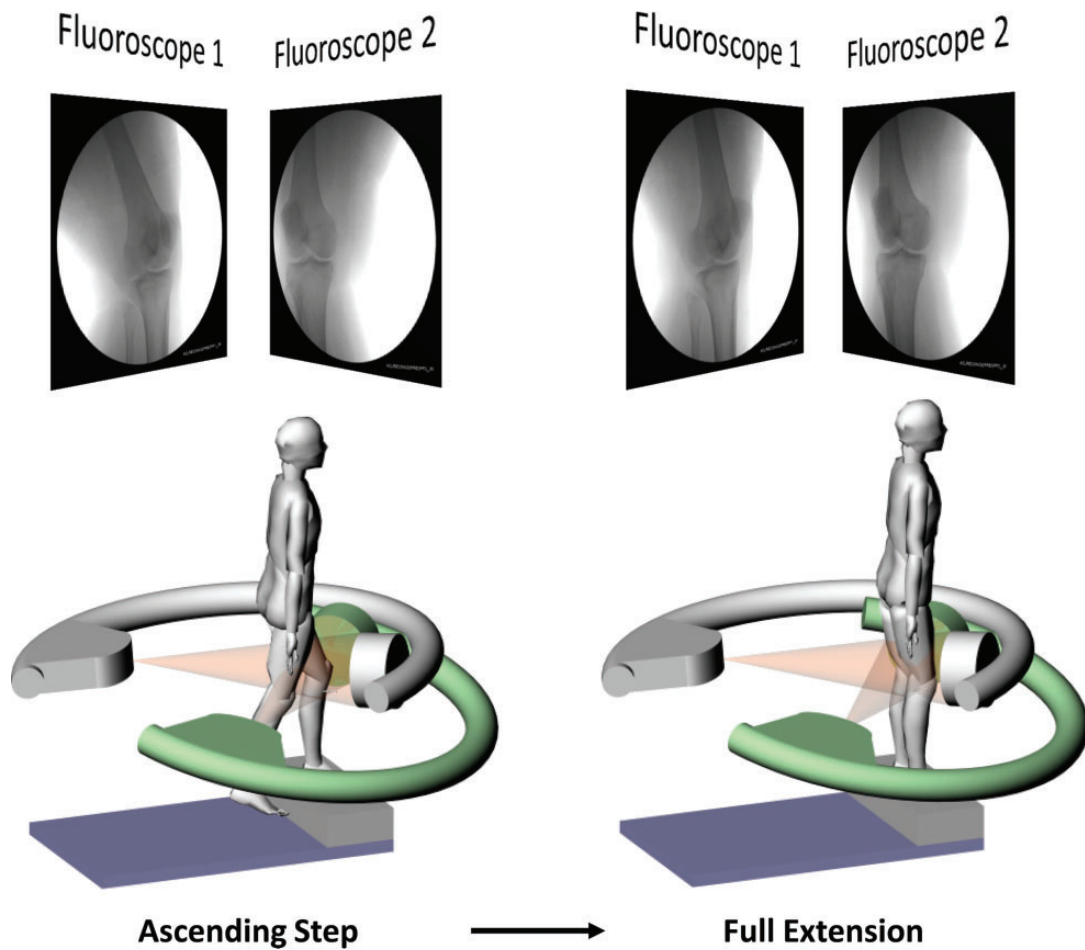


Figure 1. Schematics of the dual fluoroscopic imaging system (DFIS) with a patient performing stair-ascending exercise and the corresponding pair of fluoroscopic images.

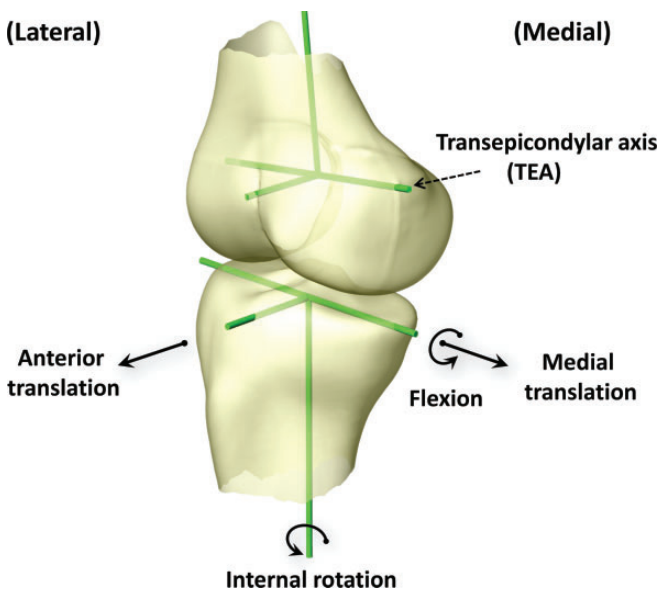


Figure 2. Definition of tibiofemoral coordinate systems.

categorical variable. Level of statistical significance was set at $P < .05$. When a statistically significant difference was detected by the ANOVA test, a post hoc Newman-Keuls test was performed to provide specific information on which means were significantly different. The statistical analysis was performed using Statistica software (Statistica; Statsoft).

RESULTS

The changes in the kinematics of the ACL-injured knees relative to the intact contralateral knees are presented in Table 2 for the second half of stair climbing (50% to 100% of the activity, when the knee was extended from approximately 30° to full extension). The ACL is known to be functional in this range of knee flexion. The step-up time is shown in Table 1 as well. In general, the kinematics of the joints with or without meniscus injuries was different.

Anteroposterior Translation

In the isolated ACL-injured group (group I), an increase in anterior tibial translation was observed in the ACL-injured

TABLE 2
Changes in the Kinematics of ACL-Injured Knees Relative to Their Contralateral Intact Knees^a

		Anteroposterior Translation, mm ^b						Mediolateral Translation, mm ^c						Axial Tibial Rotation, deg ^d					
		50%	60%	70%	80%	90%	100%	50%	60%	70%	80%	90%	100%	50%	60%	70%	80%	90%	100%
Group I	1	-1.2	2.4	4.4	3.6	2.2	-0.1	1.2	0.6	-3.4	-1.1	0.7	-0.5	-2.9	-2.5	-8.6	-9.6	-7.3	-6.8
	2	-0.5	-0.5	1.4	2.3	2.8	2.5	0.3	-0.8	-1.4	-1.0	0.6	1.0	-4.3	-3.9	-6.9	-7.3	-4.6	-10.0
	3	0.9	0.3	0.6	0.4	0.1	-0.5	0.3	0.5	1.5	1.6	2.2	3.4	-3.4	-1.7	0.4	-0.1	0.1	0.9
	4	4.4	2.5	2.1	4.0	1.9	3.0	-1.3	-0.8	-1.5	-1.6	0.1	-0.7	-6.8	-4.0	-1.4	-1.0	-3.2	-6.5
	5	-3.0	-3.3	-0.3	2.3	4.4	6.6	2.6	0.9	0.0	0.9	0.6	0.4	-7.9	-10.6	-9.3	-9.0	-7.5	-2.4
	Mean (SD)	0.1 (2.8)	0.3 (2.4)	1.6 (1.8)	2.5 (1.4)	2.3 (1.6)	2.3 (2.9)	0.6 (1.4)	0.1 (0.8)	-1.0 (1.8)	-0.2 (1.4)	0.8 (0.8)	0.7 (1.6)	-5.1 (2.2)	-4.5 (3.5)	-5.2 (4.4)	-5.4 (4.5)	-4.5 (3.2)	-5.0 (4.2)
Group II	1	3.6	1.1	1.8	1.5	-0.8	-2.1	-2.8	-3.1	-2.2	-2.0	-2.9	-3.1	-3.6	-2.8	-7.3	-6.3	0.4	2.4
	2	0.4	0.4	0.0	-2.6	-2.6	-1.7	1.2	1.0	0.8	0.5	0.0	-0.6	-8.0	-6.9	-10.4	-11.4	-14.5	-14.4
	3	0.1	0.9	2.3	0.5	-0.4	0.2	0.9	-0.7	0.2	0.1	-0.3	-1.9	-1.1	2.7	0.9	0.2	-2.6	-0.9
	4	-6.3	-6.4	-5.7	-0.9	0.6	1.5	1.0	3.1	0.9	3.0	3.4	4.3	0.7	-1.9	-3.4	-2.1	-4.9	-7.2
	5	3.4	3.9	3.2	3.2	3.8	2.4	-1.6	-1.9	-0.5	-0.8	-0.9	-1.2	-2.4	-3.5	-9.6	-11.1	-10.8	-13.8
	6	0.4	1.4	2.6	1.9	1.1	0.4	0.2	0.5	0.4	1.0	1.4	1.4	-7.7	-6.7	-8.1	-9.9	-10.1	-8.5
	7	2.1	0.0	0.1	-1.9	-1.2	2.2	0.6	0.4	-0.5	0.0	-1.0	-2.8	18.6	19.7	18.7	15.9	18.8	18.6
	8	-2.8	-2.7	-4.2	-3.8	0.3	-1.8	1.0	0.4	-0.2	-0.7	-2.0	-4.5	2.8	4.6	2.1	4.4	8.9	14.2
	Mean (SD)	0.1 (3.3)	-0.2 (3.1)	0.0 (3.3)	-0.3 (2.4)	0.1 (1.9)	0.1 (1.8)	0.1 (1.5)	0.0 (1.9)	-0.1 (1.0)	0.1 (1.5)	-0.3 (2.0)	-1.1 (2.8)	-0.1 (8.4)	0.7 (8.7)	-2.1 (9.6)	-2.5 (9.4)	-1.9 (11.1)	-1.2 (12.3)
Group III	1	-0.8	0.2	1.0	1.5	2.1	3.0	0.5	0.5	0.6	-0.1	-0.7	-0.1	-3.7	-4.0	-2.8	-0.1	2.6	0.8
	2	0.7	-0.8	0.3	1.9	3.3	5.1	-0.4	-1.8	-1.9	-1.1	-0.5	-1.2	-1.0	-0.8	0.4	0.4	1.2	2.0
	3	-0.8	0.7	-0.1	2.6	4.1	4.7	0.6	0.8	1.2	1.4	2.3	3.3	1.0	0.1	5.3	6.7	3.6	0.9
	4	-2.2	-3.1	-5.0	-2.8	-7.6	-5.6	-0.8	-0.4	-1.7	-0.5	0.1	1.4	4.6	4.2	5.0	4.5	5.2	11.2
	5	-4.7	-2.0	-0.3	1.0	1.7	3.6	-0.9	0.4	2.3	-1.9	-0.1	-2.7	2.8	1.7	1.7	7.2	9.8	9.3
	6	6.2	5.5	2.9	1.1	0.7	1.9	1.5	0.2	-1.1	-1.3	-0.6	0.6	13.9	14.0	5.4	1.1	3.3	5.5
	7	1.4	0.8	1.4	1.5	0.5	3.5	-0.9	-1.3	-0.3	-0.1	-0.6	0.1	3.3	3.0	2.8	-0.9	2.2	1.6
	8	7.1	7.3	8.3	10.0	10.9	11.7	-1.5	-2.7	-1.8	-0.3	0.6	1.5	-1.5	-2.0	-1.8	-2.9	-5.5	-7.3
	Mean (SD)	0.9 (4.0)	1.1 (3.6)	1.1 (3.7)	2.1 (3.6)	2.0 (5.1)	3.5 (4.7)	-0.2 (1.0)	-0.5 (1.3)	-0.3 (1.6)	-0.5 (1.0)	0.1 (1.0)	0.4 (1.8)	2.4 (5.4)	2.0 (5.5)	2.0 (3.2)	2.0 (3.7)	2.8 (4.3)	3.0 (5.8)

^aGroup I—isolated ACL deficiency; group II—combined ACL and medial meniscus injuries; group III—combined ACL and lateral meniscus injuries.

^bPositive value indicates anterior translation.

^cPositive value indicates medial translation.

^dPositive value indicates internal rotation.

knee compared with the intact contralateral knee (Figure 3). At 90% and 100% of the ascent activity, the average anterior tibial translation increased in injured knees compared with their contralateral side by 2.3 ± 1.6 mm ($P = .019$) and 2.3 ± 2.9 mm ($P = .144$), respectively. For group II patients, the average change of anterior tibial translation was less than 0.5 mm along the motion path ($P > .05$) compared with their contralateral side. For group III patients, the anterior tibial translation of the ACL-injured knees increased as the knee was getting close to full extension. At 90% and 100% of the stair-ascending activity, the anterior tibial translation increased by 2.0 ± 5.1 mm ($P = .313$) and 3.5 ± 4.7 mm ($P = .076$), respectively. Comparing the changes of anterior tibial translation of the 3 groups of patients, no statistically significant difference was detected along the flexion path.

Mediolateral Translation

Different trends of changes in the mediolateral tibial translation were observed in ACL-injured knees in the 3 patient groups (Figure 4). At 90% and 100% of the stair-ascending activity, the injured knees of group I showed an increase in the medial tibial translation by

0.8 ± 0.8 mm ($P = .110$) and 0.7 ± 1.6 mm ($P = .487$) compared with the contralateral side, respectively. For group II patients, the lateral tibial translation of the ACL-injured knees increased as the knee approached full extension. At 90% and 100% of the activity, the tibia of injured knees translated more laterally compared with their corresponding contralateral knees by 0.3 ± 2.0 mm ($P = .078$) and 1.1 ± 2.8 mm ($P = .019$), respectively. For group III patients, the average change of mediolateral tibial translation was less than 0.5 mm along the motion path ($P > .05$). Comparing the changes of mediolateral tibial translation of the injured knees with respect to the intact knees in 3 groups of patients, a statistically significant difference was detected at 90% of the activity between groups I and II ($P = .02$; knee flexion, 6.4°), as well as at 100% of the activity between group III and the other 2 groups ($P = .017$; knee flexion, 3°).

Internal/External Rotation

The changes in the axial tibial rotation between injured and intact contralateral knees after ACL injury showed

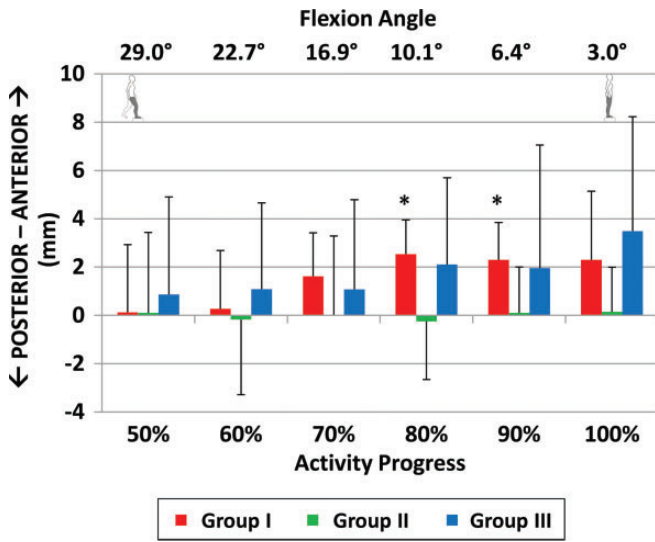


Figure 3. Anteroposterior shift of the tibia with respect to the femur in anterior cruciate ligament (ACL)-deficient patients with isolated ACL deficiency (group I), combined ACL and medial meniscus injuries (group II), and combined ACL and lateral meniscus injuries (group III). *Statistically significant difference ($P < .05$).

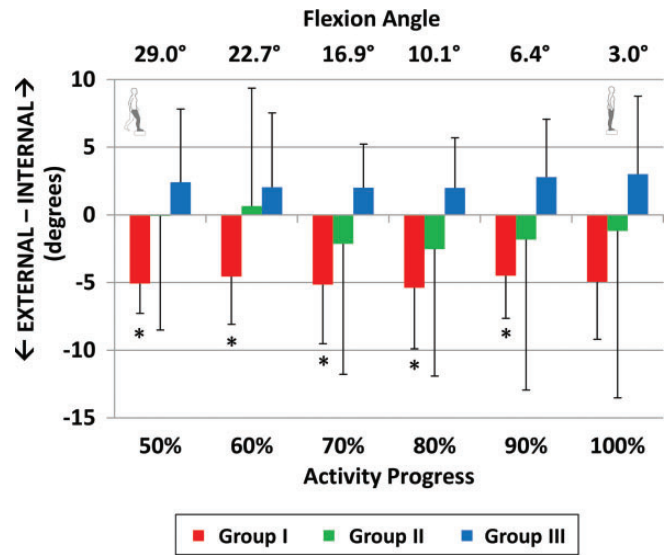


Figure 5. Axial tibial rotation in anterior cruciate ligament (ACL)-deficient patients with isolated ACL deficiency (group I), combined ACL and medial meniscus injuries (group II), and combined ACL and lateral meniscus injuries (group III). *Statistically significant difference ($P < .05$).

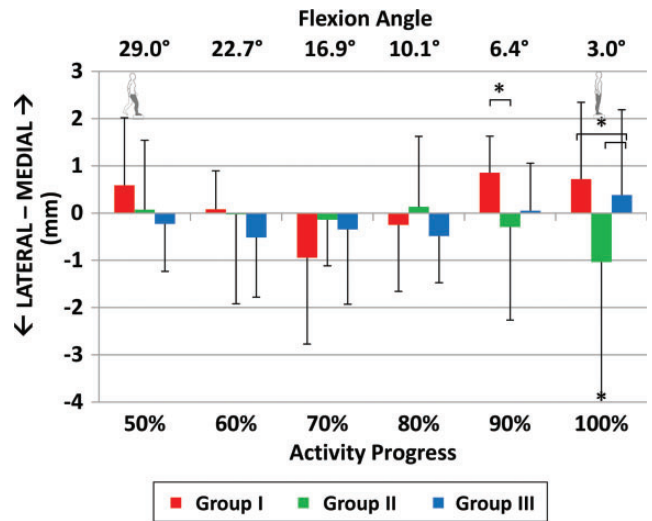


Figure 4. Mediolateral shift of the tibia with respect to the femur in anterior cruciate ligament (ACL)-deficient patients with isolated ACL deficiency (group I), combined ACL and medial meniscus injuries (group II), and combined ACL and lateral meniscus injuries (group III). *Statistically significant difference ($P < .05$).

different trends among the 3 groups of patients (Figure 5). At 90% and 100% of the ascent activity, group I showed an increase in external tibial rotation by $4.5^\circ \pm 3.2^\circ$ ($P = .034$) and $5.0^\circ \pm 4.2^\circ$ ($P = .129$), respectively. In group II, the average external tibial rotation of the injured knees increased by less than 2.5° along the flexion path ($P > .05$). However,

in group III, at 90% and 100% of the ascent activity, the axial tibial rotation of injured knees increased internally by $2.8^\circ \pm 4.3^\circ$ ($P = .107$) and $3.0^\circ \pm 5.8^\circ$ ($P = .184$), respectively. Comparing the changes of axial tibial rotation of the 3 groups of patients, no statistically significant difference was detected along the flexion path.

DISCUSSION

The changes in the tibiofemoral joint kinematics (including anteroposterior and mediolateral tibial translations and axial tibial rotation) in patients with isolated ACL deficiency and combined ACL and medial or lateral meniscus injuries were investigated. Altered kinematics were defined as the changes in the kinematics of the injured knee relative to the intact contralateral knee of the same patient.

In general, ACL-deficient knees showed more anterior tibial shift toward full extension, except for patients with a combined medial meniscus tear. Controlling tibial translation in the anterior direction is the primary function of the ACL, as increased anterior tibial translation in ACL-deficient knees was observed in both in vitro^{1,17} and in vivo⁴ investigations. This difference was reported to be significant only during the terminal stance phase,^{1,15} with an average difference of 2.5 mm in anteroposterior translation between ACL-deficient and ACL-intact groups. Interestingly, patients with combined ACL and medial meniscus injuries did not show increased anterior tibial shift while ascending stairs in our study, although a positive Lachman test was seen in all patients. The reason for this finding is yet to be determined and warrants future investigation.

In different groups of patients, the mediolateral tibial translation was not similar, especially close to full extension. Patients with isolated ACL deficiency and patients with combined ACL and lateral meniscus injuries were associated with medial tibial shift. However, patients with combined ACL and medial meniscus injuries had lateral tibial shift close to full extension. These patterns imply that in the mediolateral direction, the femoral condyles tend to shift toward the injured meniscus in the terminal phase of stair ascent. Kozánek et al¹⁵ reported medial tibial shift in ACL-deficient patients compared with their ACL-intact sides when patients performed a similar stair step-up activity (19 males, 11 females; mean age, 36 years; mean time from injury to test, 3.3 months). Those patients were reported not to have other injuries to the soft tissue structures of the knee joint except the ACL and meniscus. However, the side of meniscal injury was not reported in their study, which made a direct comparison with other studies difficult. Results of our current study revealed that the presence of a medial or lateral meniscus tear could have a role in the kinematics of the injured knee. Therefore, it is important to indicate the specific meniscus injuries when reporting kinematics of ACL-deficient knees.

Both in vivo^{4,9,19} and in vitro simulated muscle loading experiments¹⁷ have reported increased internal tibial rotation in the presence of ACL deficiency. However, in axial rotation, only the results of those patients with a combined lateral meniscus tear were in agreement with previous studies. On the other hand, groups I and II showed increased external tibial rotation in deficient knees during stair ascent. Interestingly, a similar discrepancy of results exists in the literature as well. In 2 recent independent studies of ACL-deficient patients, opposite observations of increased internal tibial rotation⁸ and external tibial rotation¹⁵ during stair ascent were reported. Even though “extensive” damage to the meniscus was one of the exclusion criteria in the study by Gao et al⁸ (10 males, 2 females each in the ACL-intact group and ACL-deficient group; mean age, 24 years; mean time from injury to test, 3 months),⁸ neither of the studies mentioned details of meniscus injuries in their patient groups (side, existence, etc). Our results on different patterns of axial tibial rotation indicate that meniscus injury patterns are critical factors in knee rotation after ACL injuries.

In the literature, meniscus injury is associated with joint degeneration^{20,22} and a high incidence of medial osteoarthritis.^{5,11,21} However, in most previous studies, the side of meniscus injury is not reported. Different kinematic results from similar experimental setups show that accurate description of the injury pattern is required to interpret study outcomes. The results of this study supported our initial hypothesis that kinematic response of ACL-deficient knees could be dependent on the presence and side of meniscus injuries as well. In contemporary ACL reconstruction surgeries, all surgical techniques have been developed based on the investigation of isolated ACL injury, regardless of meniscus injuries. The data of our investigation suggest that further research may be necessary on different surgical approaches for restoration of the knee kinematics when ACL deficiency is combined with meniscus injuries.

The results of this study should be interpreted in the context of its limitations. We acquired data from only 1 functional activity (ascending stairs). Other physiological activities, such as gait and dynamic flexion-extension, should be considered before generalizing these results since different activities may cause different in vivo joint loadings. Except medial or lateral side, the location of the meniscus injury was not considered in this study (due to our small sample size). All patients with meniscus injuries were treated with partial meniscectomy later during ACL reconstruction, except 1 patient who was treated with meniscus repair. Samples of the second group are not uniform due to longer mean time from injury to analysis. Finally, the sample size of each group was relatively small and did not have sufficient power to detect the kinematic differences among the 3 groups of patients. Recruiting patients will be continued in our future studies.

To summarize, this study investigated the changes of tibiofemoral kinematics of ACL-deficient knees with or without an accompanied medial or lateral meniscus injury during stair ascent using a dual fluoroscopic imaging system. The data revealed that a combined ACL and meniscus injury could alter the tibial translation and axial rotation of the ACL-injured knee, depending on the injury side of the meniscus. Considering the varying effect of meniscus injuries on knee joint kinematics, future studies should focus on specific treatments for patients with combined ACL and meniscus injuries to restore normal knee joint function and prevent postoperative cartilage degeneration.

REFERENCES

1. Ahmed AM, McLean C. In vitro measurement of the restraining role of the anterior cruciate ligament during walking and stair ascent. *J Biomech Eng.* 2002;124:768-779.
2. Andernord D, Bjornsson H, Petzold M, et al. Surgical predictors of early revision surgery after anterior cruciate ligament reconstruction: results from the Swedish National Knee Ligament Register on 13,102 patients. *Am J Sports Med.* 2014;42:1574-1582.
3. Chhadia AM, Inacio MC, Maletis GB, Csintalan RP, Davis BR, Funahashi TT. Are meniscus and cartilage injuries related to time to anterior cruciate ligament reconstruction? *Am J Sports Med.* 2011; 39:1894-1899.
4. DeFrate LE, Papannagari R, Gill TJ, Moses JM, Pathare NP, Li G. The 6 degrees of freedom kinematics of the knee after anterior cruciate ligament deficiency: an in vivo imaging analysis. *Am J Sports Med.* 2006; 34:1240-1246.
5. Fairclough JA, Graham GP, Dent CM. Radiological sign of chronic anterior cruciate ligament deficiency. *Injury.* 1990;21:401-402.
6. Fetzer GB, Spindler KP, Amendola A, et al. Potential market for new meniscus repair strategies: evaluation of the MOON cohort. *J Knee Surg.* 2009;22:180-186.
7. Fithian DC, Paxton LW, Goltz DH. Fate of the anterior cruciate ligament-injured knee. *Orthop Clin North Am.* 2002;33:621-636, v.
8. Gao B, Cordova ML, Zheng NN. Three-dimensional joint kinematics of ACL-deficient and ACL-reconstructed knees during stair ascent and descent. *Hum Mov Sci.* 2012;31:222-235.
9. Georgoulis AD, Papadonikolakis A, Papageorgiou CD, Mitsou A, Stergiou N. Three-dimensional tibiofemoral kinematics of the anterior cruciate ligament-deficient and reconstructed knee during walking. *Am J Sports Med.* 2003;31:75-79.
10. Granan LP, Inacio MC, Maletis GB, Funahashi TT, Engebretsen L. Sport-specific injury pattern recorded during anterior cruciate ligament reconstruction. *Am J Sports Med.* 2013;41:2814-2818.

11. Hill CL, Seo GS, Gale D, Totterman S, Gale ME, Felson DT. Cruciate ligament integrity in osteoarthritis of the knee. *Arthritis Rheum*. 2005; 52:794-799.
12. Hosseini A, Gill TJ, Li G. In vivo anterior cruciate ligament elongation in response to axial tibial loads. *J Orthop Sci*. 2009;14:298-306.
13. Kannus P, Jarvinen M. Posttraumatic anterior cruciate ligament insufficiency as a cause of osteoarthritis in a knee joint. *Clin Rheumatol*. 1989;8:251-260.
14. Keays SL, Bullock-Saxton JE, Keays AC, Newcombe PA, Bullock MI. A 6-year follow-up of the effect of graft site on strength, stability, range of motion, function, and joint degeneration after anterior cruciate ligament reconstruction: patellar tendon versus semitendinosus and gracilis tendon graft. *Am J Sports Med*. 2007;35:729-739.
15. Kozánek M, Hosseini A, de Velde SK, et al. Kinematic evaluation of the step-up exercise in anterior cruciate ligament deficiency. *Clin Biomech (Bristol, Avon)*. 2011;26:950-954.
16. Li G, DeFrate LE, Rubash HE, Gill TJ. In vivo kinematics of the ACL during weight-bearing knee flexion. *J Orthop Res*. 2005;23:340-344.
17. Li G, Papanagari R, DeFrate LE, Yoo JD, Park SE, Gill TJ. Comparison of the ACL and ACL graft forces before and after ACL reconstruction: an in-vitro robotic investigation. *Acta Orthop*. 2006;77:267-274.
18. Li G, Wuerz TH, DeFrate LE. Feasibility of using orthogonal fluoroscopic images to measure in vivo joint kinematics. *J Biomech Eng*. 2004;126:314-318.
19. Logan M, Dunstan E, Robinson J, Williams A, Gedroyc W, Freeman M. Tibiofemoral kinematics of the anterior cruciate ligament (ACL)-deficient weightbearing, living knee employing vertical access open "interventional" multiple resonance imaging. *Am J Sports Med*. 2004;32:720-726.
20. Magnussen RA, Mansour AA, Carey JL, Spindler KP. Meniscus status at anterior cruciate ligament reconstruction associated with radiographic signs of osteoarthritis at 5- to 10-year follow-up: a systematic review. *J Knee Surg*. 2009;22:347-357.
21. Murrell GA, Maddali S, Horovitz L, Oakley SP, Warren RF. The effects of time course after anterior cruciate ligament injury in correlation with meniscal and cartilage loss. *Am J Sports Med*. 2001;29:9-14.
22. Neuman P, Englund M, Kostogiannis I, Friden T, Roos H, Dahlberg LE. Prevalence of tibiofemoral osteoarthritis 15 years after nonoperative treatment of anterior cruciate ligament injury: a prospective cohort study. *Am J Sports Med*. 2008;36:1717-1725.
23. Noyes FR, Barber-Westin SD. Treatment of meniscus tears during anterior cruciate ligament reconstruction. *Arthroscopy*. 2012;28: 123-130.
24. Roos H, Adalberth T, Dahlberg L, Lohmander LS. Osteoarthritis of the knee after injury to the anterior cruciate ligament or meniscus: the influence of time and age. *Osteoarthritis Cartilage*. 1995;3: 261-267.
25. Sim JA, Gadikota HR, Li JS, Li G, Gill TJ. Biomechanical evaluation of knee joint laxities and graft forces after anterior cruciate ligament reconstruction by anteromedial portal, outside-in, and transtibial techniques. *Am J Sports Med*. 2011;39:2604-2610.
26. Van de Velde SK, Bingham JT, Hosseini A, et al. Increased tibiofemoral cartilage contact deformation in patients with anterior cruciate ligament deficiency. *Arthritis Rheum*. 2009;60:3693-3702.
27. Wyatt RW, Inacio MC, Liddle KD, Maletis GB. Factors associated with meniscus repair in patients undergoing anterior cruciate ligament reconstruction. *Am J Sports Med*. 2013;41:2766-2771.