



Nerve Wrapping of the Sciatic Nerve With Acellular Dermal Matrix in Chronic Complete Proximal Hamstring Ruptures and Ischial Apophyseal Avulsion Fractures

Citation

Haus, Brian M., Danny Arora, Joseph Upton, and Lyle J. Micheli. 2016. "Nerve Wrapping of the Sciatic Nerve With Acellular Dermal Matrix in Chronic Complete Proximal Hamstring Ruptures and Ischial Apophyseal Avulsion Fractures." *Orthopaedic Journal of Sports Medicine* 4 (3): 2325967116638484. doi:10.1177/2325967116638484. <http://dx.doi.org/10.1177/2325967116638484>.

Published Version

doi:10.1177/2325967116638484

Permanent link

<http://nrs.harvard.edu/urn-3:HUL.InstRepos:26860109>

Terms of Use

This article was downloaded from Harvard University's DASH repository, and is made available under the terms and conditions applicable to Other Posted Material, as set forth at <http://nrs.harvard.edu/urn-3:HUL.InstRepos:dash.current.terms-of-use#LAA>

Share Your Story

The Harvard community has made this article openly available.
Please share how this access benefits you. [Submit a story](#).

[Accessibility](#)

Nerve Wrapping of the Sciatic Nerve With Acellular Dermal Matrix in Chronic Complete Proximal Hamstring Ruptures and Ischial Apophyseal Avulsion Fractures

Brian M. Haus,^{*†} MD, Danny Arora,[‡] MD, Joseph Upton,[§] MD, and Lyle J. Micheli,[§] MD
Investigation performed at Boston Children's Hospital, Boston, Massachusetts, USA

Background: Patients with chronic injuries of the proximal hamstring can develop significant impairment because of weakness of the hamstring muscles, sciatic nerve compression from scar formation, or myositis ossificans.

Purpose: To describe the surgical outcomes of patients with chronic injury of the proximal hamstrings who were treated with hamstring repair and sciatic neurolysis supplemented with nerve wrapping with acellular dermal matrix.

Study Design: Retrospective case series; Level of evidence, 4.

Methods: Fifteen consecutive patients with a diagnosis of chronic complete proximal hamstring rupture or chronic ischial tuberosity apophyseal avulsion fracture (mean age, 39.67 years; range, 14-69 years) were treated with proximal hamstring repair and sciatic neurolysis supplemented with nerve wrapping with acellular dermal matrix. Nine patients had preoperative sciatica, and 6 did not. Retrospective chart review recorded clinical outcomes measured by the degree of pain relief, the rate of return to activities, and associated postoperative complications.

Results: All 15 patients were followed in the postoperative period for an average of 16.6 months. Postoperatively, there were 4 cases of transient sciatic nerve neurapraxia. Four patients (26%) required postoperative betamethasone sodium phosphate (Celestone Soluspan) injectable suspension USP 6 mg/mL. Among the 9 patients with preoperative sciatica, 6 (66%) had a good or excellent outcome and were able to return to their respective activities/sports; 3 (33%) had persistent chronic pain. One of these had persistent sciatic neuropathy that required 2 surgical reexplorations and scar excision after development of recurrent extraneural scar formation. Among the 6 without preoperative sciatica, 100% had a good or excellent outcomes and 83% returned to their respective activities/sports. Better outcomes were observed in younger patients, as the 3 cases of persistent chronic sciatic pain were in patients older than 45 years.

Conclusion: This study suggests that when used as an adjunct to sciatic neurolysis, nerve wrapping with acellular dermal matrix can be a safe and effective method of treating younger patients with and preventing the development of sciatic neuropathic pain after chronic injury of the proximal hamstrings.

Keywords: hamstring avulsion; neurolysis; acellular dermal matrix

*Address correspondence to Brian M. Haus, MD, University of California–Davis Children's Hospital, Shriners Hospital for Children, Northern California, 4860 Y Street Suite 3800, Sacramento, CA 98817, USA (email: bhaus@ucdavis.edu).

†University of California–Davis Children's Hospital, Shriners Hospital for Children, Northern California, Sacramento, California, USA.

‡University of Toronto, Toronto, Ontario, Canada.

§Boston Children's Hospital, Harvard Medical School, Boston, Massachusetts, USA.

The authors declared that they have no conflicts of interest in the authorship and publication of this contribution.

The Orthopaedic Journal of Sports Medicine, 4(3), 2325967116638484

DOI: 10.1177/2325967116638484

© The Author(s) 2016

Injuries of the proximal hamstring are relatively common and occur after forceful eccentric contraction of the hamstring with the knee extended and the hip flexed.^{3,11,17} The injury most often presents as a sprain or partial tear involving 1 of the 3 proximal hamstrings. Complete tears of the proximal hamstring tendon origin, or apophyseal avulsion fractures of the ischial tuberosity, are less common injuries. Apophyseal avulsion fractures of the ischial tuberosity are seen in adolescent athletes, whereas complete tears of the proximal hamstring origin are seen in skeletally mature athletes.

While partial tears are usually treated nonoperatively,²⁰ complete tears of the proximal hamstring origin and displaced fractures of the ischial tuberosity require surgical management.^{9,21,25} Even though acute surgical

management of both injuries results in satisfactory outcomes,^{15,22} treatment of these injuries is often delayed. Patients with chronic injuries of the proximal hamstring can develop significant impairment due to weakness of the hamstring muscles, sciatic nerve compression from scar formation,^{5,20,24} or myositis ossificans.¹²

We present the results of a series of patients with chronic proximal hamstring injury who presented with chronic pain. These patients were treated with hamstring muscle repair, sciatic neurolysis, and nerve wrapping with acellular dermal matrix (AlloDerm; LifeCell). While acellular dermal matrix has been used for nerve wrapping elsewhere^{16,18,26} to help relieve pain from scarred nerves and to prevent recurrence of scar adhesions, this unique technique has not been previously employed for sciatic nerve compression in the setting of proximal hamstring injury.

METHODS

Institutional review board approval was obtained. A series of 15 consecutive patients with a diagnosis of chronic complete proximal hamstring rupture or chronic ischial tuberosity apophyseal avulsion fracture treated at the author's institution were identified. They were treated with repair and sciatic neurolysis, supplemented with nerve wrapping with acellular dermal matrix (AlloDerm). The procedure was performed simultaneously by the 2 senior authors. Inclusion criteria included the following: magnetic resonance imaging (MRI) confirmation of complete proximal hamstring tendon rupture or radiographic evidence of displaced ischial apophyseal avulsion fracture, direct repair of the avulsed tendon to the ischium or reduction of the avulsion fracture, and postoperative clinical follow-up for a minimum of 6 months. Chronic injury was defined as longer than 3 months since the time of injury.

Surgical intervention was recommended if (1) the patient could not return to their desired activities because of persistent weakness, pain, or both after nonoperative treatment or (2) when patients had symptoms associated with sciatic nerve compression without significant distal weakness.

The study group comprised 15 patients (7 females, 8 males) with proximal hamstring injuries. Twelve had a complete proximal hamstring tendon rupture, and 3 had an ischial tuberosity apophyseal avulsion fracture (Table 1). The mean age of our series at time of injury was 39.67 years (range, 14-69 years). There were multiple mechanisms of injury, ranging from competitive sports to tripping while walking, although each involved a violent mechanism with the knee extended and hip flexed. All patients treated had a chronic injury (≥ 3 months) that failed conservative measures of treatment (eg, physical therapy, various therapeutic modalities, nonsteroidal anti-inflammatory drugs, etc).

All patients (100%) complained of buttock pain made worse with sitting, and 60% of patients (9 of 15) had associated sciatica-like symptoms (numbness, shooting pain, and weakness radiating from the buttock down their leg). Of the 9 patients with preoperative sciatica,

all demonstrated pain during a straight-leg raise. A positive Tinel sign was noted in 3 of 9 patients. Four patients demonstrated scarring around the nerve on MRI, and 1 patient showed evidence of hamstring atrophy (Figure 1).

Surgical Technique

Broad-spectrum antibiotics (cephalosporin) were given preoperatively. The procedure was performed under general anesthesia with the patient in the prone position. The entire leg was draped free. The ischial tuberosity was palpated, and a transverse incision approximately 6 to 10 cm in length was created in the gluteal crease. The transverse incision, in comparison with the more commonly employed longitudinal incision, allows not only better cosmesis but also wider access to the ischial tuberosity and the insertion of the hamstring tendons.

Dissection was then performed through the subcutaneous layer to the gluteal fascia. A transverse incision was created to reveal the gluteal muscle, which was either split or approached infragluteally by retracting the muscle superiorly to provide access to the hamstrings. The hamstring fascia was subsequently incised with a transverse incision. A longitudinal incision was occasionally added to provide increased exposure to the hamstring tendons and the ischial tuberosity. At this point, the hamstring tendons and the ischial tuberosity could be visualized (Figure 2). Improved access can be obtained by placing a Hohmann retractor behind the ischial tuberosity. The sciatic nerve lies directly lateral and deep to the hamstring tendons and should be identified and retracted before proceeding with any manipulation and repair of the hamstring tendons or ischial tuberosity avulsion.

In some patients with chronic hamstring injury, the hamstrings tendons may be retracted, and the sciatic nerve may be difficult to identify, as it may be adherent to thick scarring and sometimes myositis ossificans (Figure 3).

Meticulous and often extensive dissection of the scar tissue should be initially performed around the ischial tuberosity and then extended distally to identify the hamstrings and the sciatic nerve. Although there is often significant scarring that needs to be resected (Figure 4), attention should be taken to not resect too much scarring around the hamstrings tendons to prevent significant shortening.

Once adequate resection was performed to allow better mobilization of the sciatic nerve, it was retracted and the repair of the hamstring tendons conducted. Easier reduction was facilitated by hip extension and knee flexion. The ischial tuberosity was first cleared of all remaining scar tissue and a Cobb elevator and rongeur used to create a bleeding surface for tendon healing. Repair was performed using 2 to 3 nonabsorbable suture anchors (DePuy Mitek) placed into the ischial tuberosity and then interwoven to the ruptured end of the hamstring tendons or avulsed fracture avulsion using a modified Mason-Allen stitch (Figure 4).

A more complete and meticulous neurolysis of the sciatic nerve is always necessary and usually performed after hamstring repair. Neurolysis began from an area of normal,

TABLE 1
Summary of Patients and Surgical Outcomes^a

Patient No.	Sex	Age, y	Injury Characteristics					Sciatica?	Time From Injury to Surgery, mo	Follow-up, mo	Complications	Pain Relief/Outcomes
			Type	Mechanism	Sport	Presentation						
1	F	42	Hamstring rupture	Hamstring curls	Gym	Buttock/ischial pain + sciatica	Yes	15	6	None	Excellent + return to sports	
2	F	52	Hamstring rupture	Fall on outstretched leg	Cycling	Sciatica, weakness + numbness	Yes	29	16	None	Excellent + return to cycling	
3	M	16	Hamstring avulsion	Running the bases	Baseball	Right buttock pain + sciatica	Yes	10	36	Transient sciatic nerve neurapraxia	Good, postop Celestone injections 2× + return to sports	
4	F	68	Hamstring rupture	Lunging forward with provocative contraction	Tennis	Pain, sciatica	Yes	3	33	Transient sciatic nerve neurapraxia	None, chronic pain, persistent sciatic neuropathy, reexploration with sciatic nerve release, reexploration with curettage of bursa, postop Celestone injections 3×, postop L2-3 bilateral medial branch block	
5	F	45	Hamstring rupture	Fall	None	Pain, sciatica	Yes	12	43	None	Fair, chronic sciatic pain, postop cortisone injections 3×	
6	F	56	Hamstring rupture	Fall	None	Pain, sciatica	Yes	27	39	None	Fair, chronic sciatic pain, postop cortisone injections 2×	
7	M	25	Hamstring rupture	Fall, jumping over fence	Jumping	Numbness + sciatica	Yes	5	15	Transient sciatic nerve neurapraxia	Good, mild dorsiflexion weakness + return to running	
8	M	14	Hamstring avulsion, nonunion	Slipped on ice	Hockey	Pain, sciatica	Yes	24	6	None	Good, return to sports	
9	F	15	Hamstring rupture	MVA trauma, peripelvic injury	Trauma	Pain, sciatica	Yes	32	6	None	Excellent + return to sports	
10	M	49	Hamstring rupture	Forced hip flexion	Water skiing	Mid-hamstring pain + weakness	No	21	11	Transient sciatic nerve neurapraxia	Good + no return to sports	
11	M	47	Hamstring rupture	Slipped and did splits	Badminton	Pain	No	3	6	None	Excellent + return to biking, swimming	
12	M	14	Hamstring avulsion	Hip hyperflexion	Soccer	Limp, difficulty running + pain	No	13	10.5	None	Excellent, + return to sports	
13	M	55	Hamstring rupture	Hip hyperflexion, slipped off ice cliff	Ice climbing	Left thigh pain, weakness	No	5	8	None	Excellent + return to sports	
14	F	49	Hamstring rupture	Hamstring stretching	None	Left posterior thigh pain	No	84	6	None	Excellent + return to activity	
15	F	48	Hamstring rupture	Pulling dog	Running	Unable to sit, pain	No	36	8	None	Good + return to running	

^aF, female; M, male; MVA, motor vehicle accident ; postop, postoperative.

unscarred nerve and then extended proximally or distally into the scarred area. The nerve was decompressed and carefully circumferentially neurolyzed (Figure 5). Care was taken to isolate the posterior femoral cutaneous nerve. Any large epineurial vessels were clipped. Multiple branching nerves and accompanying vessels and pedicles were

preserved. The epineurium was left intact when possible. In the setting of a constricting scar involving the epineurium, a meticulous longitudinal epineurectomy was performed to release the scar along the nerve.

The length of the neurolysed sciatic nerve was measured. A piece of acellular dermal matrix of corresponding length

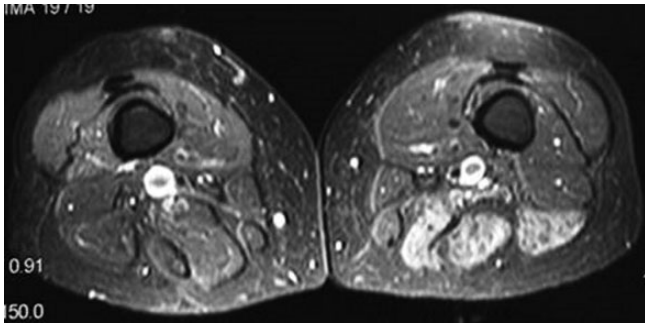


Figure 1. Hamstrings atrophy from denervation associated with sciatic nerve compression due to scar formation after chronic complete rupture of the hamstring tendon.

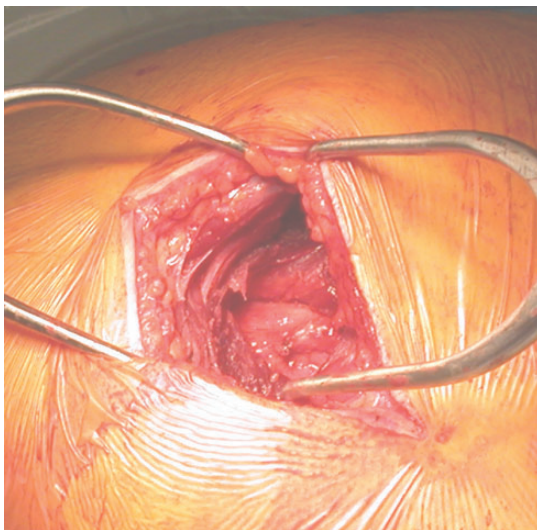


Figure 2. A gluteal splitting approach provides direct exposure of the hamstring muscles and ischial tuberosity.

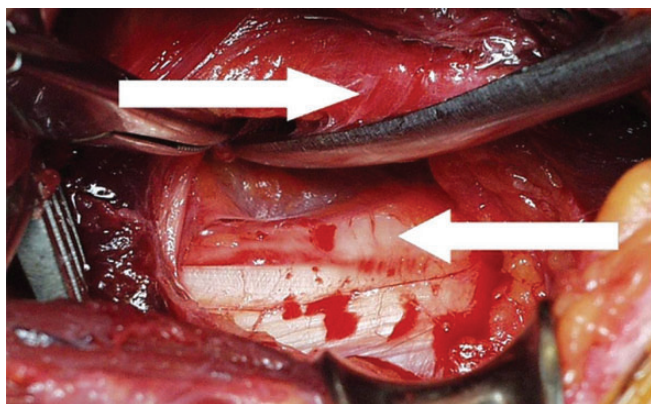


Figure 3. An extensive scar dissection is required around the ischial tuberosity to identify the sciatic nerve (top arrow) and the hamstring tendons (bottom arrow).

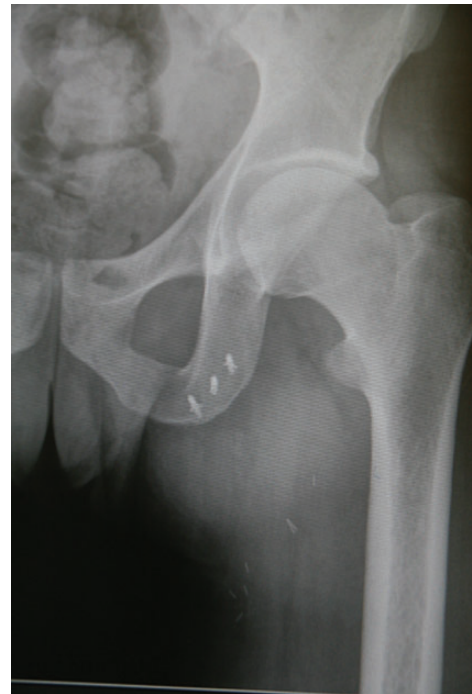

Figure 4. The hip is extended and knee is flexed to reduce the avulsion fragment or ruptured tendon in an anatomic position. Once this is achieved, 2 to 3 Mitek suture anchors were placed in the inferior pubic rami and the hamstring tendons were subsequently sutured to the anchor. The hamstring attachment is therefore adequately reduced. The torn ligament is also repaired to the adjacent intact hamstring tendon using Vicryl sutures.

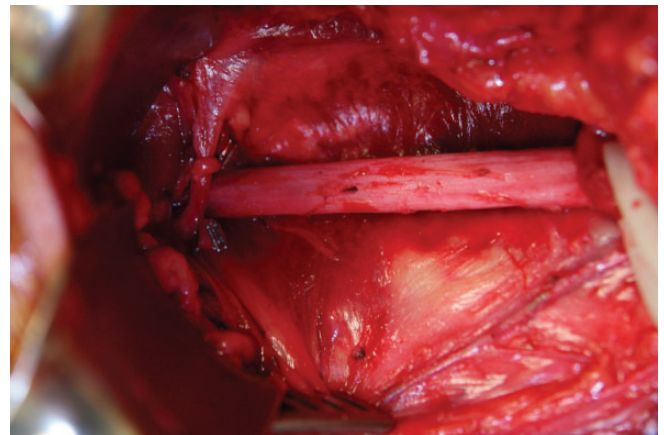


Figure 5. The sciatic nerve is meticulously neurolyzed to expose between 4.0 and 7.0 cm for preparation for the AlloDerm matrix. Any large epineural vessels are cauterized.

was subsequently selected with enough width to wrap circumferentially around the nerve. The length and width were generally between 4 and 5 cm and 3 and 4 cm, respectively. AlloDerm was rehydrated in sterile saline solution at 37.0°C for 30 minutes. Once the AlloDerm was

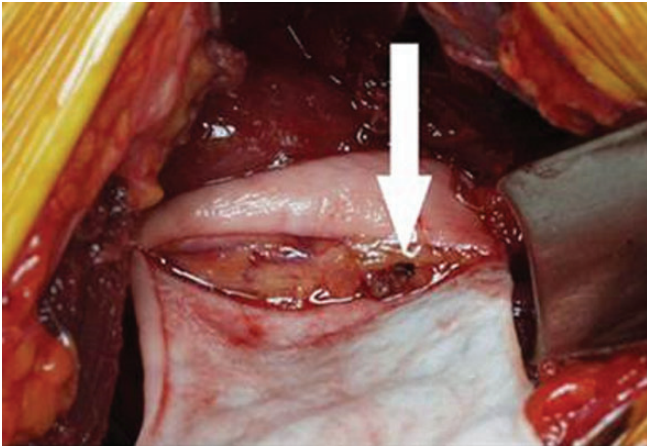


Figure 6. AlloDerm circumferentially wrapped, dermal side facing inward around the sciatic nerve.

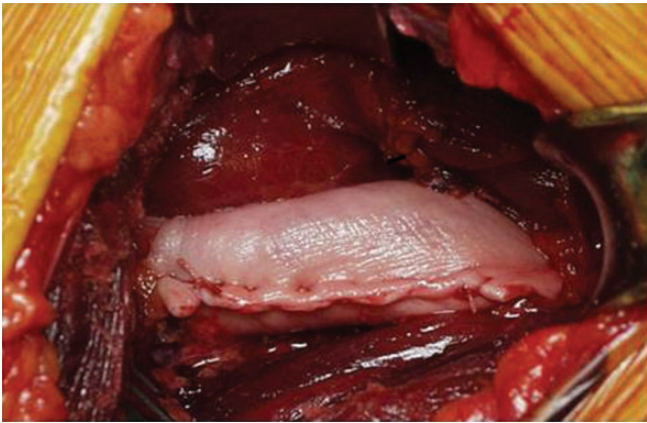


Figure 7. AlloDerm placed around the nerve without much tension to allow the nerve to slide within the wrap and to prevent restriction of any epineural vessels. It is then secured with interrupted 3-0 Vicryl sutures.

adequately rehydrated, it was cut to the appropriate size and carefully wrapped around the sciatic nerve with the dermal side facing the nerve. Any vascular pedicles were carefully ligated (Figure 6).

AlloDerm was wrapped around the nerve without tension to allow the nerve to slide within the wrap and to prevent restriction of any epineural vessels. It was then secured with interrupted 3-0 Vicryl sutures (Ethicon) (Figure 7). The most proximal suture was subsequently sutured to the local fascia, well proximal to the zone of injury to keep it from sliding distally.

The wound was then appropriately irrigated. Strict hemostasis was obtained using bipolar cautery. The muscle-splitting incision was then closed, and the wound was closed in layers using 2-0, 3-0, and 4-0 buried Vicryl sutures and running intracuticular 4-0 Monocryl sutures (Ethicon).

To protect the repair, immediately after surgery, patients were placed in a custom-fitted brace that limited hip flexion to 15° and knee extension to -60°. Each patient was placed on crutches and allowed touch-down weightbearing for 4 weeks. Passive range of motion of the hip was initiated at postoperative week 4 and full weightbearing allowed at week 6 on discontinuation of the brace. Active range of motion and aquatherapy progressed until week 10, when light jogging was allowed. Patients were allowed to return to sports after they demonstrated equal strength to the contralateral leg, usually around 4 months postoperatively.

RESULTS

We reviewed a total of 15 patients (7 females, 8 males) who suffered a proximal hamstring injury. Twelve had a complete proximal hamstring tendon rupture and 3 had an ischial tuberosity apophyseal avulsion fracture (Table 1). For each of the hamstring injuries, the displacement was greater than 2 cm.

All patients were treated with surgical repair of the hamstrings supplemented with sciatic nerve neurolysis and nerve wrapping with acellular dermal matrix. The mean time from injury to surgery was 21.9 months (range, 3-84 months).

All 15 patients were followed in the postoperative period for an average of 16.5 months (range, 6-43 months). Pain relief was regarded as “excellent” if the patient experienced only occasional pain that did not interfere with activities, “good” if the patient’s pain was caused only by strenuous activities but not light activities, “fair” if there was some relief from pain but nonnarcotic analgesics were used on a regular basis, and “none” if there were no changes in the level of pain.

Overall, 12 (80%) patients had a good or excellent outcome at the time of follow-up and 11 (73%) returned to their respective activities/sports. Postoperatively, there were 4 cases of transient sciatic nerve neurapraxia. Four patients (26%) required postoperative betamethasone sodium phosphate (Celestone Soluspan) injectable suspension USP 6 mg/mL.

Among the 9 patients with chronic pain from the hamstring injury who also had preoperative sciatica, 66% had a good or excellent outcome and were able to return to their respective activities/sports; 3 (33%) had persistent chronic pain. Of these 3 patients, 2 had a fair outcome and 1 had persistent sciatic neuropathy that required 2 surgical reexplorations and scar excision after development of recurrent extraneural scar formation. The mean time elapsed from the injury to neurolysis and repair was 14.0 months (range, 3-27 months) in patients who had poor or fair outcomes and 19.2 months (range, 5-32 months) in patients with good or excellent outcomes. Better outcomes were observed in younger patients, as the 3 cases of persistent chronic sciatic pain were in patients older than 45 years.

Among the 6 patients with chronic pain from the hamstring injury without preoperative sciatica, 100% had a good or excellent outcome and 83% returned to their respective activities/sports. Of these, the mean amount of time elapsed from the injury to neurolysis and repair was 27 months (range, 3-84 months).

DISCUSSION

Patients with complete ruptures of the proximal hamstring tendon or with ischial tuberosity apophyseal avulsion fractures can develop significant limitations due to persistent pain and weakness with knee flexion. There is debate in the literature about whether these injuries should be surgically repaired in an acute or delayed manner. Some studies suggest that patients have better clinical outcomes if they have early surgery, as those who receive delayed treatment have worse functional outcomes.^{7,13,15,17,26} However, conflicting studies report equal functional outcomes in patients treated acutely with those treated after an initial trial of nonoperative management.^{2,4,10}

However, as our case series illustrates, the concern with treating patients in a delayed manner is that they can develop chronic and painful symptoms. Many patients develop chronic buttock pain with sitting, which may or may not be associated with sciatic neuralgia. Scarring of the hamstring muscles adjacent to motor and sensory portions of the sciatic nerve^{6,8,14,17,23,26} contributes to the development of sciatic neuralgia. Because of these risks, our results suggest that complete hamstring ruptures and displaced ischial avulsions may be more effectively treated with earlier surgical repair.

The addition of barrier nerve wrapping to neurolysis procedures has proven successful in relieving the pain from scarred nerves in other clinical settings^{13,18} as well as in preventing the development or the recurrence of scar adhesions involving the nerve.¹³ The results of the present study suggest that nerve wrapping can be a safe and effective procedure in treating and preventing neuropathic pain associated with sciatic nerve compression after proximal hamstring injury. The majority of patients in the present series with debilitating preoperative neuropathic pain achieved excellent or good pain relief and had a relatively high rate of return to activity after surgery. Patients with chronic pain but without sciatic neuropathy also demonstrated benefit from the procedure, suggesting that when used in conjunction with hamstring repair, neurolysis-supplemented acellular dermal matrix may also limit postoperative scar formation around the adjacent nerve. Despite these promising results, age may be a negative risk factor for successful outcomes after repair and neurolysis, as the patients with fair or no improvement from surgery were older than 45 years. The chronicity and duration of symptoms since injury did not appear to be a negative risk factor as the mean time from injury to surgery in patients who had good or excellent outcomes was approximately 5 months more than for those who did not get much improvement. The significance of these findings would be improved with a larger series of patients.

For patients with chronic hamstring injuries, the sciatic nerve has been traditionally decompressed by performing a simple neurolysis.^{1,9,19,26} A major limitation of this approach is that it leaves the sciatic nerve unprotected while lying adjacent to the repaired hamstring tendon or avulsion fracture. During the healing of the hamstrings postoperatively, there is a fibroblastic response that can

lead to the recurrence of extraneural compressive scar around the sciatic nerve. The advantage of nerve wrapping is that it not only provides soft tissue padding to protect the nerve but also maintains proper gliding during motion by preventing the recurrence of adhesions. Persistent adhesions can permanently prohibit gliding of the nerve during adjacent hamstring or joint motion, causing chronic neuropathic pain, disability, and limited recovery.

AlloDerm is an acellular human dermis allograft that has been processed from tissue bank-derived skin.⁷ It has been successfully utilized in plastic surgery procedures^{1,19} because it can be customized to cover large areas and applied in sheets or rolled to increase tissue bulk. Its versatile properties make it a useful graft for nerve wrapping around the sciatic nerve near the ischium since a primary goal of flap coverage for neuropathic pain is to provide increased tissue padding. It is also effective because it is processed to remove all cells that would serve as antigenic stimulators of cell-mediated rejection. Because it is immunologically inert, it does not initiate reactive scarring around the nerve. In the present series, only 1 patient required revision neurolysis postoperatively after its use.

There are several steps to the procedure that are particularly important in maximizing patient outcomes. A requisite step is a complete neurolysis of the sciatic nerve to eliminate pathologic scarring. However, while this step is essential, it should be performed carefully without too much manipulation of the nerve. Four patients in the present series experienced transient painful postoperative sciatic neurapraxia that may have been associated with manipulation during the neurolysis. If the endoneurium is encased in fibrous scarring, a longitudinal epineurectomy should be performed to keep the epineurium with the nerve fascicles to prevent the devascularization of the nerve. Finally, to allow proper gliding of the nerve, the graft should be placed around the nerve with the slippery dermal slide facing in and should not be sutured down with excessive tension.

A limitation of the study is that it is a retrospective case series with a relatively low number of patients. Nevertheless, the results of our study suggest that when used as an adjunct to sciatic neurolysis, nerve wrapping with acellular dermal matrix can be a safe and effective method of treating patients with and preventing patients from developing sciatic neuropathic pain after chronic injury of the proximal hamstrings. Future studies will need to be performed that investigate outcomes using validated functional and pain scores as well as the results of pre- and postoperative electromyography.

REFERENCES

1. Achauer BM, VanderKam VM, Celikoz B, Jacobson DG. Augmentation of facial soft-tissue defects with AlloDerm dermal graft. *Ann Plast Surg*. 1998;41:503-507.
2. Birmingham P, Muller M, Wickiewicz T, Cavanaugh J, Rodeo S, Warren R. Functional outcome after repair of proximal hamstring avulsions. *J Bone Joint Surg Am*. 2011;93:1819-1826.
3. Blasler RB, Morawa LG. Complete rupture of the hamstring origin from water skiing injury. *Am J Sports Med*. 1990;18:435-437.

4. Brucker PU, Imhoff AB. Functional assessment after acute and chronic complete ruptures of the proximal hamstring tendons. *Knee Surg Sports Traumatol Arthrosc.* 2005;13:411-418.
5. Carmichael J, Packham I, Trikha SP, Wood DG. Avulsion of the proximal hamstring: surgical technique. *J Bone Joint Surg.* 2009;90:2365-2374.
6. Chakravarthy J, Ramisetty N, Pimpalnerkar A, Mohtadi N. Surgical repair of complete proximal hamstring tendon ruptures in water skiers and bull riders: a report of four cases and review of the literature. *Br J Sports Med.* 2005;39:569-572.
7. Cohen SB, Rangavajjula A, Vyas D, Bradley JP. Functional results and outcomes after repair of proximal hamstring avulsions. *Am J Sports Med.* 2012;40:2092-2098.
8. Colosomo AJ, Wyatt HM, Frank KA, Mangine RE. Hamstring avulsion injuries. *Oper Tech Sports Med.* 2005;13:80-88.
9. Cross MJ, Vandersluis R, Wood D, Banff M. Surgical repair of chronic complete hamstring tendon rupture in the adult patient. *Am J Sports Med.* 1998;26:785-788.
10. Folsom GJ, Larsen CG. Surgical treatment of acute versus chronic complete proximal hamstring ruptures: results of a new allograft technique for chronic reconstructions. *Am J Sports Med.* 2008;36:104-109.
11. Ishikawa K, Kai K, Mizuta H. Avulsion of the hamstring muscles from the ischial tuberosity. A report of two cases. *Clin Orthop Relat Res.* 1988;232:153-155.
12. Jones BV, Ward MW. Myositis ossificans in the biceps femoris muscles causing sciatic nerve palsy: a case report. *J Bone Joint Surg Br.* 2003;62:506-507.
13. Kibler WB. Diagnosis, treatment and rehabilitation principles in complete tendon ruptures in sports. *Scand J Med Sci Sports.* 1991;7:119-129.
14. Klingele KE, Sallay PI. Surgical repair of complete proximal hamstring tendon rupture. *Am J Sports Med.* 2002;30:742-747.
15. Lefevre N, Bohu Y, Naouri JF, Klouche S, Herman S. Returning to sports after surgical repair of acute proximal hamstring ruptures. *Knee Surg Sports Traumatol Arthrosc.* 2013;21:534-539.
16. Masear V. Nerve wrapping. *Foot Ankle Clin N Am.* 2011;16:327-337.
17. Orava S, Kujala UM. Rupture of the ischial origin of the hamstring muscles. *Am J Sports Med.* 1995;23:702-705.
18. Peterson SL, Adham MN. Acellular dermal matrix as an adjunct in treatment of neuropathic pain at the wrist. *J Trauma.* 2006;61:392-395.
19. Rohrich RJ, Reagan BJ, Adams WP Jr, Kenkel JM, Beran SJ. Early results of vermilion lip augmentation using acellular allogenic dermis: an adjunct in facial rejuvenation. *Plast Reconstr Surg.* 2000;105:409-416.
20. Sallay PI, Ballard G, Hamersly S, Schrader M. Subjective and functional outcomes following surgical repair of complete ruptures of the proximal hamstring complex. *Orthopedics.* 2008;31:1092.
21. Sarimo J, Lempainen L, Mattila K, Orava S. Complete proximal hamstring avulsions: a series of 41 patients with operative treatment. *Am J Sports Med.* 2008;36:1110-1115.
22. Servant CT, Jones CB. Displaced avulsion of the ischial apophysis: a hamstring injury requiring internal fixation. *Br J Sports Med.* 1998;32:255-257.
23. Takami H, Takahashi S, Ando M. Late sciatic nerve palsy following avulsion of the biceps femoris muscle from the ischial tuberosity. *Arch Orthop Trauma Surg.* 2000;120:352-354.
24. Wood DG, Packham I, Trikha SP, Linklater J. Avulsion of the proximal hamstring origin. *J Bone Joint Surg Am.* 2008;90:2365-2374.
25. Wootton JR, Cross MJ, Holt KW. Avulsion of the ischial apophysis. The case for open reduction and internal fixation. *J Bone Joint Surg.* 1990;72:625-627.
26. Xu J, Varitimidis SE, Fisher KJ, Tomiano MM, Sotereanos DG. The effect of wrapping scarred nerves with autogenous vein graft to treat recurrent chronic nerve compression. *J Hand Surg.* 2000;25:93-103.