



# Retinal blood flow in mild cognitive impairment and Alzheimer's disease

## Citation

Feke, Gilbert T., Bradley T. Hyman, Robert A. Stern, and Louis R. Pasquale. 2015. "Retinal blood flow in mild cognitive impairment and Alzheimer's disease." *Alzheimer's & Dementia : Diagnosis, Assessment & Disease Monitoring* 1 (2): 144-151. doi:10.1016/j.dadm.2015.01.004. <http://dx.doi.org/10.1016/j.dadm.2015.01.004>.

## Published Version

doi:10.1016/j.dadm.2015.01.004

## Permanent link

<http://nrs.harvard.edu/urn-3:HUL.InstRepos:27320265>

## Terms of Use

This article was downloaded from Harvard University's DASH repository, and is made available under the terms and conditions applicable to Other Posted Material, as set forth at <http://nrs.harvard.edu/urn-3:HUL.InstRepos:dash.current.terms-of-use#LAA>

## Share Your Story

The Harvard community has made this article openly available.  
Please share how this access benefits you. [Submit a story](#).

[Accessibility](#)

# Retinal blood flow in mild cognitive impairment and Alzheimer's disease

Gilbert T. Feke<sup>a</sup>, Bradley T. Hyman<sup>b</sup>, Robert A. Stern<sup>c</sup>, Louis R. Pasquale<sup>a,d,\*</sup>

<sup>a</sup>Department of Ophthalmology, Massachusetts Eye and Ear Infirmary, Harvard Medical School, Boston, MA, USA

<sup>b</sup>Department of Neurology, Massachusetts Alzheimer's Disease Research Center, Massachusetts General Hospital, Harvard Medical School, Boston, MA, USA

<sup>c</sup>Department of Neurology, Boston University Alzheimer's Disease Center, Boston University School of Medicine, Boston, MA, USA

<sup>d</sup>Department of Medicine, Channing Division of Network Medicine, Brigham and Women's Hospital, Harvard Medical School, Boston, MA, USA

## Abstract

**Background:** Patients with Alzheimer's disease (AD) demonstrate the narrowing of retinal veins and decreased retinal venous blood flow compared with control subjects. We assessed whether these abnormalities are present in patients with mild cognitive impairment (MCI).

**Methods:** After the determination of the global clinical dementia rating, 52 subjects (10 AD, 21 MCI, and 21 normal controls) underwent retinal hemodynamic profiling. Blood column diameter, blood speed, and blood flow were measured in a major temporal retinal vein using retinal laser Doppler flowmetry. In addition, peripapillary retinal nerve fiber layer (RNFL) thickness was measured using optical coherence tomography.

**Results:** Blood column diameter in AD was narrower than in both MCI ( $P = .004$ ) and controls ( $P = .002$ ). However, blood speed in both AD ( $P = .024$ ) and MCI ( $P = .005$ ) was lower than in controls. As a result, the differences in blood flow between AD and MCI ( $P = .036$ ), AD and controls ( $P < .0001$ ), and MCI and controls ( $P = .009$ ) were significant. Although there were no differences in RNFL thickness among the groups, blood flow was correlated ( $P = .047$ ) with superior RNFL thickness in the AD group, but not in the MCI ( $P = .40$ ) or control ( $P = .84$ ) groups.

**Conclusions:** Retinal blood flow in MCI is intermediate between what is measured in control subjects and in AD patients. Our findings suggest that blood flow abnormalities may precede the neurodegeneration in AD.

© 2015 The Authors. Published by Elsevier Inc. on behalf of the Alzheimer's Association. This is an open access article under the CC BY-NC-ND license (<http://creativecommons.org/licenses/by-nc-nd/4.0/>).

## Keywords:

Mild cognitive impairment; Alzheimer's disease; Retinal venous blood column diameter; Retinal blood speed; Retinal blood flow

## 1. Introduction

Transcranial Doppler ultrasonography [1], single photon emission computed tomography, and magnetic resonance imaging (MRI) [2] all demonstrate that cerebral blood flow is diminished in Alzheimer's disease (AD). The findings of diminished blood flow correlate with pathology studies that show decreased vascular density, tortuous arterioles, and deposition of excessive collagen in veins and venules [3,4]. However, there is as yet no consensus on whether decreased cerebral blood flow is a cause or a consequence

of AD [5]. It has been suggested that impaired nitric oxide signaling may contribute to the pathology associated with AD [6,7]. There is evidence that cerebral blood flow is already decreased in patients with mild cognitive impairment (MCI) [8], the condition thought to be the pre-dementia stage of AD. Reduced blood flow compared with controls in specific regions of the cerebral circulation in MCI patients has also significantly predicted the progression to AD in studies with follow-up periods ranging from 2 to 7 years [9–11].

There is evidence that the dysregulation of cerebral blood flow contributes to the pathogenesis of AD [12]. Resting cerebral blood flow is reduced, and the incremental blood flow response to neuronal stimulation is attenuated in AD [13].

\*Corresponding author. Tel.: +1-617-573-3670; Fax: +1-617-573-3707.  
E-mail address: [Louis\\_Pasquale@meei.harvard.edu](mailto:Louis_Pasquale@meei.harvard.edu)

Retinal and cerebral tissues share a common embryological origin, and their microvasculatures share anatomical and physiological similarities such as the presence of a tightly controlled blood-tissue barrier and autoregulatory capacity. Retinal vascular circulatory abnormalities are thus likely to reflect cerebrovascular pathology [14,15]. Because the retina is accessible to sensitive, noninvasive optical diagnostic methodologies, structural and functional abnormalities analogous to those established to occur in the brain in AD may also be observed in this tissue [16].

Structural retinal vascular abnormalities in AD patients include significant thinning of the blood column diameters in the larger retinal vessels and significantly decreased vessel density in the retinal microvascular network compared with controls [17,18]. Only one prior study also reported reduced retinal blood flow in patients with AD compared with control subjects [19]. There have not been any studies of retinal vascular structural abnormalities or of retinal blood flow abnormalities in patients with MCI. In this study, we sought to confirm the observations of altered retinal circulation in AD patients and to determine whether these abnormalities are also present in patients with milder clinical symptoms or MCI, that is, earlier in the course of the disease.

## 2. Methods

### 2.1. Study subjects

Subjects referred for the study underwent prior cognitive testing at either the Massachusetts Alzheimer's Disease Research Center or the Boston University Alzheimer's Disease Center. Subjects with MCI met the 2004 MCI Working Group Criteria [20] for amnesic MCI and had a global clinical dementia rating (CDR) of 0.5. Subjects with AD met both *Diagnostic and Statistical Manual of Mental Disorders, 4th Edition (DSM-IV)* [21] diagnostic criteria for dementia and National Institute of Neurological and Communicative Disorders and Stroke and the Alzheimer's Disease and Related Disorders Association criteria [22] for probable AD. Subjects with AD had a global CDR of either 1.0 or 2.0. Control subjects had normal cognition and a global CDR of 0.0. All diagnoses were made by a multidisciplinary consensus diagnostic conference. The Institutional Review Boards at the Massachusetts Eye and Ear Infirmary (MEEI), Massachusetts General Hospital, and the Boston University Medical Center approved this study. Written informed consent to participate was obtained from each subject before the ophthalmoscopic examinations that were performed at the MEEI. The investigators performing the retinal assessments were blind to the cognitive status of the subjects.

### 2.2. Study procedures

Each subject received a complete ophthalmic examination including visual acuity assessment, intraocular pressure (IOP)

measurement using Goldmann applanation tonometry (Haag Streit USA, Mason, OH), slit lamp biomicroscopy, indirect ophthalmoscopy, and digital fundus photography in both eyes. We added tropicamide 1% in both eyes for pupillary dilation. To facilitate the retinal blood flow measurements, only subjects with refractive error within the range  $-10$  to  $+10$  diopters, no significant cataract or cataract surgery within the prior 6 months, and pupillary dilation of at least 6 mm after mydriasis were tested. Subjects with a history of diabetes mellitus or evidence of glaucoma on examination were excluded from the analysis. Brachial artery blood pressure and pulse rate were measured using a Keller vital signs monitor (Keller Medical Specialties, Antioch, IL). Mean arterial pressure (MAP) was automatically displayed.

### 2.3. Laser Doppler retinal blood flow measurements

Blood column diameter, centerline blood speed, and retinal blood flow rate were reliably measured in a major temporal retinal vein of each subject using a Canon laser Doppler retinal blood flow instrument (CLBF 100, Canon, Tokyo, Japan). The basic principles, technical characteristics, and reproducibility of measurements using the instrument have been described previously [23]. The blood flow rate in units of microliter per minute in a retinal vessel is determined from simultaneous measurements of the blood column diameter and the centerline blood velocity. Measurement sites were along relatively straight segments of the largest temporal vein approximately one disc diameter away from the optic disc margin. The instrument is equipped with an internal fixation target and an automatic eye tracking system that maintains centration of the measuring laser beam on the target blood vessel to compensate for eye movements. Results are acquired at 50 measurements per second for 2 seconds. Bilateral measurements were not successful in all study subjects because of media opacities or the anatomical arrangement of the retinal vessels. Measurements in all subjects were performed during the midday hours, between 12 p.m. and 4 p.m., by the same experienced examiner (GTF). Only one eye of each subject was included in the analysis. If both eyes had reliable measurements, the eye with the larger diameter temporal retinal vein was designated as the study eye. The retinal vein with the largest diameter drains the largest retinal area and carries the greatest fraction of the total retinal blood flow. The blood flow in this vein is thus representative of the total retinal blood flow. Veins rather than arteries were chosen for measurement because of technical reasons. The instrument eye tracking system performs more efficiently when the target vessel has a larger diameter and carries deoxygenated blood. The designated eye was used in all subsequent analyses.

### 2.4. Retinal nerve fiber layer thickness measurements

To quantify retinal neuronal loss due to the pathological mechanisms associated with AD, peripapillary retinal nerve

fiber layer (RNFL) thickness was measured in both eyes of each subject using the Stratus OCT 3000 (Carl Zeiss Meditec, Inc., Dublin, CA). Optical coherence tomography (OCT) is a noninvasive technique that allows the high-resolution cross-sectional imaging of the retina. The basic principles and technical characteristics of the OCT have been described previously [24,25]. For the RNFL measurements the standard RNFL thickness circle scan mode consisting of three circular scans with a diameter of 3.4 mm centered on the optic nerve head was used. Average overall and quadrant (superior, inferior, temporal and nasal) RNFL thickness was automatically calculated. We chose the best quality scan (highest signal strength and adequate signal-to-noise ratio) for RNFL thickness analysis. A signal strength of 7 or greater in the study eye was required for inclusion in the analysis.

### 2.5. Statistical considerations

Before study inception, we calculated the statistical power to detect differences in retinal blood flow between the three study groups (AD, MCI, and controls) using a sample size of 30 subjects for each group. The results from our earlier study [19] of retinal blood flow differences between AD and control subjects were used to provide estimates. Assuming a two-sided test with  $\alpha = 0.05$ , the estimated power was  $>0.99$  to detect a 10% difference in the means between any two groups, 0.89 to detect a difference of 7% in the means, and 0.62 to detect a difference of 5% in the means. In this study we thus expected that there would be excellent power to detect a similar result between AD and control subjects and good power to detect retinal blood flow differences between MCI and control subjects where we hypothesized that the differences would be less striking.

All data were analyzed using the statistical software StatView for Windows, version 5.0 (SAS Institute, Cary, NC). Between group differences were assessed using the analysis of variance (ANOVA) with Fisher's Protected Least Significant Difference (PLSD) post hoc tests. Stepwise multiple linear regression analysis was used to determine which independent variables were significant determinants of the differences in retinal blood flow measured in study subjects. Univariate Spearman correlation analysis and linear regres-

sion analysis were used to examine the relationship between retinal blood flow and global CDR, age, MAP, and RNFL thickness. Results are expressed as mean  $\pm$  standard deviation. All tests were two tailed, and  $P$  values less than .05 were considered to be statistically significant.

### 3. Results

A total of 71 subjects were referred for the study. Retinal blood flow and RNFL thickness measurements were successfully obtained in 64 subjects. Of the remaining subjects, six had a history of type 2 diabetes mellitus, and two had an evidence of open angle glaucoma on examination. Data from these subjects were excluded from the analysis because decreases in retinal blood flow are known to occur in these conditions [26,27]. In addition, review of the dementia status of the remaining subjects revealed that elements of vascular dementia were included in the diagnosis of four patients. The data from these four patients were also excluded from the analysis. As a result, data from 52 subjects were used in the analysis.

Subjects ranged in age from 51 to 90 years ( $72.3 \pm 9.7$  years). Eighteen subjects were male and 34 were female. Four subjects were African American and 48 were Caucasian. Data from the right eye were analyzed in 18 subjects, and from the left eye in 34 subjects.

There were no statistically significant differences between the demographic and physiologic characteristics of the subjects when stratified according to the dementia status (Table 1).

#### 3.1. Venous diameter, blood speed, and blood flow according to cognitive status

Venous blood column diameter was  $133.8 \pm 8.8 \mu\text{m}$  in 10 subjects with AD (CDR = 1.0 or 2.0),  $153.2 \pm 17.4 \mu\text{m}$  in 21 subjects with MCI (CDR = 0.5), and  $154.3 \pm 18.7 \mu\text{m}$  in 21 control subjects (CDR = 0.0) (Fig. 1). The blood column diameter was significantly lower in AD subjects compared with the MCI subjects ( $P = .004$ ) and the control subjects ( $P = .002$ ). The difference in blood column diameter between the MCI and control subjects was not significant ( $P = .83$ ).

Table 1  
Demographic and physiologic characteristics of study subjects when stratified according to dementia status

	AD (n = 10)	MCI (n = 21)	Normal controls (n = 21)	$P$ value*
Age (yrs)	74.3 $\pm$ 12.2	74.4 $\pm$ 10.5	69.1 $\pm$ 6.7	.16
Gender (M/F)	3/7	11/10	4/17	.07
MAP (mmHg)	96.7 $\pm$ 11.5	94.0 $\pm$ 10.8	95.1 $\pm$ 17.8	.88
BP Meds (Y/N)	6/4	10/11	8/13	.53
Pulse (bpm)	70.9 $\pm$ 11.4	69.6 $\pm$ 11.3	69.5 $\pm$ 9.8	.94
IOP (mmHg)	15.1 $\pm$ 3.6	13.8 $\pm$ 2.7	14.4 $\pm$ 3.0	.52

Abbreviations: AD, Alzheimer's disease; MCI, mild cognitive impairment; M/F, male/female; MAP, mean brachial arterial pressure; BP Meds, blood pressure lowering medications; Y, yes; N, no; bpm, beats per minute; IOP, intraocular pressure.

\*ANOVA, analysis of variance.

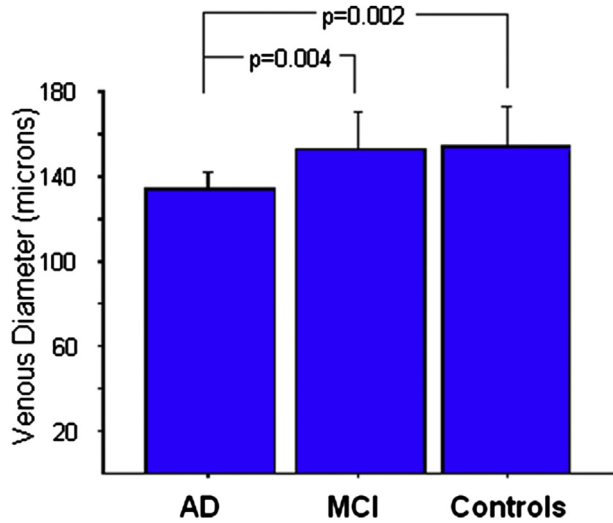


Fig. 1. Mean values of the retinal venous blood column diameter in subjects with Alzheimer's disease (AD), with mild cognitive impairment (MCI), and in control subjects. Error bars represent one standard deviation. Significance levels for paired comparisons were determined using Fisher's Protected Least Significant Difference (PLSD) tests.

Venous blood speed was  $29.1 \pm 6.3$  mm/s in subjects with AD,  $28.9 \pm 6.3$  mm/s in subjects with MCI, and  $36.0 \pm 9.3$  mm/s in control subjects (Fig. 2). The blood speed was significantly lower in both AD ( $P = .024$ ) and MCI subjects ( $P = .005$ ) compared with the blood speed in control subjects. The difference in blood speed between subjects with AD and MCI was not significant ( $P = .95$ ).

Venous blood flow was  $12.3 \pm 2.8$   $\mu$ l/min in subjects with AD,  $16.1 \pm 4.4$   $\mu$ l/min in subjects with MCI, and  $20.0 \pm 5.4$   $\mu$ l/min in control subjects (Fig. 3). The blood flow in AD subjects was significantly lower than in both MCI ( $P = .036$ ) and con-

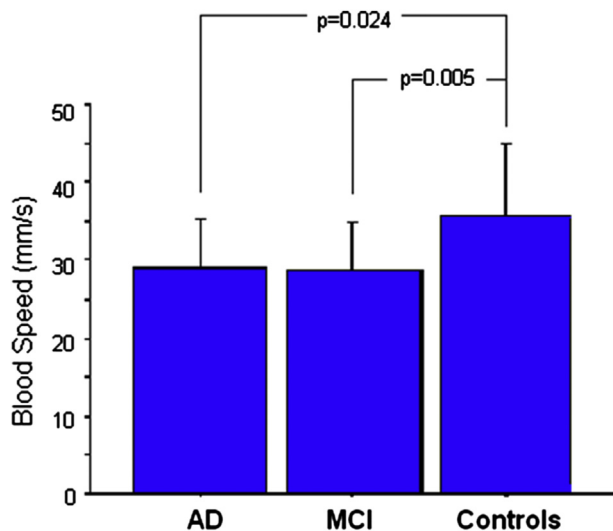


Fig. 2. Mean values of the retinal venous blood speed in subjects with Alzheimer's disease (AD), with mild cognitive impairment (MCI), and in control subjects. Error bars represent one standard deviation. Significance levels for paired comparisons were determined using Fisher's Protected Least Significant Difference (PLSD) tests.

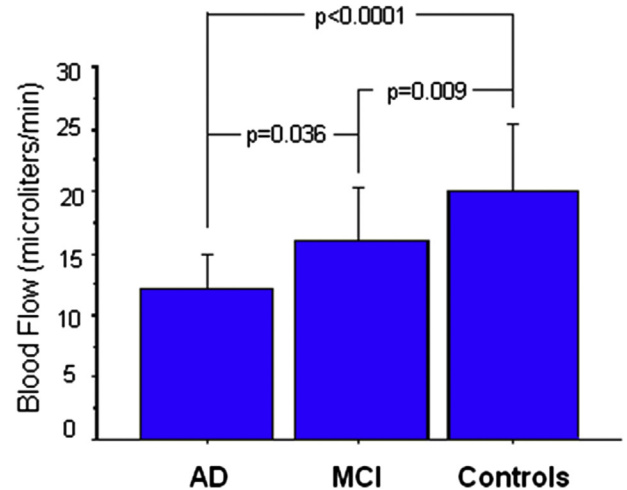


Fig. 3. Mean values of the retinal venous blood flow in subjects with Alzheimer's disease (AD), with mild cognitive impairment (MCI), and in control subjects. Error bars represent one standard deviation. Significance levels for paired comparisons were determined using Fisher's Protected Least Significant Difference (PLSD) tests.

rol subjects ( $P < .0001$ ). The blood flow in MCI subjects was also significantly lower than in control subjects ( $P = .009$ ).

### 3.2. RNFL thickness according to cognitive status and relationship to venous blood flow

There were no statistically significant differences between the RNFL thicknesses measured in the inferior, temporal, or nasal retinal quadrants between subjects with AD, MCI, and control subjects.  $P$  values ranged from 0.38 to 0.98. Superior quadrant RNFL thickness was  $108.8 \pm 13.3$   $\mu$ m in AD subjects,  $118.2 \pm 13.4$   $\mu$ m in MCI subjects, and  $117.7 \pm 15.2$   $\mu$ m in control subjects. Superior RNFL thickness in AD patients was decreased by 7.6% compared with control subjects ( $P = .109$ ) and by 8.0% compared with patients with MCI ( $P = .088$ ), differences that were not statistically significant. The 0.4% difference in superior RNFL thickness between the MCI and control subjects was also not significant ( $P = .90$ ).

The relationships between venous blood flow and superior RNFL thickness are illustrated by the correlation plots that include results from patients with AD in Fig. 4A, from patients with MCI in Fig. 4B, and from only control subjects in Fig. 4C. The positive correlation between venous blood flow and superior RNFL thickness in AD patients was statistically significant ( $\rho = 0.66$ ;  $P = .047$ ). However, there are no significant correlations between venous blood flow and superior RNFL thickness in MCI patients ( $\rho = 0.19$ ;  $P = .40$ ) or in control subjects ( $\rho = -0.04$ ;  $P = .84$ ).

### 3.3. Determinants of retinal blood flow

Stepwise multiple linear regression analyses were used to determine which factors were significantly related to the



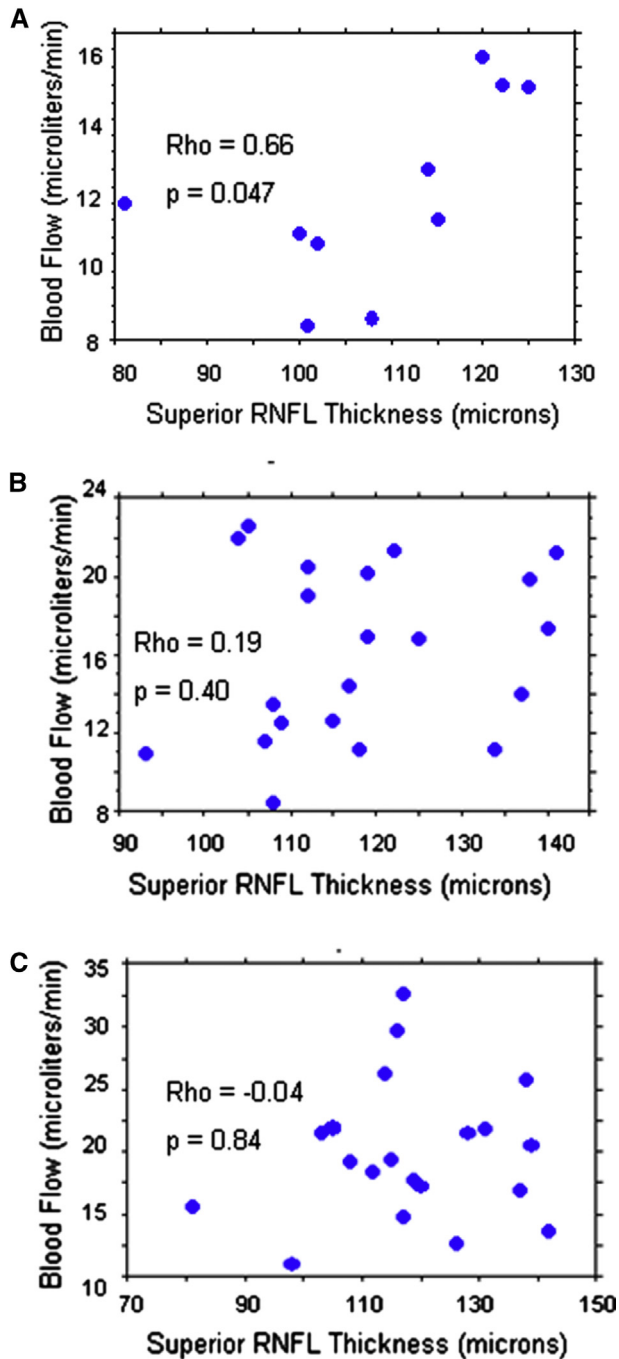


Fig. 4. Retinal venous blood flow plotted as a function of the thickness of the peripapillary retinal nerve fiber layer (RNFL) in the superior retinal quadrant in patients with Alzheimer's disease (AD) (A) with mild cognitive impairment (MCI) (B), and in normal control subjects (C). The values of the Spearman correlation coefficients ( $\rho$ ) and the corresponding  $P$  values are shown.

differences in retinal blood flow measured in study subjects. In the first analysis, the independent variables were age, sex, brachial MAP, pulse rate, IOP, average RNFL thickness from the four retinal quadrants, and global CDR. In an alternate analysis, the use or nonuse of blood pressure lowering med-

Table 2

Result of stepwise multiple linear regression analysis of independent factors significantly related to retinal venous blood flow measured in study subjects

	Coefficient	$P$ value
CDR	-5.29	<.0001
Age	-0.14	.032
MAP	0.11	.015

Abbreviations: CDR, global clinical dementia rating; MAP, mean brachial arterial pressure.

ications was considered instead of the actual brachial MAP. In the optimum model (Table 2), retinal blood flow decreases with increasing CDR ( $P < .0001$ ), increases with increasing MAP ( $P = .015$ ), and decreases with age ( $P = .032$ ).

#### 4. Discussion

The results confirm that retinal venous blood flow in AD is decreased compared with that in control subjects [19], and reveal that the same retinal circulatory abnormality is present in patients with MCI. In the prior study [19], which used the same laser Doppler methodology as this study, blood flow was decreased by 39.0% in AD patients compared with control subjects. In this study, blood flow in the AD patients is decreased by 38.6% compared with control subjects. The agreement is remarkable and solidifies the finding of reduced retinal blood flow in AD. To date, there have been no other studies reporting retinal blood flow findings in patients with AD.

There have been no prior studies of retinal blood flow in patients with MCI. In this study, blood flow in the MCI patients is decreased by 19.4% compared with control subjects. The magnitude of the decrease in blood flow in the MCI patients is one-half of the decrease in the AD patients.

There have been three prior studies of retinal venous blood column diameters in patients with AD. In the study [19] that used the same laser Doppler methodology as this study, the blood column diameter of the major temporal retinal vein was decreased by 11.2% in patients with AD compared with that in control subjects. In this study, the retinal venous blood column diameter is decreased by 13.3%. In another prior study [17], investigators used an automated retinal photographic technique and an algorithm to estimate the diameters of the central retinal artery and central retinal vein using the measured diameters of the six largest branch retinal arteries and six largest branch retinal veins in patients with AD and in control subjects. They reported a 4.8% decrease in the estimated central retinal artery diameter and a 7.1% decrease in the estimated central vein diameter in the AD patients compared with controls. More recently, other investigators [18] also used the same algorithmic retinal photographic technique and reported a 9.0% decrease in the estimated central retinal artery diameter and a 9.9% decrease in

the estimated central vein diameter in AD patients compared with controls. In this study, we directly measured the blood column diameter of the largest temporal vein in AD patients and in controls. Our results are consistent with those obtained using the retinal photographic method.

There have been no prior studies of retinal vascular blood column diameter in patients with MCI. In this study, venous blood column diameter in the largest temporal retinal vein in the MCI patients ( $153.2 \pm 17.4 \mu\text{m}$ ) was nearly identical to that measured in the control subjects ( $154.3 \pm 18.7 \mu\text{m}$ ). However, the venous blood speed was  $28.9 \pm 6.3 \text{ mm/s}$  in the MCI patients and  $36.0 \pm 9.3 \text{ mm/s}$  in the control subjects, a difference of 19.7%. The decrease in blood flow in the MCI patients is thus accounted for by the decrease in blood speed measured at the laser Doppler measurement site along the major temporal retinal vein. The decreased blood flow in MCI must then arise from narrower venules upstream from the measurement site, obstruction of retinal capillaries, retinal arterial constriction, or a combination of these factors.

Cerebral amyloid angiopathy, characterized by amyloid  $\beta$  ( $\text{A}\beta$ ) deposition in the walls of arteries and arterioles has been well documented in AD [28–31]. It is known that the intravascular deposition occurs in parallel with the formation of  $\text{A}\beta$  deposition in the parenchyma [32]. Deposition of collagen fibrils in the walls of capillaries [33] and veins [34,35] resulting in narrowed lumina and even occlusion has also been found in AD patients. It is thus likely that the mechanisms producing decreased blood column diameter with concomitant reduced blood flow in the retinal vasculature are analogous to those that produce the known vascular narrowing and reduced cerebral blood flow that occurs in AD. It is also reasonable to speculate that the narrowing of the retinal venous diameter observed in our study could be related to an increased venous wall thickness due to collagen deposition as found in cerebral veins.

It should be noted that although venous blood flow was decreased in our patients with MCI, venous blood column diameter in the large retinal veins, unlike in patients with AD, was not decreased. Our results suggest that retinal blood flow measurements are more sensitive than retinal vessel diameter measurements alone when detecting retinal hemodynamic changes earlier in the disease course of AD; that is, in MCI. Reduced blood flow compared with controls in specific regions of the cerebral circulation in MCI patients has significantly predicted the progression to AD in studies with follow-up periods ranging from 2 to 7 years [9–11]. It would be interesting to determine whether follow-up studies of retinal blood flow in MCI patients would also predict the progression to AD.

The most robust outcome of the multiple linear regression analysis was that retinal venous blood flow decreases with increasing global CDR, that is, with worsening dementia. However, the analysis also found that blood

flow decreases with increasing subject age. The decrease of retinal blood flow with aging in healthy subjects between the ages of 20 and 82 years has been reported in three studies [36–38]. In these three studies, blood flow decreased by 6.4%, 7.8%, and 11.2% per decade, respectively. Thus, both dementia and age contribute to decreasing blood flow. It should be noted, however, that the ages of the AD ( $74.3 \pm 12.2$  years) and MCI ( $74.4 \pm 10.5$  years) patients were nearly identical.

The trend toward the thinning of the superior RNFL in AD reported here is consistent with a prior study [19]. Such results are also consistent with a study that reported predominantly inferior visual field defects in AD patients, which correspond structurally to superior RNFL defects [39]. In our study, superior RNFL thickness differed by only 0.4% and average RNFL thickness using results from all four retinal quadrants differed by only 0.6% between MCI and control subjects. Other investigators who used the same OCT technology and also excluded patients with diabetes or glaucoma, however, reported that average RNFL thickness was decreased by 12.6% in 23 MCI subjects compared with 15 control subjects [40]. Surprisingly, those investigators also reported that average RNFL thickness in AD was nearly identical to that in MCI, decreasing by 12.7% in AD compared with control subjects. There is no clear explanation for the discrepancy between our results showing essentially no difference in RNFL thickness in MCI compared with control subjects and the other results showing a substantial difference in RNFL thickness in MCI compared with control subjects.

We also found a significant correlation between retinal venous blood flow and superior RNFL thickness in the AD patients. In contrast, there was no significant correlation between blood flow and superior RNFL thickness in the MCI patients or in the control subjects. Our data in MCI patients (decreased blood flow in the presence of unchanged RNFL thickness) suggest that blood flow abnormalities may precede rather than follow neurodegeneration in the pathological process that results in AD. This issue has been the subject of considerable debate [41,42]. Longitudinal follow-up studies of cognitive function, retinal blood flow, and RNFL thickness in MCI patients and control subjects should provide answers to this important question.

## Acknowledgments

Supported by grant # IIRG-08-90846: Objective Biomarkers for Alzheimer's Disease in the Retina from the Alzheimer's Association, Chicago, IL, grant # 1802: Objective Biomarkers for Alzheimer's Disease in the Retina from the Stranahan Foundation, Toledo, OH, and NIH grant #P30 AG13846: Boston University Alzheimer's Disease Core Center. Dr. Pasquale is a Distinguished Ophthalmology

Scholar supported by the Harvard Glaucoma Center of Excellence.

## RESEARCH IN CONTEXT

1. **Systematic review:** This article reports the results of a 3-year study entitled "Objective Biomarkers for Alzheimer's Disease in the Retina," which was funded primarily by the Alzheimer's Association. Preliminary findings had shown for the first time that retinal blood flow was abnormally decreased in patients with Alzheimer's disease (AD). The goal of this study was to determine whether blood flow decreases were already present in patients with mild cognitive impairment (MCI).
2. **Interpretation:** The study results show that, as in the cerebral circulation, blood flow in the retinal circulation is decreased in MCI and further decreased in AD. Our findings also suggest that blood flow abnormalities may precede neurodegeneration in AD. Because the retina is accessible to sensitive noninvasive optical diagnostic methodologies, it is an excellent site for the detection of the earliest structural and functional abnormalities in AD.
3. **Future directions:** A means to detect the earliest indicators of progression of MCI to AD is of utmost clinical importance because treatments applied early will be the most effective at delaying the neurodegenerative process. Monitoring retinal blood flow over time may provide the means to do this.

## References

- [1] Ruitenbergh A, den Heijer T, Bakker SL, van Swieten JC, Koudstaal PJ, Hofman A, et al. Cerebral hypoperfusion and clinical onset of dementia: The Rotterdam study. *Ann Neurol* 2005;57:789-94.
- [2] Austin BP, Nair VA, Meier TB, Xu G, Rowley HA, Carlson CM, et al. Effects of hypoperfusion in Alzheimer's disease. *J Alzheimer's Dis* 2011;26:123-33.
- [3] Brown WR, Thore CR. Review: cerebral microvascular pathology in ageing and neurodegeneration. *Neuropathol Appl Neurobiol* 2011; 37:56-74.
- [4] Hunter JM, Kwan J, Malek-Ahmadi M, Maarouf CL, Kokjohn TA, Belden C, et al. Morphological and pathological evolution of the brain microcirculation in aging and Alzheimer's disease. *PLoS One* 2012; 7:e36893.
- [5] Mazza M, Marano G, Traversi G, Bria P, Mazza S. Primary cerebral blood flow deficiency and Alzheimer's disease: shadows and lights. *J Alzheimer's Dis* 2011;23:375-89.
- [6] de la Torre JC, Stefano GB. Evidence that Alzheimer's disease is a microvascular disorder: the role of constitutive nitric oxide. *Brain Res Rev* 2000;34:119-36.
- [7] Katusic ZS, Austin SA. Endothelial nitric oxide: protector of a healthy mind. *Eur Heart J* 2014;35:888-94.
- [8] Maalikjy Akkawi N, Borroni B, Agosti C, Magoni M, Broli M, Pezzini A, et al. Volume cerebral blood flow reduction in pre-clinical stage of Alzheimer disease: evidence from an ultrasonographic study. *J Neurol* 2005;252:559-63.
- [9] Park KW, Yoon HJ, Kang DY, Kim BC, Kim SY, Kim JW. Regional cerebral blood flow differences in patients with mild cognitive impairment between those who did and did not develop Alzheimer's disease. *Psychiatry Res* 2012;203:201-6.
- [10] Hirao K, Ohnishi T, Hirata Y, Yamashita F, Mori T, Moriguchi Y, et al. The prediction of rapid conversion to Alzheimer's disease in mild cognitive impairment using regional cerebral blood flow SPECT. *Neuroimage* 2005;28:1014-21.
- [11] Hansson O, Buchhave P, Zetterberg H, Blennow K, Minthon L, Warkentin S. Combined rCBF and CSF biomarkers predict progression from mild cognitive impairment to Alzheimer's disease. *Neurobiol Aging* 2009;30:165-73.
- [12] Iadecola C. Neurovascular regulation in the normal brain and in Alzheimer's disease. *Nat Rev Neurosci* 2004;16:206-14.
- [13] Girouard H, Iadecola C. Neurovascular coupling in the normal brain and in hypertension, stroke, and Alzheimer's disease. *J Appl Physiol* (1985) 2006;100:328-35.
- [14] Patton N, Aslam T, MacGillivray T, Pattie A, Deary IJ, Dhillo N. Retinal vascular image analysis as a potential screening tool for cerebrovascular disease: a rationale based on homology between cerebral and retinal microvasculatures. *J Anat* 2005;206:319-48.
- [15] Ikram MK, Cheung CY, Wong TY, Chen CP. Retinal pathology as biomarker for cognitive impairment and Alzheimer's disease. *J Neurol Neurosurg Psychiatry* 2012;83:917-22.
- [16] Guo L, Duggan J, Cordeiro MF. Alzheimer's disease and retinal neurodegeneration. *Curr Alzheimer Res* 2010;7:3-14.
- [17] Frost S, Kanagasalingam Y, Sohrabi H, Vignarajan J, Bourgeat P, Salvado O, et al. Retinal vascular biomarkers for early detection and monitoring of Alzheimer's disease. *Transl Psychiatry* 2013;3:e233. <http://dx.doi.org/10.1038/tp.2012.150>.
- [18] Cheung CY, Ong YT, Ikram MK, Ong SY, Li X, Hilal S, et al. Microvascular network alterations in the retina of patients with Alzheimer's disease. *Alzheimers Dement* 2014;10:135-42.
- [19] Berisha F, Feke GT, Trempe CL, McMeel JW, Schepens CL. Retinal abnormalities in early Alzheimer's disease. *Invest Ophthalmol Vis Sci* 2007;48:2285-9.
- [20] Petersen RC. Mild cognitive impairment as a diagnostic entity. *J Intern Med* 2004;256:183-94.
- [21] *Diagnostic and Statistical Manual of Mental Disorders – fourth edition (DSM-IV)* Washington D.C: American Psychiatric Association; 1994.
- [22] McKhann G, Drachman D, Folstein M, Katzman R, Price D, Stadlan EM. Clinical diagnosis of Alzheimer's disease: report of the NINCDS-ADRDA Work Group under the auspices of Department of Health and Human Services Task Force on Alzheimer's disease. *Neurology* 1984;34:939-44.
- [23] Yoshida A, Feke GT, Mori F, Nagaoka T, Fujio N, Ogasawara H, et al. Reproducibility and clinical application of a newly developed stabilized retinal laser Doppler instrument. *Am J Ophthalmol* 2003; 135:356-61.
- [24] Huang D, Swanson EA, Lin CP, Schuman JS, Stinson WG, Chang W, et al. Optical coherence tomography. *Science* 1991;254:1178-81.
- [25] Hee MR, Izatt JA, Swanson EA, Huang D, Schuman JS, Lin CP, et al. Optical coherence tomography of the human retina. *Arch Ophthalmol* 1995;113:325-32.
- [26] Nagaoka T, Sato E, Takahashi A, Yokota H, Sogawa K, Yoshida A. Impaired retinal circulation in patients with type 2 diabetes mellitus: retinal laser Doppler velocimetry study. *Invest Ophthalmol Vis Sci* 2010;51:6729-34.
- [27] Berisha F, Feke GT, Hirose T, McMeel JW, Pasquale LR. Retinal blood flow and nerve fiber layer measurements in early-stage open-angle glaucoma. *Am J Ophthalmol* 2008;146:466-72.



- [28] Ellis RJ, Olichney JM, Thal LJ, Mirra SS, Morris JC, Beekly D, et al. Cerebral amyloid angiopathy in the brains of patients with Alzheimer's disease: the CERAD experience, part XV. *Neurology* 1996; 46:1592–6.
- [29] Vinters HV, Wang ZZ, Secor DL. Brain parenchymal and microvascular amyloid in Alzheimer's disease. *Brain Pathol* 1996;6: 179–95.
- [30] Jellinger KA. Alzheimer disease and cerebrovascular pathology: an update. *J Neural Transm* 2002;109:813–36.
- [31] Tian J, Shi J, Smallman R, Iwatsubo T, Mann DM. Relationships in Alzheimer's disease between the extent of A $\beta$  deposition in cerebral blood vessel walls, as cerebral amyloid angiopathy, and the amount of cerebrovascular smooth muscle cells and collagen. *Neuropathol Appl Neurobiol* 2006;32:332–40.
- [32] Thal DR, Griffin WS, Braak H. Parenchymal and vascular A $\beta$ -deposition and its effects on the degeneration of neurons and cognition in Alzheimer's disease. *J Cell Mol Med* 2008;12:1848–62.
- [33] Kalaria RN, Pax AB. Increased collagen content of cerebral microvessels in Alzheimer's disease. *Brain Res* 1995;705:349–52.
- [34] Brown WR, Moody DM, Thore CR, Challa WR. Cerebrovascular pathology in Alzheimer's disease and leukoaraiosis. *Ann N Y Acad Sci* 2000;903:39–45.
- [35] Brown WR, Moody DM, Challa VR, Thore CR, Anstrom JA. Venous collagenosis and arteriolar tortuosity in leukoaraiosis. *J Neurol Sci* 2002;203-204:159–63.
- [36] Embleton SJ, Hosking SL, Roff Hilton EJ, Cunliffe IA. Effect of senescence on ocular blood flow in the retina, neuroretinal rim and lamina cribrosa, using scanning laser Doppler flowmetry. *Eye* 2002; 16:156–62.
- [37] Groh MJ, Michelson G, Langhans MJ, Harazny J. Influence of age on retinal and optic nerve head blood circulation. *Ophthalmology* 1996; 103:529–34.
- [38] Grunwald JE, Piltz J, Patel N, Bose S, Riva CE. Effect of aging on retinal macular microcirculation: a blue field simulation study. *Invest Ophthalmol Vis Sci* 1993;34:3609–13.
- [39] Trick GL, Trick LR, Morris P, Wolf M. Visual field loss in senile dementia of the Alzheimer's type. *Neurology* 1995;45:68–74.
- [40] Paquet C, Boissonnot M, Roger F, Dighiero P, Gil R, Hugon J. Abnormal retinal thickness in patients with mild cognitive impairment and Alzheimer disease. *Neurosci Lett* 2007;420:97–9.
- [41] de la Torre JC. Alzheimer's disease: how does it start? *J Alzheimer's Dis* 2002;4:497–512.
- [42] Aliev G. Is non-genetic Alzheimer's disease a vascular disorder with neurodegenerative consequences? *J Alzheimer's Dis* 2002;4:513–6.