



# Use of Lumbar Perforator Recipient Vessels for Salvage Chest Wall Reconstruction: A Case Report

## Citation

Sillah, Nyama M., Jinesh Shah, Eugene Fukudome, and Samuel J. Lin. 2016. "Use of Lumbar Perforator Recipient Vessels for Salvage Chest Wall Reconstruction: A Case Report." *Plastic and Reconstructive Surgery Global Open* 4 (3): e642. doi:10.1097/GOX.0000000000000540. <http://dx.doi.org/10.1097/GOX.0000000000000540>.

## Published Version

doi:10.1097/GOX.0000000000000540

## Permanent link

<http://nrs.harvard.edu/urn-3:HUL.InstRepos:27662101>

## Terms of Use

This article was downloaded from Harvard University's DASH repository, and is made available under the terms and conditions applicable to Other Posted Material, as set forth at <http://nrs.harvard.edu/urn-3:HUL.InstRepos:dash.current.terms-of-use#LAA>

## Share Your Story

The Harvard community has made this article openly available.  
Please share how this access benefits you. [Submit a story](#).

[Accessibility](#)

# Use of Lumbar Perforator Recipient Vessels for Salvage Chest Wall Reconstruction: A Case Report

Nyama M. Sillah, MD  
Jinesh Shah, BS  
Eugene Fukudome, MD  
Samuel J. Lin, MD

**Summary:** Abdominal-based free flaps are commonly used for breast reconstruction, and the internal mammary or thoracodorsal vessels are typically used as recipient sites. Conversely, free tissue transfer is less commonly used for chest wall reconstruction in the setting of chest wall recurrence, in part, because of a paucity of recipient vessels. Here, we describe a case of a 68-year-old female smoker with metastatic breast cancer, who presented with a chest wall recurrence. There was a large area of chronic ulceration with foul smelling drainage, in addition to radiation-induced tissue injury, and palliative resection was performed. The area was reconstructed with a free transverse rectus abdominis myocutaneous flap using lumbar perforators as recipient vessels, because conventional recipient sites were unavailable because of scarring from radiation and residual tumor. This case demonstrates that uncommon recipient vessels such as lumbar perforators may allow for successful palliative chest wall reconstruction. We hypothesize that the tumor burden, previous surgeries, and radiation may have rendered the recipient field relatively ischemic, thereby inducing hypertrophy of the lumbar perforators, similar to a delay phenomenon. (*Plast Reconstr Surg Glob Open* 2016;4:e642; doi: 10.1097/GOX.0000000000000540; Published online 17 March 2016.)

A 68-year-old woman with recurrent, metastatic breast cancer to the right chest wall presented for extirpation and reconstruction in July, 2014. On presentation, she had a large area of ulceration with foul smelling drainage over a previous drain site overlying a large mass, which had been present for 3 to 4 years (Fig. 1). She previously had been diagnosed with breast cancer in 2005 and underwent mastectomy. She developed a right axillary recurrence in 2010. She underwent radiotherapy to the right axilla and chest wall, which was completed

in April, 2014. She also received multiple rounds of chemotherapy. Over the past few months, she had an approximate 70-pound weight loss and was a current smoker who smoked 2 packs per day.

The patient was brought to the operating room on July 31, 2014, and the mass was resected by thoracic surgery. There was extension of the mass into the axilla, and it was indeterminate whether this represented radiation or postsurgical changes or tumor after resection by the ablative surgical team. The decision was made to leave this area undissected as to not cause additional morbidity (Fig. 2). Although the resection was taking place, a contralateral left free transverse rectus abdominis myocutaneous (TRAM) flap was raised concurrently. After the completion of the extirpation, the defect was explored for recipient vessels. There were vessels visualized on the subscapular pedicle that appeared heavily radiated, scarred, and adjacent to the tissue potentially repre-

*From the Division of Plastic Surgery, Beth Israel Deaconess Medical Center, Harvard Medical School, Boston, Mass.*

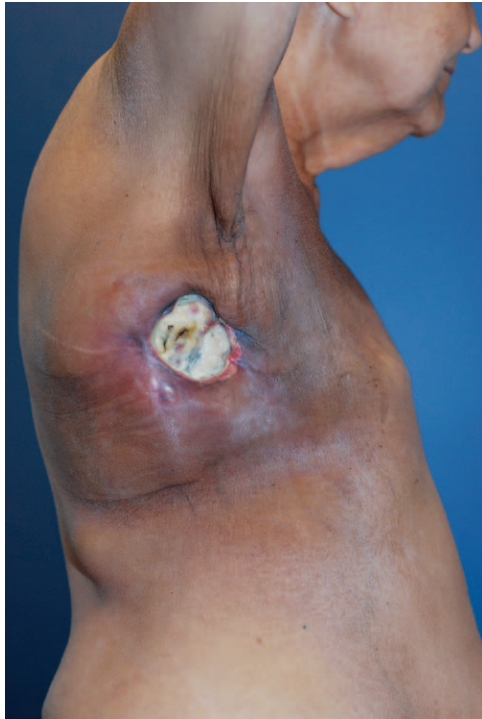*Received for publication April 15, 2015; accepted September 9, 2015.*

*Drs. Sillah and Shah contributed equally to this article.*

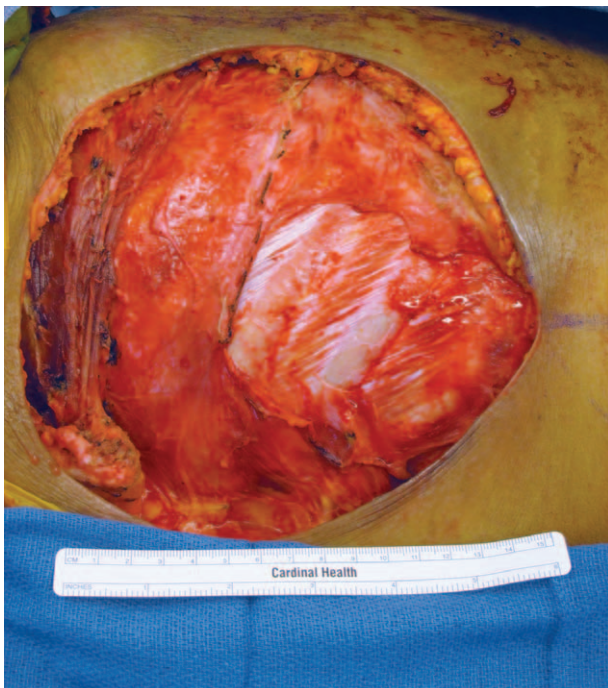
*Copyright © 2016 The Authors. Published by Wolters Kluwer Health, Inc. on behalf of The American Society of Plastic Surgeons. All rights reserved. This is an open-access article distributed under the terms of the Creative Commons Attribution-Non Commercial-No Derivatives License 4.0 (CCBY-NC-ND), where it is permissible to download and share the work provided it is properly cited. The work cannot be changed in any way or used commercially.*

DOI: 10.1097/GOX.0000000000000540

**Disclosure:** The authors have no financial interest to declare in relation to the content of this article. The Article Processing Charge was paid for by the authors.



**Fig. 1.** Preoperative lateral view of the patient with exophytic chronic open wound containing metastatic tumor.



**Fig. 2.** Chest wall defect after tumor extirpation for palliation.

sending scar or residual tumor. Because of the findings, alternate recipient vessels were sought. There was a suitable lumbar perforator that was visualized (Fig. 3) lower on the truncal area. Anastomosis was performed, and once flow was established through

the artery and vein, the flap was inset without complication.

The patient did well during her hospitalization and was able to be discharged on postoperative day 4. She returned to clinic the following week, the flap was warm and well perfused, and the drains were removed (Fig. 4). She continued to do well perioperatively at last follow-up. Institutional review board exemption was granted by our institutional review board.

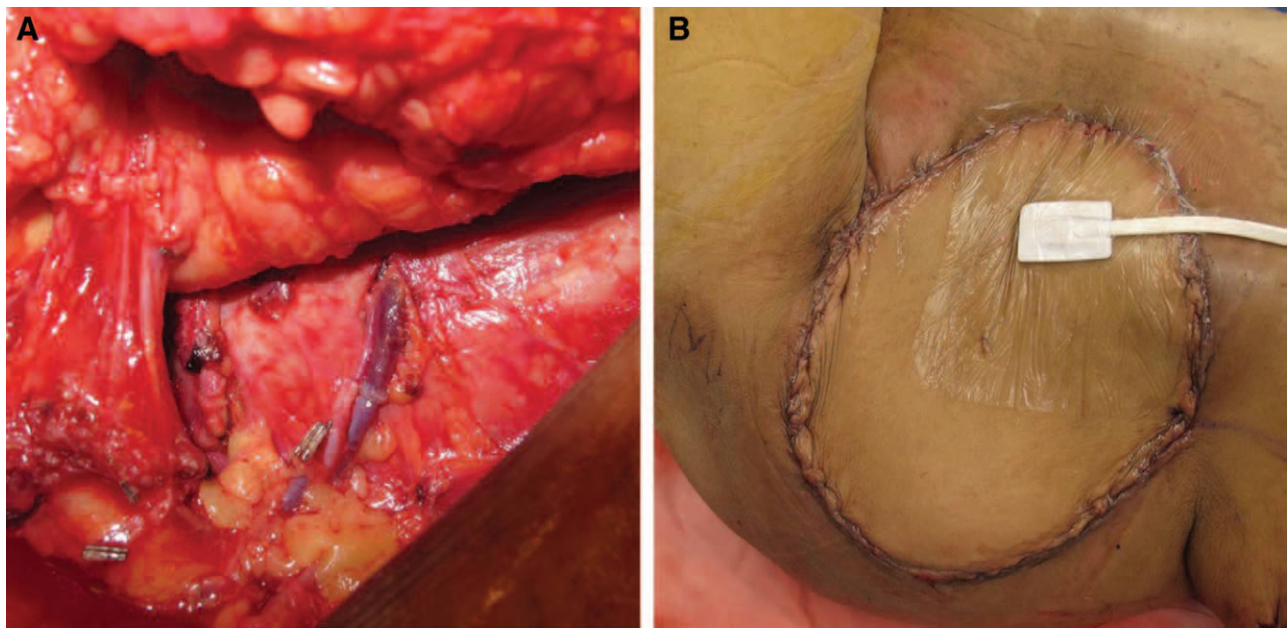
## DISCUSSION

The TRAM flap was first described in 1982 by Hartrampf.<sup>1</sup> The pedicled TRAM flap as described by Hartrampf evolved into the free TRAM flap, described by Holmstrom, and eventually led to the deep inferior epigastric perforator flap, popularized for breast reconstruction.<sup>1</sup> Microvascular free flap reconstruction has become a staple in breast reconstruction because of improved blood supply at the recipient site and reduced anatomical defects and scarring at the donor site.<sup>2,3</sup> In addition, patients actively smoking undergoing reconstruction using a free TRAM flap had lower complications than those undergoing one using a pedicled TRAM flap<sup>4</sup> secondary to the adverse affects nicotine has on vascular health, resulting in decreased number of perforators and reduced blood supply.

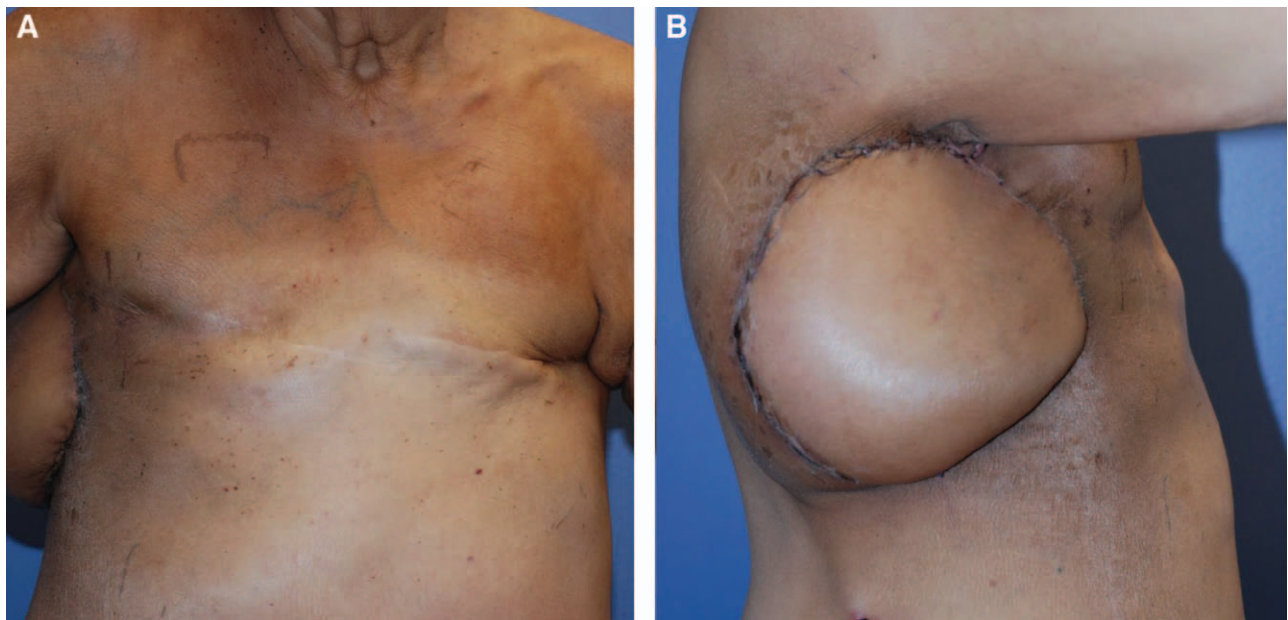
The choice of the recipient vessel during reconstruction is dependent on the surgeon and timing of the reconstruction such as delayed versus intermediate, but commonly the internal mammary and thoracodorsal vessels are used as recipients.<sup>5</sup> In rare cases, subscapular vessels, transverse cervical, and lateral thoracic vessels are utilized.<sup>5</sup> In this case, because of scarring from the previous chest wall irradiation, previous surgical intervention, and concern about unresectable tumor encasing some of the vasculature, neither the internal mammary nor the thoracodorsal vessels were suitable recipients. Anastomosis with the axillary artery was avoided because of feared upper limb complications from shunting and/or postoperative occlusion.

Cadaveric and clinical anatomical studies have demonstrated that lumbar perforators can be often used as both donor and recipient vessels for free flap surgeries. Despite the variability in their sizes, 1 study identified lower lumbar perforators as having adequate lumen size and being easily verifiable by computed tomographic angiography.<sup>6</sup> There have been reports describing the use of a lumbar artery free perforator flap for autologous breast reconstruction; however, to our knowledge, there have been no re-





**Fig. 3.** Lumbar perforator recipient vessels (A) and flap inset after anastomosis (B).



**Fig. 4.** Postoperative views of the patient 3 weeks postoperatively.

ports describing the use of a lumbar artery perforator as a recipient vessel for free flap palliative chest wall reconstruction in the setting of previous mastectomy and radiation for breast cancer.<sup>7</sup>

In the presented case, the success of the reconstruction was potentially aided by a tumor “delay phenomenon.” Although the exact mechanism of the delay phenomenon has not been elucidated, it is hypothesized that ischemia induces hypertrophy of remaining vasculature and increases ischemia tolerance through locally mediated fac-

tors.<sup>8,9</sup> In many cases, the donor tissue is delayed by partially incising the tissue, which creates an ischemic environment, and hypertrophy of existing vessels, which improves graft survival during transposition of tissue in a delayed fashion. In this case, however, the longstanding tumor burden, previous surgeries, and irradiation of the recipient field created an ischemic environment similar to a delay phenomenon. In this patient, vessels in the area, specifically lumbar perforators, may have hypertrophied because of the prolonged ischemic

conditions to become suitable recipients for free tissue transfer.

Chest wall reconstruction in the setting of recurrent metastatic breast cancer after previous radiation therapy can pose a difficult reconstructive challenge. The ischemic environment induced by various factors including tumor burden and radiation may have a beneficial effect on lumbar perforators, which may become suitable recipients for free flap reconstruction when traditional vessel recipients are unusable in certain cases.

**Samuel J. Lin, MD**

Division of Plastic Surgery  
Beth Israel Deaconess Medical Center  
Harvard Medical School, 110 Francis Street  
Suite 5A, Boston, MA 02215  
E-mail: sjlin@bidmc.harvard.edu

## REFERENCES

1. Uroskie TW, Colen LB. History of breast reconstruction. *Semin Plast Surg.* 2004;18:65–69.
2. Kroll SS, Baldwin B. A comparison of outcomes using three different methods of breast reconstruction. *Plast Reconstr Surg.* 1992;90:455–462.
3. Schusterman MA. The free TRAM flap. *Clin Plast Surg.* 1998;25:191–195.
4. Moran SL, Serletti JM. Outcome comparison between free and pedicled TRAM flap breast reconstruction in the obese patient. *Plast Reconstr Surg.* 2001;108:1954–1960; discussion 1961.
5. Temple CL, Strom EA, Youssef A, et al. Choice of recipient vessels in delayed TRAM flap breast reconstruction after radiotherapy. *Plast Reconstr Surg.* 2005;115:105–113.
6. Kiil BJ, Rozen WM, Pan WR, et al. The lumbar artery perforators: a cadaveric and clinical anatomical study. *Plast Reconstr Surg.* 2009;123:1229–1238.
7. de Weerd L, Elvenes OP, Strandenes E, et al. Autologous breast reconstruction with a free lumbar artery perforator flap. *Br J Plast Surg.* 2003;56:180–183.
8. Dhar SC, Taylor GI. The delay phenomenon: the story unfolds. *Plast Reconstr Surg.* 1999;104:2079–2091.
9. Maitz PK, Pribaz JJ, Duffy FJ, et al. The value of the delay phenomenon in flap prefabrication: an experimental study in rabbits. *Br J Plast Surg.* 1994;47:149–154.