



Planum Temporale and Heschl Gyrus Volume Reduction in Schizophrenia

Citation

Hirayasu, Yoshio, Robert W. McCarley, Dean F. Salisbury, Shin Tanaka, Jun Soo Kwon, Melissa Frumin, Danielle Snyderman, Deborah Yurgelun-Todd, Ron Kikinis, Ferenc A. Jolesz, and Martha E. Shenton. 2000. Planum Temporale and Heschl Gyrus Volume Reduction in Schizophrenia. *Arch Gen Psychiatry* 57, no. 7: 692–699.

Published Version

<http://archpsyc.jamanetwork.com/article.aspx?articleid=481629>

Permanent link

<http://nrs.harvard.edu/urn-3:HUL.InstRepos:28520159>

Terms of Use

This article was downloaded from Harvard University's DASH repository, and is made available under the terms and conditions applicable to Other Posted Material, as set forth at <http://nrs.harvard.edu/urn-3:HUL.InstRepos:dash.current.terms-of-use#LAA>

Share Your Story

The Harvard community has made this article openly available.
Please share how this access benefits you. [Submit a story](#).

[Accessibility](#)

Published in final edited form as:

Arch Gen Psychiatry. 2000 July ; 57(7): 692–699.

Planum Temporale and Heschl Gyrus Volume Reduction in Schizophrenia:

A Magnetic Resonance Imaging Study of First-Episode Patients

Yoshio Hirayasu, MD, PhD¹, Robert W. McCarley, MD^{1,2}, Dean F. Salisbury, PhD^{1,2}, Shin Tanaka, MD¹, Jun Soo Kwon, MD, PhD¹, Melissa Frumin, MD¹, Danielle Snyderman, BS¹, Deborah Yurgelun-Todd, PhD³, Ron Kikinis, MD⁴, Ferenc A. Jolesz, MD^{1,4}, and Martha E. Shenton, PhD^{1,2}

¹ Clinical Neuroscience Division, Laboratory of Neuroscience, Department of Psychiatry, Brockton Veterans Affairs Medical Center, and Harvard Medical School, Brockton, Mass

² Cognitive Neuroscience Laboratory, McLean Hospital, Belmont, Mass

³ Brain Imaging Center, McLean Hospital, Belmont, Mass

⁴ The Surgical Planning Laboratory, MRI Division, Brigham and Women's Hospital, Department of Radiology, Harvard Medical School, Boston, Mass

Abstract

Background—Magnetic resonance imaging studies in schizophrenia have revealed abnormalities in temporal lobe structures, including the superior temporal gyrus. More specifically, abnormalities have been reported in the posterior superior temporal gyrus, which includes the Heschl gyrus and planum temporale, the latter being an important substrate for language. However, the specificity of the Heschl gyrus and planum temporale structural abnormalities to schizophrenia vs affective psychosis, and the possible confounding roles of chronic morbidity and neuroleptic treatment, remain unclear.

Methods—Magnetic resonance images were acquired using a 1.5-T magnet from 20 first-episode (at first hospitalization) patients with schizophrenia (mean age, 27.3 years), 24 first-episode patients with manic psychosis (mean age, 23.6 years), and 22 controls (mean age, 24.5 years). There was no significant difference in age for the 3 groups. All brain images were uniformly aligned and then reformatted and resampled to yield isotropic voxels.

Results—Gray matter volume of the left planum temporale differed among the 3 groups. The patients with schizophrenia had significantly smaller left planum temporale volume than controls (20.0%) and patients with mania (20.0%). Heschl gyrus gray matter volume (left and right) was also reduced in patients with schizophrenia compared with controls (13.1%) and patients with bipolar mania (16.8%).

Conclusions—Compared with controls and patients with bipolar manic psychosis, patients with first-episode schizophrenia showed left planum temporale gray matter volume reduction and bilateral Heschl gyrus gray matter volume reduction. These findings are similar to those reported in patients with chronic schizophrenia and suggest that such abnormalities are present at first episode and are specific to schizophrenia.

Structural brain abnormalities in schizophrenia have been extensively investigated using magnetic resonance imaging (MRI).¹⁻⁵ Several studies have reported abnormalities in portions of the superior temporal gyrus (STG) in patients diagnosed as having schizophrenia,¹⁻³ including planum temporale (PT) and Heschl gyrus (HG) (primary auditory cortex).⁶⁻¹⁴ The impetus for much of this work is based on the role that the left (dominant) hemisphere PT plays in language processing¹⁵⁻¹⁷ and the role that the HG plays in the initial processing of auditory information.¹⁻³

DeLisi et al¹⁰ measured length of the sylvian fissure and reported asymmetry differences in patients with first-episode schizophrenia compared with controls. Reduced cortical PT volume was reported in a postmortem study in schizophrenia compared with controls,¹⁸ and we reported reduced left PT gray matter volume and a reversal of PT asymmetry in patients diagnosed as having chronic schizophrenia.⁶ Other investigators^{7,8} measuring PT area in schizophrenia also reported a reversal of the left larger than right PT asymmetry found in controls. However, several investigators⁹⁻¹³ have not reported abnormalities of PT asymmetry in schizophrenia. Of particular note, Kleinschmidt and colleagues¹¹ reported no differences in PT area between first-episode patients with schizophrenia and controls. This lack of consistency in results is likely due to variations in the definition of PT, as discussed by Barta and coworkers.¹⁹

Fewer studies of HG have been conducted, although asymmetrical length has been reported in HG (left greater than right) in healthy patients in a postmortem study by Musiek and Reeves.²⁰ Only one group²¹ using MRI has reported a left HG volume greater than the right in controls and patients with paranoid schizophrenia. However, other investigators^{7,12,14} have reported no asymmetry between left and right HG and no difference in asymmetry between patients with schizophrenia and controls. To our knowledge, no studies have evaluated *gray* matter volume of HG and PT concurrently in patients with schizophrenia and those with affective psychosis at the time of first hospitalization.

It remains uncertain whether the psychosis associated with affective disorder and schizophrenia represents manifestations of different disorders or variants of a single disorder with somewhat different expressions.²² The MRI studies that evaluate both patient groups may assist in answering this question. We previously reported²³ that first-episode patients with schizophrenia showed smaller gray matter volume in a posterior segment of STG than first-episode patients with affective disorder and controls. The MRI evidence also supporting pathophysiological differences comes from Pearlson and colleagues,²⁴ who reported STG and medial temporal lobe abnormalities in patients with schizophrenia but not in patients with bipolar disorder.

The posterior STG segment, reported previously by us, included only a fraction of the whole PT, and HG was not evaluated. In the present study, gray matter volume of PT and HG was measured to determine whether PT and HG abnormalities are present at first episode and specific to schizophrenia as contrasted with first-episode manic psychosis.

RESULTS

There were no significant group differences in age. First-episode patients with schizophrenia showed significantly lower SES than comparison subjects, consistent with reduced functioning (Table 1). Parental SES was upper middle class or above for all groups, but parental SES of the schizophrenia group was lower than parental SES of the other 2 comparison groups. There were no significant differences between patients diagnosed as having schizophrenia and patients diagnosed as having mania on any of the clinical scale measures, age of first medication use, medication dose, or duration of illness. There were significant differences between the

patient groups in 4 items of the BPRS. Patients with schizophrenia showed higher scores (mean \pm SD) in suspiciousness (schizophrenia, 4.26 ± 1.88 ; mania, 2.96 ± 2.14 ; $t_{42} = 2.07$; $P = .04$), hallucinatory behavior (schizophrenia, 3.05 ± 1.81 ; mania, 2.00 ± 1.01 ; $t_{42} = 2.06$; $P = .046$), and blunted affect (schizophrenia, 3.11 ± 1.76 ; mania, 1.70 ± 1.40 ; $t_{42} = 2.84$; $P = .007$) than patients with mania. In contrast, patients with mania showed higher scores for grandiosity (schizophrenia, 1.42 ± 3.01 ; mania, 3.83 ± 1.02 ; $t_{42} = 3.32$; $P = .002$). Total score on the BPRS, age of first medication use, and duration of medication use did not correlate with any ROI volumes. There was also no significant difference in ICC volume among the 3 groups.

VOLUME OF THE PT AND HG

The 3-factor ANCOVA revealed a significant group-by-side-by-region interaction ($F_{2,61} = 4.41$, $P = .02$). Follow-up ANCOVA revealed a significant group-by-side interaction ($F_{2,61} = 7.62$, $P = .001$) in PT. One-way ANCOVA showed that left PT differed among groups ($F_{2,61} = 4.76$, $P = .01$), with the schizophrenia group significantly smaller than the control and mania groups (Tukey Honestly Significant Difference, $P < .05$) (Table 2 and Figure 2). However, right PT was not different among groups.

For HG, there was a significant main effect for group ($F_{2,61} = 4.67$, $P = .01$), with no group-by-side interaction ($F_{2,61} = 0.21$, $P = .98$). Post hoc tests revealed that total (left and right) HG gray matter volume was significantly smaller in schizophrenic patients compared with patients with mania and healthy control subjects (Tukey Honestly Significant Difference, $P < .05$) but that group differences for left and right HG did not reach significance by 1-way ANCOVA ($F_{2,61} = 2.11$, $P = .13$; $F_{2,61} = 2.49$, $P = .09$, respectively) (Table 2 and Figure 2). However, HG was significantly asymmetrical in all subjects ($F_{1,61} = 4.19$, $P = .04$).

Note that, compared with controls and patients with mania, patients with schizophrenia show gray matter volume reductions of 20.0% in left PT (effect size = 0.91). In addition, compared with controls, patients with schizophrenia show gray matter volume reductions of 15.3% in left HG (effect size = 0.71) and 10.6% in right HG (effect size = 0.44). For HG (left+right), patients with schizophrenia, compared with controls and patients with mania, showed 13.1% (effect size = 0.87) and 16.8% (effect size = 1.16) volume reduction, respectively.

CORRELATIONS BETWEEN ROI VOLUMES AND PSYCHOPATHOLOGY

In an exploratory analysis, no factors or items of the BPRS significantly correlated ($P < .05$) with absolute or relative volumes of PT or HG in first-episode schizophrenia or in first-episode mania. In addition, none of the cognitive tests were statistically significantly correlated with HG and PT volumes in this study.

COMMENT

Left PT gray matter volume was significantly reduced in first-episode patients with schizophrenia compared with controls (20.0%) and first-episode patients with manic psychosis (20.0%). Bilateral HG gray matter volume was also reduced in patients with schizophrenia compared with controls and patients with mania.

The present data are consistent with our earlier findings of left-lateralized volume reduction in posterior STG gray matter in both chronic and first-episode schizophrenia^{23,33} and enlarges the finding, since the region studied previously was only partially coextensive with PT. These data are also consistent with left PT gray matter volume reduction (28.2%) in patients with chronic schizophrenia.⁶ The present findings suggest that lateralized PT reductions are not due to confounds of long-term medication use or disorder chronicity and that abnormal left PT and

bilateral HG gray matter volumes are present at time of first hospitalization and are specific to schizophrenia.

Musiek and Reeves²⁰ reported an asymmetrical length of HG (left greater than right) in healthy subjects. However, findings have been inconsistent in MRI studies of schizophrenia.^{7,12,14} Rojas and coworkers,²¹ for example, reported a left HG volume greater than the right in controls and patients diagnosed as having paranoid schizophrenia. The present results indicate an asymmetry of HG in all groups but also suggest bilateral HG reduction in the schizophrenia group. This raises the interesting question of primary auditory sensory deficits in schizophrenia, a question not yet completely investigated. For example, Holcomb and coworkers³⁹ have documented that patients with schizophrenia have more difficulty than controls in differentiating high and low tones presented against a background of noise, and these patients often also show deficits in mismatch negativity, an electrophysiological index of echoic memory processes.^{40,41}

In the present study, clinical measures and ROIs were not significantly correlated. In patients with chronic disease, left anterior STG volume reduction has been reported to correlate with auditory hallucinations,⁴² and left posterior STG volume reduction has been reported to correlate with severity of thought disorder.^{4,33} Moreover, our laboratory found the suspiciousness/persecution sub-scale score of the Positive and Negative Syndrome Scale was associated with reduced left PT volume in patients diagnosed as having chronic schizophrenia.⁶ Correlations between clinical measures and reduced volumes in patients with chronic schizophrenia have been reported by several investigators.^{36,43,44} However, few MRI studies^{45,46} of first-episode schizophrenia have reported an association between structural abnormalities and symptoms. We suggest that at the time of first hospitalization symptom-MRI correlations might be less than in chronic schizophrenia because of either a lack of stability in psychiatric symptoms or an absence of more marked structural alterations.

The specificity of MRI abnormalities to schizophrenic vs affective psychosis is a long-standing conundrum, as is the more general question of whether these psychoses are manifestations of a single disorder. Our previous report indicated that volume reduction in left posterior STG gray matter was specific to schizophrenia, although volume reduction of the posterior amygdala-hippocampal complex was not different between patients diagnosed as having first-episode schizophrenia and patients diagnosed as having first-episode bipolar mania. A recent report by Velakoulis et al⁴⁷ also showed left hippocampal volume reduction in first-episode schizophrenia and schizophreniform psychosis compared with healthy subjects, but, once again, no differences were reported between first-episode schizophrenia and first-episode affective psychosis. These findings suggest that abnormalities in left STG gray matter, including PT and HG, are specific to schizophrenic psychosis, in contrast to abnormalities in medial temporal structures. Furthermore, Schlaepfer et al⁴³ reported that patients with bipolar disorder did not show heteromodal cerebral cortex volume reduction, whereas gray matter volume was reduced in patients with schizophrenia. More specifically, asymmetry reversal was reported for posterior STG in patients diagnosed as having schizophrenia but not in patients diagnosed as having bipolar disorder.²⁴ Zipursky et al⁴⁸ similarly found global volume reduction in gray matter in first-episode psychotic patients but not in first-episode affective psychotic patients. Harvey et al⁴⁹ also reported a decrease in cortical volume in patients with schizophrenia but not in patients with bipolar disorder. Since we have not investigated frontal or parietal cortex, 2 other areas possibly implicated in schizophrenic and affective pathology,^{1,2} conclusions drawn herein about specificity apply only to the regions we have studied.

There are several caveats to this study. First, the sex distribution of our sample did not allow us to investigate this variable. We anticipate doing so in the future. Second, a previous study by our group failed to show a significant volume difference in HG between patients with

chronic schizophrenia and controls.⁶ One possible reason may be that different methods were used. In the previous study, post-MRI realignment was not performed, whereas in the present study we used a newly developed postrealignment procedure and a new method for resampling of voxels. When we evaluated the 2 methods, with and without realignment before ROI tracing (N=10; 5 patients with schizophrenia and 5 controls), we found no significant volume difference between the 2 methods for PT or HG in either schizophrenic patients or control subjects. We also found no differences in intraclass correlation coefficients between the 2 methods. A more likely explanation for the difference in HG and PT in this study, but for only PT in our previous study, might be the differences in the samples. Third, operationalizing first episode as time of first hospitalization rather than as time of prodromal symptom onset may overestimate age at onset yet provides an unequivocal measure. First hospitalization is used synonymously with first episode in virtually all the literature. We have also provided time of first medication use, which may help to clarify the clinical picture for patients with significant symptoms before hospitalization.

In conclusion, our findings of volume reduction in PT and HG in first-episode schizophrenia suggest the presence of structural abnormalities in regions associated with auditory processing and language. Finally, we suggest that studies of patients with recent-onset disease provide a major advantage in having fewer confounds from chronicity variables and, additionally, offer a baseline for longitudinal studies evaluating the presence or absence of progression of MRI changes over time.

SUBJECTS AND METHODS

SUBJECTS

Patients were inpatients at McLean Hospital, a private psychiatric hospital in Belmont, Mass. Thirty-five psychotic patients were tested within 2 weeks of their first hospitalization, 8 within 4 months of first hospitalization, and 1 within 11 months. Patients and control subjects met criteria for age (18–55 years), IQ above 75, right-handedness,²⁵ negative history of seizures, head trauma with loss of consciousness, neurologic disorder, and no lifetime history of alcohol or other drug dependence. Control subjects had no Axis I mental disorder nor did their first-degree relatives (self-report).

Patients were diagnosed using the Structured Clinical Interview for *DSM-III-R* (SCID),²⁶ a review of hospital course, and medical records. The study group consisted of 20 patients with schizophrenia (16 men, 4 women) and 24 patients with bipolar disorder mania with psychotic features (18 men, 6 women). All patients manifested psychosis at the time of the study. More specifically, 6 patients with schizophrenia had hallucinations, paranoia, ideas of reference, and delusions; 1 had hallucinations, delusions, and ideas of reference; 2 had hallucinations, paranoia, and ideas of reference; 2 had hallucinations and delusions; 2 had delusions and paranoia; 2 had hallucinations and paranoia; 2 had only hallucinations; and 3 had only delusions. Two patients with mania had hallucinations, paranoia, ideas of reference, and delusions; 5 had hallucinations, delusions, and ideas of reference; 2 had hallucinations, paranoia, and delusions; 1 had hallucinations and delusions; 1 had hallucinations and ideas of reference; 2 had delusions and paranoia; 5 had delusions and ideas of reference; 5 had only delusions; and 1 had only paranoia. Diagnoses were confirmed at 1-year follow-up. The median duration of psychotropic medication use before MRI was short (Table 1). In addition, duration of medication use and dosage of medication were not significantly correlated with any MRI volumes. In terms of operationalizing onset of psychosis, we selected date of first psychiatric hospitalization. Although onset of prodromal symptoms may be a better indicator of actual onset of disease, in practice this retrospective measure is difficult to verify. For comparative purposes, we provided age at time of first medication use, which we believe to be more objective (most dates were from hospital

records) and nonequivocal than prodrome onset and thus possibly a better estimate of symptom onset. A group of 22 control subjects (SCID nonpatient edition²⁷ and SCID-II²⁸; 20 men, 2 women), group matched for age, was recruited through newspaper advertisements. The present study reflects an increase in sample size (N=64) over our previous study (N=46)²³ and presents new, more detailed measures of posterior STG anatomy, partially but not completely coextensive with our previous measures of posterior STG.

The Mini-Mental State Examination was used to rule out dementia or delirium. In addition, the information sub-scale of the Wechsler Adult Intelligence Scale–Revised²⁹ was used to estimate general information, and the digits-forward and -backward subscales of the Wechsler Adult Intelligence Scale–Revised were used to evaluate immediate and short-term memory, attention, and concentration. Socioeconomic status (SES) and parental SES³⁰ were also assessed. Psychosis was further evaluated using the Brief Psychiatric Rating Scale (BPRS).³¹ Social functioning was evaluated using the Global Assessment Scale³² (Table 1). After a complete description of the study, written informed consent was obtained from all subjects. Subjects were paid for participating.

MRI ACQUISITION PROTOCOL AND MRI POSTPROCESSING

The MRIs were obtained on a 1.5-T scanner (General Electric Scanner; GE Medical Systems, Milwaukee, Wis). Details concerning pulse sequences are provided elsewhere.^{33–35} Briefly, there were 2 MRI protocols. The first was a coronal series of contiguous images (repetition time=35 milliseconds, echo time=5 milliseconds, 1 repetition, 45° nutation angle, 24-cm field of view, number of excitations = 1.0, matrix=256×256[192 phase encoding steps]×124). Voxel (volume of pixel) dimensions were 0.9375×0.9375×1.5 mm. Data were reformatted in the coronal plane and analyzed as 124 coronal 1.5-mm-thick slices. This protocol was used to measure PT and HG. The second was an axial series of contiguous double echo (proton density and T2-weighted) images (repetition time=3000 milliseconds, echo time=30 and 80 milliseconds, 24-cm field of view, an interleaved acquisition with 3-mm slice thickness). Voxel dimensions were 0.9375×0.9375×3 mm. This latter protocol was used to evaluate total intracranial volume. To reduce flow-related artifacts and to obtain low arterial signal intensity, presaturation of a slab inferior to the head was performed in both the axial and coronal acquisitions. A semiautomated segmentation procedure³³ was used on the axial slices to measure total intracranial content (ICC), including overall gray matter, white matter, and cerebrospinal fluid. An anisotropic diffusion filter was applied to reduce noise before processing each set of scans.³⁵

REALIGNMENT AND RESAMPLING PROCESS

Following acquisition, MRIs were aligned using the inter-hemispheric fissure in the anterior two thirds of the brain in the coronal and axial planes. After this alignment in 2 planes, the midsagittal plane was aligned to correct head tilt using the line between the anterior and posterior commissures. Images were also resampled using an algorithm to make them isotropic, with sides measuring 0.9375 mm. Comparisons in 5 patients with schizophrenia and 5 healthy subjects showed that this process did not alter either measured region of interest (ROI) volumes or segmentation values for gray matter, white matter, or cerebrospinal fluid.

DEFINITION OF HG AND PT

The ROI definitions for both PT and HG have been described in detail by us in a recent study.⁶ In the present study, we used criteria similar to both our previous work and to the work of Barta et al¹⁹ for delineating HG and PT. We defined HG as the first transverse gyrus commencing from a point at the posterior margin of the insula next to the end of an opercular branch of the postcentral gyrus, then traversing anterolaterally to the superior

aspect of the temporal lobe and terminating at the lateral border of STG. If there was an initial single gyral origin of HG, and then bifurcation into branches, both branches were defined as HG.

Briefly summarized, our ROI definition procedure involved first using axial MRIs for manually outlining HG. The marked voxels defining the axial HG outlines, once reformatted, helped to accurately pinpoint the location of HG on the coronal images, with HG tracing proceeding from the most posterior coronal image with a mark to the most anterior. In between these bounds, we manually outlined HG gray matter. As the Heschl sulcus reached the lateral border of STG, we included only the edge of gray matter of HG superior to the level of the white matter, ie, the roof of the white matter of STG was the inferior boundary of HG gray matter, and the most lateral extension of white matter formed the lateral bound of HG. Finally, sagittal MRIs were used to check and confirm HG boundaries.

The anterior border of PT was defined by the posterior border of HG. The lateral border of PT was defined as the superolateral margin of STG, with the gray matter underneath being manually outlined. Posteriorly, PT gray matter was traced to the end of the sylvian fissure, as seen on coronal images, and then gray matter of the ascending ramus of the sylvian fissure was also included. Thus, our definition of the PT included PT proper and its parietal extension. Both PT and HG ROIs could then be viewed as 3-dimensional objects for any further editing (Figure 1).

Interrater reliability was computed for the ROIs by 3 independent raters (Y.H., S.T., and D.S.) who were blind to group membership. Ten cases were randomly selected for interrater reliability. An intraclass correlation coefficient was used to compute interrater reliability based on the 3 raters: 0.882 (left HG), 0.881 (right HG), 0.985 (left PT), and 0.950 (right PT).

STATISTICAL ANALYSES

One-way analysis of variance was used to test for group differences in age, SES, and parental SES. In addition, *t* tests were used to assess group differences in clinical measures, age of first medication use, and medication dose and duration of use. Tests for group differences in ICC were conducted with a 1-way analysis of covariance (ANCOVA), with age and parental SES as covariates.

For ROI analysis we used a mixed-model ANCOVA, using relative volumes with 1 between-subjects factor (group: schizophrenia, mania, or controls) and 2 within-subjects factors (side: left and right; region: HG and PT). Age and parental SES were used as covariates for all ANCOVAs. Follow-up analyses included a 2-factor (group and side) ANCOVA for each region (HG and PT), 1-way ANCOVA, and post hoc Tukey Honestly Significant Difference tests for individual regions, with left and right compared separately. For the analyses used herein, we used relative volumes of ROI computed as [(absolute ROI volume)/(ICC)] × 100. Adjusting for brain size by linear regression of absolute volumes on ICC and using the residuals for comparisons did not change the results reported herein (see Zipursky et al³⁶ and Dickey et al³⁷ for examples of this procedure).

Exploratory analyses of the relationship between absolute volumes of PT and HG and the 4 syndrome factors of the BPRS,³⁸ as well as for each BPRS item, were evaluated using Spearman rho.

Acknowledgments

This work was supported in part by grants NIMH 01110 and 50747 (Dr Shenton) and NIMH 40977 (Dr McCarley) from the National Institute of Mental Health, Rockville, Md; by MERIT and Schizophrenia Center Awards from the

Department of Veterans Affairs Medical Research Service, Washington, DC (Dr McCarley); by a National Alliance for Research on Schizophrenia and Depression Young Investigator Award (Dr Salisbury); and by a Neuroimaging Analysis Center Biomedical Technology Resource grant (P41 RR13218-01) and Core Segmentation Tools for Computer Assisted Surgery grant (1R01 RR11747-01A) (Drs Kikinis and Jolesz).

References

1. Shenton, ME.; Wible, CG.; McCarley, RW. A review of magnetic resonance imaging studies of brain abnormalities in schizophrenia. In: Krishnan, KRR.; Doraiswamy, PM., editors. *Brain Imaging in Clinical Psychiatry*. New York, NY: Marcel Dekker Inc; 1997. p. 297-380.
2. McCarley RW, Wible CG, Frumin M, Hirayasu Y, Levitt JJ, Fischer IA, Shenton ME. MRI anatomy of schizophrenia. *Biol Psychiatry* 1999;45:1099–1119. [PubMed: 10331102]
3. Shenton, ME.; Frumin, M.; McCarley, RW.; Maier, S.; Westin, CF.; Fischer, IA.; Dickey, CC.; Kikinis, R. MR morphometric findings in schizophrenia. In: Dougherty, D.; Rauch, S.; Rosenbaum, J., editors. *Psychiatric Neuroimaging Strategies: Research and Clinical Applications*. Washington, DC: American Psychiatric Association; 2000.
4. Pearlson GD, Marsh L. Structural brain imaging in schizophrenia: a selective review. *Biol Psychiatry* 1999;46:627–649. [PubMed: 10472416]
5. Marsh L, Suddath RL, Higgins N, Weinberger DR. Medial temporal lobe structures in schizophrenia: relationship of size to duration of illness. *Schizophr Res* 1994;11:225–238. [PubMed: 8193061]
6. Kwon J-S, McCarley RW, Hirayasu Y, Anderson JE, Fischer IA, Kikinis R, Jolesz FA, Shenton ME. Left planum temporale volume reduction in schizophrenia. *Arch Gen Psychiatry* 1999;56:142–148. [PubMed: 10025438]
7. Petty RG, Barta PE, Pearlson GD, McGilchrist IK, Lewis RW, Tien AY, Pulver A, Vaughn DD, Casanova MF, Powers RE. Reversal of asymmetry of the planum temporale in schizophrenia. *Am J Psychiatry* 1995;152:715–721. [PubMed: 7726311]
8. Rossi A, Serio A, Stratta P, Petruzzi C, Schiazza G, Mancini F, Casacchia M. Planum temporale asymmetry and thought disorder in schizophrenia. *Schizophr Res* 1994;12:1–7. [PubMed: 8018581]
9. Jacobsen LK, Giedd JN, Tanrikut C, Brady DR, Donohue BC, Hamburger SD, Kumra S, Alagband-Rad J, Rumsey JM, Rapoport JL. Three-dimensional cortical morphometry of the planum temporale in childhood-onset schizophrenia. *Am J Psychiatry* 1997;154:685–687. [PubMed: 9137128]
10. DeLisi LE, Hoff AL, Neale C, Kushner M. Asymmetries in the superior temporal lobe in male and female first-episode schizophrenic patients: measures of the planum temporale and superior temporal gyrus by MRI. *Schizophr Res* 1994;12:19–28. [PubMed: 8018582]
11. Kleinschmidt A, Falkai P, Huang Y, Schneider T, Furst G, Steinmetz H. In vivo morphometry of planum temporale asymmetry in first-episode schizophrenia. *Schizophr Res* 1994;12:9–18. [PubMed: 8018589]
12. Kulynych JJ, Vladar K, Fantie BD, Jones DW, Weinberger DR. Normal asymmetry of the planum temporale in patients with schizophrenia: three-dimensional cortical morphometry with MRI. *Br J Psychiatry* 1995;166:742–749. [PubMed: 7663822]
13. Frangou S, Sharma T, Sigmudsson T, Barta P, Pearlson G, Murray RM. The Maudsley Family Study, 4: normal planum temporale asymmetry in familial schizophrenia: a volumetric MRI study. *Br J Psychiatry* 1997;170:328–333. [PubMed: 9246250]
14. Barta PE, Pearlson GD, Brill LB II, Royall R, McGilchrist IK, Pulver AE, Powers RE, Casanova MF, Tien AY, Frangou S, Petty RG. Planum temporale asymmetry reversal in schizophrenia: replication and relationship to gray matter abnormalities. *Am J Psychiatry* 1997;154:661–667. [PubMed: 9137122]
15. Galaburda AM, Corsiglia J, Rosen GD, Sherman GF. Planum temporale asymmetry, reappraisal since Geschwind and Levitsky. *Neuropsychologia* 1987;25:853–868.
16. Geschwind N, Levitsky W. Human brain: left-right asymmetries in temporal speech region. *Science* 1968;161:186–187. [PubMed: 5657070]
17. Witelson SF, Pallie W. Left hemisphere specialization for language in the newborn: neuroanatomical evidence of asymmetry. *Brain* 1973;96:641–646. [PubMed: 4795531]

18. Falkai P, Bogerts B, Schneider T, Greve B, Pfeiffer U, Pilz K, Gonsiorczyk C, Majtenyi C, Ovary I. Disturbed planum temporale asymmetry in schizophrenia: a quantitative post-mortem study. *Schizophr Res* 1995;14:161–176. [PubMed: 7710997]
19. Barta PE, Petty RG, McGilchrist I, Lewis RW, Jerram M, Casanova MF, Powers RE, Brill LB II, Pearlson GD. Asymmetry of the planum temporale: methodological considerations and clinical associations. *Psychiatry Res Neuroimaging* 1995;61:137–150.
20. Musiek FE, Reeves AG. Asymmetries of the auditory areas of the cerebrum. *J Am Acad Audiol* 1990;1:240–245. [PubMed: 2132609]
21. Rojas DC, Teale P, Sheeder J, Simon J, Reite M. Sex-specific expression of Heschl's gyrus functional and structural abnormalities in paranoid schizophrenia. *Am J Psychiatry* 1997;154:1655–1662. [PubMed: 9396942]
22. Crow TJ. The two-syndrome concept: origins and current status. *Schizophr Bull* 1985;11:471–486. [PubMed: 2863873]
23. Hirayasu Y, Shenton ME, Salisbury DF, Dickey CC, Fischer IA, Mazzoni P, Kisler T, Arakaki H, Kwon JS, Anderson JE, Yurgelun T, Tohen M, McCarley RW. Lower left temporal lobe MRI volumes in patients with first-episode schizophrenia compared with psychotic patients with first-episode affective disorder and normal subjects. *Am J Psychiatry* 1998;155:1384–1391. [PubMed: 9766770]
24. Pearlson GD, Barta PE, Powers RE, Menon RR, Richards SS, Aylward H, Federman B, Chase GA, Petty RG, Tien AY. Medial and superior temporal gyrus volumes and cerebral asymmetry in schizophrenia versus bipolar disorder. *Biol Psychiatry* 1997;41:1–14. [PubMed: 8988790]
25. Oldfield RC. The assessment and analysis of handedness: The Edinburg Inventory. *Neuropsychologia* 1971;9:97–113. [PubMed: 5146491]
26. Spitzer, RL.; Williams, JBW.; Gibbon, M.; First, M. The Structured Clinical Interview for DSM-III-R (SCID). Washington, DC: American Psychiatric Association; 1990.
27. Spitzer, RL.; Williams, JBW.; Gibbon, M.; First, M. The Structured Clinical Interview for DSM-III-R (SCID-NP)—Non-Patient Edition. Washington, DC: American Psychiatric Association; 1990.
28. Spitzer, RL.; Williams, JBW.; Gibbon, M.; First, M. The Structured Clinical Interview for DSM-III-R (SCID-II)—Personality Disorders. Washington, DC: American Psychiatric Association; 1990.
29. Wechsler, D. Wechsler Adult Intelligence Scale—Revised. New York, NY: Harcourt Brace Jovanovich Inc; 1981.
30. Hollingshead, AB. Two Factor Index of Social Position. New Haven, Conn: Yale University Press; 1965.
31. Overall JE, Gorham DR. The Brief Psychiatric Rating Scale. *Psychol Rep* 1962;10:799–812.
32. Endicott J, Spitzer RL, Fleiss JL, Cohen J. The Global Assessment Scale: a procedure for measuring overall severity of psychiatric disturbance. *Arch Gen Psychiatry* 1976;33:766–771. [PubMed: 938196]
33. Shenton ME, Kikinis R, Jolesz FA, Pollak SD, LeMay M, Wible CG, Hokama H, Martin J, Metcalf D, Coleman M, McCarley RW. Abnormalities of the left temporal lobe and thought disorder in schizophrenia: a quantitative magnetic resonance imaging study. *N Engl J Med* 1992;327:604–612. [PubMed: 1640954]
34. Shenton ME, Kikinis R, McCarley RW, Metcalf D, Tieman J, Jolesz FA. Application of automated MRI volumetric measurement techniques to the ventricular system in schizophrenics and normal controls. *Schizophr Res* 1991;5:103–113. [PubMed: 1931803]
35. Kikinis, R.; Jolesz, FA.; Gerig, G. 3D morphometric and morphometric information derived from clinical brain MR images. In: Hohne, KH.; Fuchs, H.; Pizer, SM., editors. *3D Imaging in Medicine*. Berlin, Germany: Springer-Verlag; 1990. p. 441-454.
36. Zipursky RB, Marsh L, Lim KO, DeMent S, Shear PK, Sullivan EV, Murphy GM, Csernansky JG, Pfefferbaum A. Volumetric MRI assessment of temporal lobe structures in schizophrenia. *Biol Psychiatry* 1994;35:501–516. [PubMed: 8038294]
37. Dickey CC, McCarley RW, Voglmaier M, Niznikiewicz M, Seidman LJ, Hirayasu Y, Fischer IA, Teh E, Rhoads RV, Jakab M, Kikinis R, Jolesz FA, Shenton ME. Schizotypal personality disorder and MRI abnormalities of temporal lobe gray matter. *Biol Psychiatry* 1999;45:1393–1402. [PubMed: 10356620]

38. Kay, SR.; Opler, LA.; Fiszbein, A. Positive and Negative Syndrome Scale Manual. North Tonawanda, NY: Multi-Health Systems; 1992.
39. Holcomb HH, Ritzl EK, Medoff DR, Nevitt J, Gordon B, Tamminga CA. Tone discrimination performance in schizophrenic patients and normal volunteers: impact of stimulus presentation levels and frequency differences. *Psychiatry Res* 1995;57:75–82. [PubMed: 7568562]
40. Javitt DC, Doneshka P, Grochowski S, Ritter W. Impaired mismatch negativity generation reflects widespread dysfunction of working memory in schizophrenia. *Arch Gen Psychiatry* 1995;52:550–558. [PubMed: 7598631]
41. Hirayasu Y, Potts GF, O'Donnell BF, Kwon J, Arakaki H, Akdag SJ, Levitt JJ, McCarley RW. Auditory mismatch negativity in schizophrenia: topographic evaluation with a high density recording montage. *Am J Psychiatry* 1998;155:1281–1284. [PubMed: 9734556]
42. Barta PE, Pearlson GD, Powers RE, Richards SS, Tune LE. Auditory hallucinations and smaller superior temporal gyral volume in schizophrenia. *Am J Psychiatry* 1990;147:1457–1462. [PubMed: 2221156]
43. Schlaepfer TE, Harris GJ, Tien AY, Peng LW, Lee S, Federman EB, Chase GA, Barta PE, Pearlson GD. Decreased regional cortical gray matter volume in schizophrenia. *Am J Psychiatry* 1994;151:842–848. [PubMed: 8184992]
44. Flaum M, Swayze VW II, O'Leary DS, Yuh WT, Ehrhardt JC, Arndt SV, Andreasen NC. Effects of diagnosis, laterality, and gender on brain morphology in schizophrenia. *Am J Psychiatry* 1995;152:704–714. [PubMed: 7726310]
45. Degreef G, Ashtari M, Bogerts B, Bilder RM, Jody DN, Alvir JM, Lieberman JA. Volumes of ventricular system subdivisions measured from magnetic resonance images in first-episode schizophrenic patients. *Arch Gen Psychiatry* 1992;49:531–537. [PubMed: 1627044]
46. Bilder RM, Wu H, Bogerts B, Degreef G, Ashtari M, Alvir JM, Snyder PJ, Lieberman JA. Absence of regional hemispheric volume asymmetries in first-episode schizophrenia. *Am J Psychiatry* 1994;151:1437–1447. [PubMed: 8092337]
47. Velakoulis D, Pantelis C, McGorry PD, Dudgeon P, Brewer W, Cook M, Desmond P, Bridle N, Tierney P, Murrie V, Singh B, Copolov D. Hippocampal volume in first-episode psychoses and chronic schizophrenia: a high-resolution magnetic resonance imaging study. *Arch Gen Psychiatry* 1999;56:133–141. [PubMed: 10025437]
48. Zipursky RB, Seeman MV, Bury A, Langevin R, Wortzman G, Katz R. Deficits in gray matter volume are present in schizophrenia but not bipolar disorder. *Schizophr Res* 1997;26:85–92. [PubMed: 9323337]
49. Harvey I, Persaud R, Ron MA, Baker G, Murray RM. Volumetric MRI measurements in bipolars compared with schizophrenics and healthy controls. *Psychol Med* 1994;24:689–699. [PubMed: 7991751]

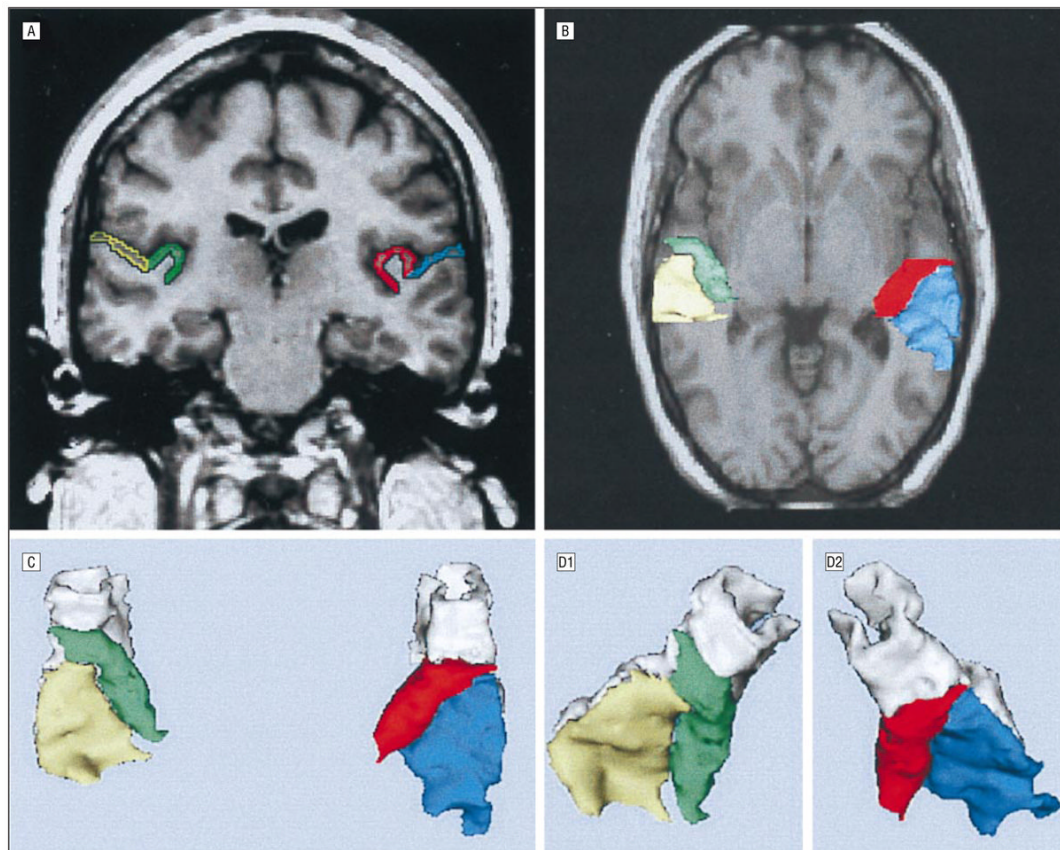


Figure 1.

A, Coronal slice (1.5 mm) through the temporal lobe of a healthy control subject. The regions of interest for the structures are outlined: the gray matter of Heschl gyrus (HG) is red on subject left and green on subject right. The gray matter of planum temporale (PT) is labeled yellow on subject left and blue on subject right. B, Top-down view of the 3-dimensional reconstruction of HG and PT placed on top of an axial magnetic resonance imaging slice. Anterior is top. The HG is red on subject left and green on subject right, and PT is blue on subject left and yellow on subject right. C, Three-dimensional reconstruction of the left and right regions of interest, color coded as in section B but from a slightly different angle of rotation from that in section B. Note the tubular structure of the gray matter of the superior temporal gyrus, most clearly seen anteriorly, where gray codes non-HG, non-PT portions of superior temporal gyrus. D, Three-dimensional reconstructions viewed from a different angle from that in section C (D1 is subject right and D2 is subject left).

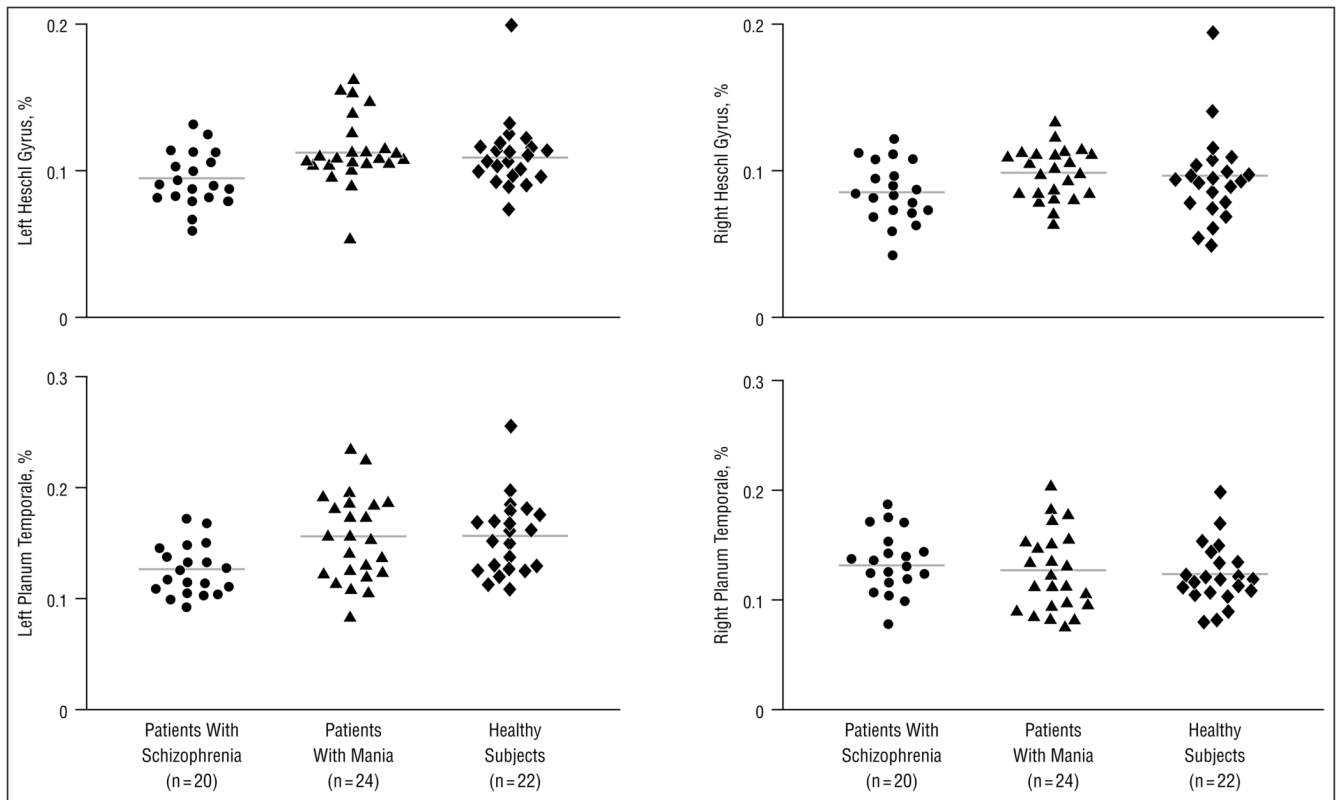


Figure 2. Relative volume of the Heschl gyrus and planum temporale in patients with first-episode schizophrenia, patients with first-episode mania, and healthy control subjects. Horizontal lines represent means.

Table 1

Subjects' Characteristics and Test Scores*

Variable	Patients With Schizophrenia (n = 20)	Patients With Mania (n = 24)	Healthy Subjects (n = 22)	df	F or t Values	P†
Age, mean ± SD (range), y	27.3 ± 7.0 (18–41)	23.6 ± 5.0 (19–41)	24.5 ± 4.7 (18–35)	2, 63	2.56	.08
Male/female	16/4	18/6	20/2
Handedness, mean ± SD	0.7 ± 0.1	0.7 ± 0.2	0.8 ± 0.2	2, 63	0.84	.44
SES, mean ± SD‡	3.3 ± 1.2§	2.5 ± 1.1	1.9 ± 0.6	2, 63	9.30	<.001
Parental SES, mean ± SD‡	2.1 ± 0.9§	1.4 ± 0.7	1.4 ± 0.8	2, 63	4.57	.01
MMSE score, mean ± SD	28.5 ± 2.7	28.7 ± 1.6	29.0 ± 1.2	2, 63	0.82	.44
WAIS-R score, mean ± SD						
Information	20.5 ± 6.3	20.5 ± 4.8	23.2 ± 3.1	2, 63	2.56	.08
Digits-forward	8.4 ± 2.2	8.1 ± 1.7	9.5 ± 2.6	2, 63	3.16	.05
Digits-backward	6.7 ± 2.7	6.3 ± 2.2	8.1 ± 2.8	2, 63	2.84	.07
GAS score, mean ± SD	36.3 ± 12.4	35.1 ± 10.4	...	43	0.34	.74
Age first medicated, mean ± SD, y	27.3 ± 7.1	23.7 ± 5.4	...	43	1.78	.08
Median duration (range) of medication use, mo	1.7 (0–18.8)	0 (0–18.8)
Medication dose (CPZ equiv), mean ± SD	249.4 ± 203.4	198.5 ± 171.0	...	43	0.84	.41
BPRS score, mean ± SD	36.8 ± 9.6	36.2 ± 11.7	...	43	0.20	.84

* SES indicates socioeconomic status; MMSE, Mini-Mental State Examination; WAIS-R, Wechsler Adult Intelligence Scale-Revised; GAS, Global Assessment Scale; CPZ equiv, chlorpromazine equivalent; BPRS, Brief Psychiatric Rating Scale; and ellipses, data not applicable. Handedness was assessed by a modified Oldfield Inventory (Oldfield, 1971), right-handed being above 0.

† Statistical significance was determined by a 1-factor analysis of variance.

‡ Higher scores indicate lower SES.

§ Post hoc Tukey Honestly Significant Difference test showed significant difference ($P < .05$) compared with patients with mania and comparison subjects.

Table 2
 Absolute and Relative Volumes of Regions of Interest of Heschl Gyrus and Planum Temporale*

Region	Absolute Volume, mL (Relative Volume, %)				df	F	P
	Patients With Schizophrenia (n = 20)	Patients With Mania (n = 24)	Healthy Subjects (n = 22)				
Total ICC	1512 ± 97	1454 ± 140	1546 ± 161		2, 61	2.63	.08
Left planum temporale	1.88 ± 0.39 [†] (0.09 ± 0.02)	2.23 ± 0.55 (0.16 ± 0.04)	2.40 ± 0.63 (0.16 ± 0.03)		2, 60	4.20	.02
Right planum temporale	2.01 ± 0.48 (0.13 ± 0.03)	1.80 ± 0.46 (0.13 ± 0.04)	1.88 ± 0.48 (0.12 ± 0.03)		2, 60	1.21	.30
Left Heschl gyrus	1.42 ± 0.28 (0.09 ± 0.02)	1.68 ± 0.38 (0.12 ± 0.02)	1.73 ± 0.46 (0.11 ± 0.02)		2, 60	1.96	.15
Right Heschl gyrus	1.28 ± 0.32 (0.08 ± 0.02)	1.43 ± 0.29 (0.10 ± 0.02)	1.44 ± 0.46 (0.09 ± 0.03)		2, 60	2.07	.14
					2, 61	2.49	.09

* Data are given as mean ± SD. Statistical significance levels are based on 1-factor analysis of covariance (ANCOVA). The df of ANCOVA varies because there are 2 covariates for intracranial contents (ICC) (age and parental socioeconomic status) and 3 covariates for absolute volumes (ICC, age, and parental socioeconomic status). The text uses relative volumes for statistical significance measures, but absolute volumes are also presented here for comparison purposes.

[†] Post hoc Tukey Honestly Significant Difference tests indicated that patients with schizophrenia were significantly different from patients with mania and comparison subjects.