



Löffler syndrome on a Louisiana pig farm

Citation

Gipson, Kevin, Ryan Avery, Heena Shah, Derek Pepiak, Rodolfo E. Bégué, John Malone, and Luke A. Wall. 2016. "Löffler syndrome on a Louisiana pig farm." *Respiratory Medicine Case Reports* 19 (1): 128-131. doi:10.1016/j.rmcr.2016.09.003. <http://dx.doi.org/10.1016/j.rmcr.2016.09.003>.

Published Version

doi:10.1016/j.rmcr.2016.09.003

Permanent link

<http://nrs.harvard.edu/urn-3:HUL.InstRepos:29408175>

Terms of Use

This article was downloaded from Harvard University's DASH repository, and is made available under the terms and conditions applicable to Other Posted Material, as set forth at <http://nrs.harvard.edu/urn-3:HUL.InstRepos:dash.current.terms-of-use#LAA>

Share Your Story

The Harvard community has made this article openly available.
Please share how this access benefits you. [Submit a story](#).

[Accessibility](#)



Case report

Löffler syndrome on a Louisiana pig farm



Kevin Gipson^a, Ryan Avery^b, Heena Shah^c, Derek Pepiak^d, Rodolfo E. Bégué^e,
John Malone^b, Luke A. Wall^{c,*}

^a Division of Pediatric Pulmonology, Department of Pediatrics, Massachusetts General Hospital and Harvard Medical School, Boston, MA, USA

^b Louisiana State University School of Veterinary Medicine, Department of Pathobiological Sciences, Baton Rouge, LA, USA

^c Section of Allergy Immunology, Department of Pediatrics, Louisiana State University Health Sciences Center and Children's Hospital New Orleans, New Orleans, LA, USA

^d Division of Pediatric Pulmonology, Department of Pediatrics, Ochsner for Children and the University of Queensland School of Medicine, New Orleans, LA, USA

^e Section of Infectious Diseases, Department of Pediatrics, Louisiana State University Health Sciences Center and Children's Hospital New Orleans, New Orleans, LA, USA

ARTICLE INFO

Article history:

Received 7 September 2016

Received in revised form

14 September 2016

Accepted 15 September 2016

Keywords:

Löffler syndrome

Pediatric pulmonology

Pulmonary eosinophilia

Ascaris suum

Onychophagia

ABSTRACT

Löffler syndrome, a fulminant eosinophilic pneumonitis associated with the larval migratory phase of human parasites, is rarely reported in the United States. A previously healthy 8-year-old male was hospitalized with tachypnea, cough, hypoxemia, and fever of one week's duration. History revealed exposure to pigs on his family's farm in southernmost Louisiana, where the patient was responsible for cleaning the farm's pigpens. His fingernails were soiled and extremely short, with the edge of the nail bed exposed secondary to onychophagia. Laboratory evaluation demonstrated peripheral eosinophilia (39%), pulmonary eosinophilia (86%), high total IgE, diffuse reticulonodular lung opacities, and mixed obstructive and restrictive pulmonary function pattern. Systemic corticosteroids were initiated for his acute respiratory insufficiency and produced rapid clinical improvement. Serum *Ascaris*-specific IgE was markedly elevated and he was treated with albendazole. An extensive evaluation for other infectious and allergic etiologies was negative. A site visit to the family farm and laboratory investigation was coordinated with the Louisiana Animal Disease Diagnostic Laboratory at LSU. *Ascaris suum* eggs were detected in fresh pig feces and in the soil immediately surrounding the pens. Ascariasis should be considered even in the absence of travel history, especially in swine raising areas that are endemic for *Ascaris* in pigs, such as the southeastern United States. Onychophagia is a highly probable mechanism of zoonotic fecal-oral transmission in this case, and such habits could lead to continual reinfection. Systemic corticosteroids were effective in treating the patient's acute respiratory compromise due to Löffler syndrome.

© 2016 The Authors. Published by Elsevier Ltd. This is an open access article under the CC BY-NC-ND license (<http://creativecommons.org/licenses/by-nc-nd/4.0/>).

1. Case description

A previously healthy 8-year-old boy presented to the ED of an outside hospital complaining of fatigue and intermittent tachypnea for one week, and fever as high as 39.4 °C for 3 days. A chest radiograph showed interstitial lung infiltrates, and the patient was

discharged on azithromycin and albuterol, with instructions to present to our Pediatric Pulmonology clinic the following day. In our clinic, the patient was found to be tachypneic, tachycardic, and hypoxemic with a SpO₂ of 85% on room air. Physical exam was notable for supraclavicular retractions and sparse rales, and chest imaging demonstrated diffuse reticulonodular lung opacities (Figs. 1a and 2). He was hospitalized and treated with supplemental oxygen, intravenous methylprednisolone, and nebulized albuterol. Initial laboratory values showed elevated white blood cell count (32,500 cells/μL) with absolute eosinophilia (12,700 cells/μL, or 39% of total white cell count), and an elevated serum IgE (3480 IU/mL). His symptoms quickly improved, with resolution of his oxygen requirement by day 3 of hospitalization. On that day he underwent bronchoalveolar lavage, which demonstrated fluid containing 601

Abbreviations: BAL, Broncho-alveolar lavage; ED, emergency department; FEF, forced expiratory flow; FEV₁, forced expiratory volume in 1 second; FVC, forced vital capacity; LPM, liter per minute; LSU, Louisiana State University; RV, residual volume; TLC, total lung capacity.

* Corresponding author. Department of Pediatrics, Children's Hospital New Orleans, 200 Henry Clay Ave, New Orleans LA 70118, USA.

E-mail address: lwall@lsuhsc.edu (L.A. Wall).

<http://dx.doi.org/10.1016/j.rmcr.2016.09.003>

2213-0071/© 2016 The Authors. Published by Elsevier Ltd. This is an open access article under the CC BY-NC-ND license (<http://creativecommons.org/licenses/by-nc-nd/4.0/>).

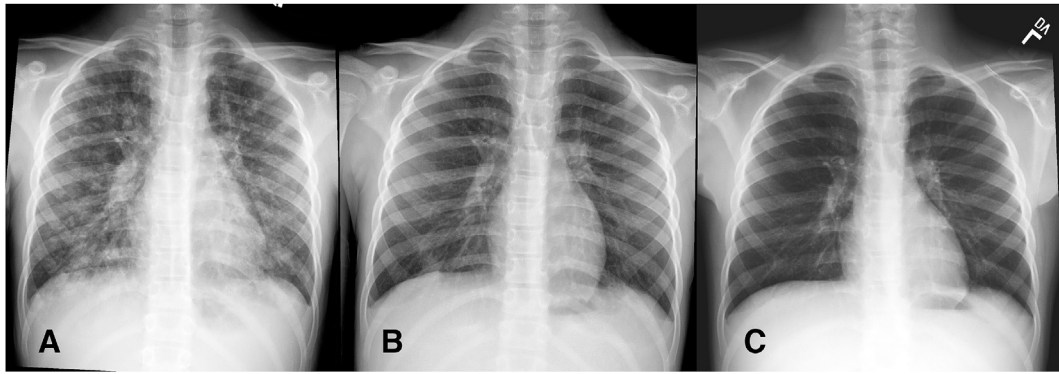


Fig. 1. The patient's initial chest radiograph at our facility at time of admission, demonstrating diffuse reticulonodular lung opacities (a). Marked improvement is seen by hospital day 4 (b), and complete radiographic resolution is demonstrated on a repeat outpatient film 21 days after admission (c).

white cells/mL, 86% of them eosinophils; microscopy of the fluid revealed no organisms and subsequent cultures were negative for bacterial, fungal, or viral pathogens. Studies to assess the possibilities of cystic fibrosis, human immunodeficiency virus, *Aspergillus* or *Mycoplasma* infection, and allergic hypersensitivity pneumonitis were negative. Pulmonary function testing on hospital day 4 revealed both restrictive and obstructive disease, with severe limitation of FEV₁ (46% of reference improving to 52% of reference after albuterol, FEV₁/FVC 79) and mild reduction of TLC (78% of reference) with evidence of air trapping (RV 146% of reference), despite improvement on chest radiograph (Fig. 1b). He was discharged on day 5 of hospitalization to complete a course of oral corticosteroids, with follow-up by the Allergy/Immunology Department. Seen in clinic 3 weeks later, he reported no further pulmonary symptoms and a chest radiograph demonstrated resolution of his interstitial disease (Fig. 1c). Laboratory testing revealed a persistently increased serum IgE (12,700 IU/mL) and elevated white blood cell count (22,600 cells/ μ L). On further questioning, the patient's grandfather shared that the child's daily chores on their farm in

southern Louisiana included the care of seven pigs. The patient was responsible for cleaning a moderately large pig enclosure and feeding the animals daily. This information prompted an expansion of the initial laboratory work-up to include parasitic etiologies, including *Ascaris*, *Toxoplasma*, and others. The serum *Ascaris*-specific IgE level was markedly elevated (433kU/L; normal: <0.35 kU/L). A stool sample revealed no *Ascaris* eggs. As we had observed the patient to have significant, perseverative hand-to-mouth behaviors including onychophagia (Fig. 3), attempts were made twice to collect scrapings from his fingernail beds, but this failed to produce enough sample for analysis. Due to his profoundly elevated *Ascaris*-specific IgE level, we elected to treat the patient with albendazole 400 mg once for presumed *Ascaris* infection. We then performed a site visit to the family's farm in coastal Louisiana in conjunction with the Louisiana Animal Disease Diagnostic Laboratory at LSU. *Ascaris suum* eggs (Fig. 4) were identified both in porcine fecal samples and in the soil immediately surrounding the pen. Several factors regarding the pig enclosure were identified which may have contributed to fecal-oral transmission of the parasite: a water hose which was handled by the caretakers daily was allowed to rest in fecal run-off, an open septic pit for fecal runoff was located immediately at the entrance to the pen, and there was no hand soap near the enclosure. These factors make it highly probable that the family's pigs were the source of the patient's infection, and that the patient's onychophagia was the route of transmission.

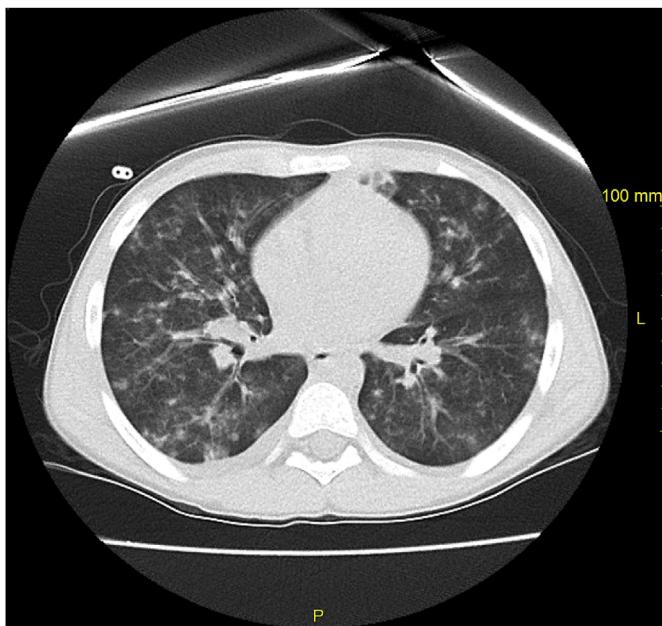


Fig. 2. CT scan demonstrating scattered centrilobular opacities with areas of tree-in-bud pattern and ground glass opacities, and with scattered areas of focal consolidation. No significant lymphadenopathy or pleural effusion is present.

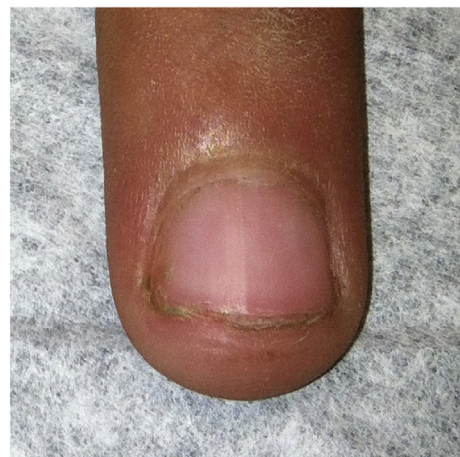


Fig. 3. A photo of the patient's fingernails, demonstrating soiling as well as damage from nail biting.

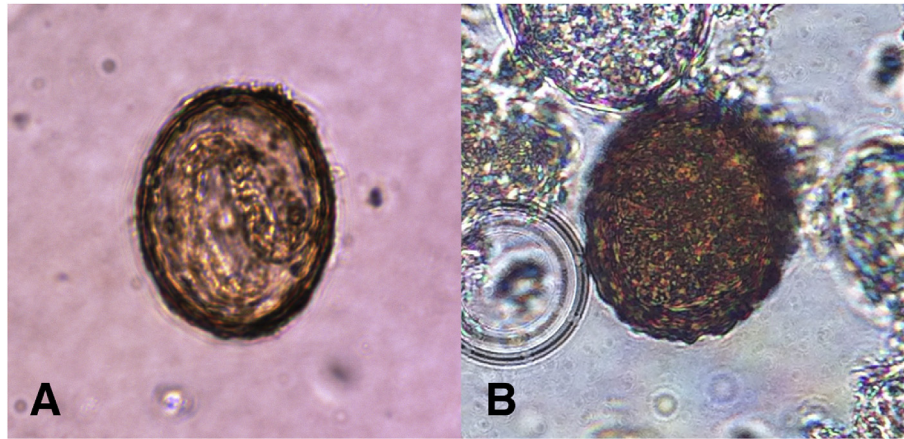


Fig. 4. Microscopic analysis of the soil surrounding the pig enclosure demonstrated larvated *Ascaris suum* eggs (a). A non-larvated egg was isolated from fresh pig feces (b).

2. Discussion

As first described in 1932 by the physician Wilhelm Löffler, Löffler syndrome classically consists of the constellation of ephemeral and migratory pulmonary infiltrates on chest radiograph, respiratory symptoms, and peripheral blood eosinophilia [1]. True Löffler syndrome is a disease on the spectrum of the pulmonary eosinophilias, a varied group of disorders of the lung interstitium, alongside diseases such as acute and chronic eosinophilic pneumonias, eosinophilic granulomatosis with polyangiitis (traditionally Churg-Strauss syndrome), allergic bronchopulmonary aspergillosis, asthma, and drug-induced pneumonitis [1]. Though the etiology of the syndrome was not identified by Löffler in his early description, Dr. Löffler and contemporaries including R. W. Muller ultimately identified *Ascaris* as the likely culprit in subsequent works. Interestingly, this constellation of respiratory signs and symptoms was earlier described by Japanese researcher and self-tester Shimesu Koino in 1922, after he ingested infective *Ascaris* ova and suffered a severe, week-long pneumonitis characterized by dyspnea, harsh cough, and trace hemoptysis [2]. Since the initial description, other etiologies including other organisms and drugs have been implicated in Löffler-like pneumonitis, but true Löffler syndrome is largely considered to occur only in the context of ascariasis.

Ascaris is one of the most common causes of parasitic infection in the world, though specific prevalence data for the US population is lacking [3]. The life-cycle of *Ascaris* in the human host is complex, and begins with ingestion of infective, larvated *Ascaris* eggs. This has been described in settings where untreated animal and human excrement is used as fertilizer for crops. In our case, we postulate that the child's frequent contact with soil and fecal matter near the pig pen, coupled with his onychophagia, led to repeated exposure to infective *Ascaris* eggs [4]. Once ingested, the larvae hatch from the eggs, traverse the wall of the small intestine, cecum, or upper colon, enter the bloodstream via the portal system, and migrate to the liver [2]. They are then carried to the capillary-alveolar interface of the lungs, subsequently migrating through the parenchyma and airways where they both cause mechanical tissue damage and provoke a marked immune response [2]. Löffler syndrome is thus largely a result of eosinophil-mediated inflammatory reaction within the airways and lung parenchyma, related to the migration of *Ascaris* larvae through the lungs [4]. This results in the classically seen sputum, peripheral eosinophilia, and the pneumonitis associated with the disease. The larvae then ascend, largely via the mucociliary escalator, to the pharynx, where they are subsequently

swallowed, returned to the small intestine, mature and reproduce [2].

In the immunocompetent adult host, the classic presentation of Löffler syndrome consists of a dry irritating cough, wheezing and/or rales, and subjective dyspnea [2], [4]. In our patient, these classic signs and symptoms were coupled with fever, malaise, and hypoxemia, likely reflective of his young age and a high level of *Ascaris* inoculum. Löffler syndrome is known to occasionally present as a frank asthma exacerbation, with symptoms resolving after completion of the larval migratory phase and after successful treatment of the infection [3].

In our case, peripheral eosinophilia and elevated serum IgE strongly suggested a parasitic infection. In Löffler syndrome, such eosinophilia is frequently present at the onset of respiratory symptoms, peaking several days after presentation and resolving over a period of weeks [3]–[5]. On BAL and sputum examination, eosinophilia and Charcot-Leyden crystals may be seen. The exceedingly high level of pulmonary eosinophilia in this case (86%) is rarely reported in the literature, and fits with the florid immune response to larval migration through the lung [3], [6], [7]. It is possible to visualize larvae in the bronchial washings, but this finding is rare, and the absence of larvae by no means excludes the diagnosis [2]. *Ascaris*-specific IgE was useful in our case, and strongly indicative of ascariasis. We were unable to isolate *Ascaris* eggs in either the patient's stool or fingernail scrapings. However, as many as six to eight weeks may elapse before the larvae associated with the acute pulmonary symptoms will mature and produce eggs discernable in the stool [3], [4]. Serological testing can provide presumptive evidence that should then be followed by an exhaustive search for a possible source of the infection, so that re-exposures in the patient may be prevented [8].

Ephemeral, migratory non-segmental densities seen on serial chest radiographs is perhaps the most representative sign of Löffler syndrome, with the fleeting opacities postulated to represent migration of larvae through the lung parenchyma [2], [4]. In the pediatric setting, the tendency to avoid serial irradiation may decrease the likelihood of detecting this finding. Mixed restrictive and obstructive lung disease may be demonstrated on pulmonary function testing, as was seen in our patient [3].

On histology, lung tissue may reveal areas of bronchopneumonia, with bronchioles and alveoli containing eosinophils and even larvae in various stages of immobilization and destruction, swarmed with eosinophils [3]. Biopsy is rarely needed to establish the diagnosis, however, and was not performed in our case. Larval migration can cause intra-alveolar hemorrhage, and thus may

result in V/Q mismatch as an explanation for our patient's hypoxemia [3].

Classically, Löffler syndrome is a relatively benign and self-limited syndrome, with peak respiratory symptoms occurring approximately four to sixteen days after ingestion of infective *Ascaris* eggs, and subsiding within three to four weeks [2]. Notably, however, there does appear to be a dose-dependent effect, with more severe symptoms occurring in cases of large inoculum or persistent exposure [3].

Treatment is often not necessary in the milder cases. If, however, the symptoms are severe enough to warrant treatment, as was the case with our patient, steroids have been found to be efficacious in alleviating the acute respiratory symptoms [5]. Though there has historically been some reticence to utilize steroids due to fear of disseminated hyperinfection, such cases are reported almost exclusively in the setting of *Strongyloides* infection in patients receiving chronic steroid therapy or in other immunocompromised states [9]–[12]. It is important to note that while there are a number of equally effective anthelmintics available for treating infection with the adult *Ascaris* worm, none are known to kill the early larval stages during the critical migratory phase [5]. As such, some experts advise deferring anti-helminthic therapy until respiratory symptoms have resolved, and enough time has passed to where the larvae can be expected to have matured (i.e. approximately 6–9 weeks after ingestion) [5].

3. Conclusion

This case of Löffler syndrome in a young, immunocompetent child with onychophagia and exposure to pigs highlights the clinician's need for a broad differential when confronted with fulminant pneumonitis in the pediatric patient. This case is notable for the extreme pulmonary eosinophilia detected on BAL, the unique route of infection, and the patient's rapid improvement with systemic steroids. Ascariasis should be considered even in the absence of travel history, especially in swine-raising areas that are endemic for *Ascaris* in pigs, such as the southeastern United States. Swine-associated Löffler syndrome, and ascariasis more broadly, is seldom reported in the modern medical literature, though there is increasing awareness of this zoonosis in Europe [13], [14]. Recent report of 14 cases of ascariasis on pig farms in Maine has called to light the importance of this pathogen in human pulmonary disease and the need for public health intervention. Our case suggests that ascariasis and associated Löffler syndrome may perhaps be more wide-spread than one might surmise from its relative scarcity in the current pulmonary and infectious disease literature [15].

Funding source

No funding was secured for this study.

Financial disclosure

The authors have no financial relationships relevant to this article to disclose.

Conflict of interest

The authors have no conflicts of interest to disclose.

Clinical trial registration

Not applicable.

Contributors' statements

Dr. Gipson prepared the manuscript and provided inpatient care to the patient. Heena Shah: Dr. Shah provided allergy/immunology consultation care for the patient. Dr. Pepiak provided pulmonary consultation care for the patient, including bronchoscopy. Dr. Bégué provided infectious disease consultation care for the patient, and critical review to the paper. Ryan Avery participated in the collection of soil and fecal samples during our site visit, and isolated and identified the *Ascaris* from these samples. Dr. Malone participated in the collection of soil and fecal samples during our site visit, isolated and identified the *Ascaris* from these samples, and serves as a mentor to Ryan Avery. Dr. Wall provided mentorship to Dr. Gipson in preparation of the manuscript, critically reviewed and edited the manuscript, and provided allergy/immunology care for the patient. All authors approved the final manuscript as submitted and agree to be accountable for all aspects of the work.

Acknowledgements

We extend our sincere appreciation to our patient and his family for their cooperation in the site investigation, and to Dr. Dean Edell for first bringing this patient to our attention. We acknowledge the Louisiana Animal Disease Diagnostic Laboratory at LSU for their role in the definitive identification of *Ascaris* in this case. We also appreciate the guidance of Dr. LeAnne M. Fox, Division of Parasitic Diseases, Centers for Disease Control and Prevention, Atlanta, GA, and Dr. Gary A. Balsamo, Louisiana State Public Health Veterinarian. Dr. Gipson sincerely appreciates the mentorship of Dr. Stephen Levine.

References

- [1] D.M. Rose, D.E. Hrcir, Primary eosinophilic lung diseases, *Allergy Asthma Proc.* 34 (2013) 19–25, <http://dx.doi.org/10.2500/aap.2013.34.3628>.
- [2] O.P. Sharma, *Lung Disease in the Tropics*, New York, 1991.
- [3] R. Chitkara, G. Krishna, Parasitic pulmonary Eosinophilia, *Semin. Respir. Crit. Care Med.* 27 (2006) 171–184, <http://dx.doi.org/10.1055/s-2006-939520>.
- [4] R.L. Guerrant, D.H. Walker, P.F. Weller, *Tropical Infectious Diseases: Principles, Pathogens and Practice*, second ed., Saunders, 2011.
- [5] P. Akuthota, P.F. Weller, Eosinophilic pneumonias, *Clin. Microbiol. Rev.* 25 (2012) 649–660, <http://dx.doi.org/10.1128/CMR.00025-12>.
- [6] G. Ranasuriya, A. Mian, Z. Boujaoude, C. Tsigrelis, Pulmonary toxocariasis: a case report and literature review, *Infection* 42 (2014) 575–578, <http://dx.doi.org/10.1007/s15010-014-0587-3>.
- [7] A.I. Zumla, D.G. James, Immunologic aspects of tropical lung disease, *Clin. Chest Med.* 23 (2002) 283–308.
- [8] J.C. Petithory, Can *Ascaris suum* cause visceral larva migrans? *Lancet* 348 (1996) 689, [http://dx.doi.org/10.1016/S0140-6736\(05\)65117-3](http://dx.doi.org/10.1016/S0140-6736(05)65117-3).
- [9] M.Z. Abdelrahman, M. Zeehaida, N. Rahmah, A. Norsyahida, B. Madihah, H. Azlan, et al., Fatal septicemic shock associated with *Strongyloides stercoralis* infection in a patient with angioimmunoblastic T-cell lymphoma: a case report and literature review, *Parasitol. Int.* 61 (2012) 508–511, <http://dx.doi.org/10.1016/j.parint.2012.04.005>.
- [10] G. Geri, A. Rabbat, J. Mayaux, L. Zafrani, L. Chalumeau-Lemoine, B. Guidet, et al., *Strongyloides stercoralis* hyperinfection syndrome: a case series and a review of the literature, *Infection* 43 (2015) 691–698, <http://dx.doi.org/10.1007/s15010-015-0799-1>.
- [11] E.B. Scowden, W. Schaffner, W.J. Stone, Overwhelming strongyloidiasis: an unappreciated opportunistic infection, *Med. Baltim.* 57 (1978) 527–544.
- [12] T.W. Higenbottam, B.E. Heard, Opportunistic pulmonary strongyloidiasis complicating asthma treated with steroids, *Thorax* 31 (1976) 226–233, <http://dx.doi.org/10.1136/thx.31.2.226>.
- [13] M.C. Starr, S.P. Montgomery, Soil-transmitted Helminthiasis in the United States: a systematic review—1940–2010, *Am. J. Trop. Med. Hyg.* 85 (2011) 680–684, <http://dx.doi.org/10.4269/ajtmh.2011.11-0214>.
- [14] L. Aleksandra, Z. Barbara, L.-A. Natalia, K.-B. Danuta, G.-K. Renata, M.-L. Ewa, Respiratory failure associated with Ascariasis in a patient with immunodeficiency, *Case Rep. Infect. Dis.* 2016 (2016) 1–5, <http://dx.doi.org/10.1155/2016/4070561>.
- [15] L.A. Miller, K. Colby, S.E. Manning, D. Hoenig, E. McEvoy, S. Montgomery, et al., Ascariasis in humans and pigs on small-scale farms, Maine, USA, 2010–2013, *Emerg. Infect. Dis.* 21 (2015) 332–334, <http://dx.doi.org/10.3201/eid2102.140048>.