



Optical coherence tomography angiography in pediatric choroidal neovascularization

Citation

Veronese, Chiara, Chiara Maiolo, David Huang, Yali Jia, Grayson W. Armstrong, Mariachiara Morara, and Antonio P. Ciardella. 2016. "Optical coherence tomography angiography in pediatric choroidal neovascularization." *American journal of ophthalmology case reports* 2 (1): 37-40. doi:10.1016/j.ajoc.2016.03.009. <http://dx.doi.org/10.1016/j.ajoc.2016.03.009>.

Published Version

doi:10.1016/j.ajoc.2016.03.009

Permanent link

<http://nrs.harvard.edu/urn-3:HUL.InstRepos:29738984>

Terms of Use

This article was downloaded from Harvard University's DASH repository, and is made available under the terms and conditions applicable to Other Posted Material, as set forth at <http://nrs.harvard.edu/urn-3:HUL.InstRepos:dash.current.terms-of-use#LAA>

Share Your Story

The Harvard community has made this article openly available.
Please share how this access benefits you. [Submit a story](#).

[Accessibility](#)



Published in final edited form as:

Am J Ophthalmol Case Rep. 2016 July ; 2: 37–40. doi:10.1016/j.ajoc.2016.03.009.

Optical coherence tomography angiography in pediatric choroidal neovascularization

Chiara Veronese^{a,*}, Chiara Maiolo^b, David Huang^c, Yali Jia^c, Grayson W. Armstrong^d, Mariachiara Morara^a, and Antonio P. Ciardella^a

^aOphthalmology Unit, S. Orsola-Malpighi Hospital, University of Bologna, Via Pelagio Palagi, 9, 40138, Bologna, Italy

^bUniversity of Bologna, Via Zamboni, 33, 40126, Bologna, Italy

^cCasey Eye Institute, 3375 SW Terwilliger Blvd, Oregon Health & Science University, Portland, OR, USA

^dCambridge Health Alliance/Harvard Medical School, 1493 Cambridge St, Cambridge, MA, 02139, USA

Abstract

Purpose—To report two cases of pediatric choroidal neovascularization (CNV) and the associated neo-vascular and retinal findings identified on Optical Coherence Tomography Angiography (OCTA) imaging.

Methods—A 14-year-old boy with handheld laser-induced maculopathy-related CNV and a 13-year-old boy with idiopathic CNV were evaluated with visual acuity testing, slit-lamp exam, fundus photography, fluorescein angiography, indocyanine green angiography, spectral domain optical coherence tomography, and OCTA.

Results—Macular CNV were identified in both pediatric patients using OCTA imaging. The first case demonstrated a classic pediatric type II CNV with a “tree-like” pattern and a single vessel in-growth site, while the second case demonstrated a type I CNV with a “glomerular” pattern.

Conclusion—Distinct choroidal neovascular patterns were visualized in these two cases of pediatric CNV when compared to adult subtypes. OCTA is a noninvasive imaging modality capable of evaluating and characterizing pediatric CNV and their associated vascular patterns.

Keywords

Choroidal neovascularization; Children; Pediatric; Optical coherence tomography angiography

1. Introduction

Choroidal neovascularization (CNV) is a serious cause of central visual loss, with subfoveal neovascularization increasing the risk of visual morbidity [1,2]. Although CNV is rare

among children, blindness in this population can be more devastating due to its social and educational repercussions as well as greater disability-adjusted life years. In children, the cause of CNV is most often idiopathic, though rare causes include inflammatory etiologies, optic nerve head anomalies, traumatic choroidal rupture, retinal dystrophies, high myopia, angioid streaks, and choroidal osteoma [3]. In contrast, adult CNV is most commonly caused by age-related macular degeneration. Rarely, CNV have also been reported in handheld laser-induced maculopathy [4].

The gold standard for CNV diagnosis is fluorescein angiography (FA). However, general anesthesia is often necessary to obtain FA imaging in children, increasing the risk of the procedure. Optical Coherence Tomography Angiography (OCTA) provides a non-invasive imaging modality to study the morphology of neo-vascular membranes and vascular structure of CNV [5,6].

To our knowledge, this is the first report describing the utility of OCTA in the evaluation and characterization of pediatric CNVs.

2. Materials and methods

In this case-series, two children each with CNV in one eye were evaluated at Sant'Orsola-Malpighi Hospital, University of Bologna, Bologna, Italy. Written consent for the use of clinical information for research purposes was obtained from each patient. Each child underwent a best correct visual acuity measurement, anterior segment examination, dilated fundus biomicroscopy, color fundus photography, FA, indocyanine green angiography (ICGA), spectral domain optical coherence tomography (SD-OCT) B-scans, and OCTA. FA images were collected during the 5 minutes following injection of dye. ICGA images were collected during the first 10 seconds after dye administration in order to best appreciate the CNV feeder vessel. Spectralis SD-OCT images (Spectralis Heidelberg Engineering, Heidelberg, Germany) and OCTA images (RTVue XR AVANTI, Optovue Inc, Fremont, CA, USA) were collected using methods that have been well documented [4,7]. OCTA angiograms were correlated with concurrently obtained FA, ICGA, and Spectralis SD-OCT B-scans. OCTA images were then color-coded to more carefully evaluate choroidal and retinal vasculature.

3. Results

3.1. Case 1

A 14-year-old boy previously in good health presented with blurred vision in the right eye following self-inflicted handheld laser exposure. He was treated in an outside hospital with one intravitreal bevacizumab injection and subsequently presented to our clinic for a second opinion. At presentation, his visual acuity was 20/50 OD and 20/20 OS. The anterior segment was normal. Fundus examination revealed a whitish subretinal lesion in the right macula with tenting of the internal limiting membrane and resolution of a hemorrhagic ring previously described upon fundus examination (Fig. 1A). FA imaging showed a macular lesion with surrounding hypofluorescence, suggestive of classic CNV (Fig. 1B). ICGA imaging demonstrated subfoveal CNV (Fig. 1C). Color-coded composite *en-face* OCTA

imaging demonstrated a vascular complex (yellow) with a large main central feeder vessel radiating from one side of the lesion (“tree-like” pattern) (Fig. 1D). Spectral Domain Optical Coherence Tomography (SD-OCT) (Spectralis Heidelberg Engineering, Heidelberg, Germany) imaging showed a subfoveal lesion with subretinal fluid (Fig. 1E). Color-coded cross-sectional OCTA imaging demonstrated that the CNV is above the RPE (type II) and overshadows the RPE (Fig. 1F). Three injections of anti-VEGF agents (2 bevacizumab, 1 aflibercept) were administered to the right eye with a resulting improvement in visual acuity of two lines.

3.2. Case 2

A 13-year-old boy was referred to our clinic for evaluation of a retinal lesion of the left eye suspected to be due to toxoplasmosis. The child had no history of toxoplasmosis. Visual acuity was 20/20 OD and 20/60 OS. The anterior segment was normal. Serological tests for inflammatory CNV, including toxoplasmosis, and genetic testing for retinal dystrophies were negative. The patient denied exposure to handheld lasers. Fundus examination revealed a whitish round lesion in the left macula with a scar temporal to the lesion and a pigmented spot over the lesion (Fig. 2A). FA showed a hyperfluorescent macular lesion surrounded by a hyperfluorescent area corresponding to absence of ellipsoid zone and a hypofluorescent area temporal to the lesion corresponding to scar suggestive of occult CNV (Fig. 2B). ICGA imaging demonstrated subfoveal CNV (Fig. 2C). Color-coded composite *en face* OCTA imaging showed details of a vascular complex (“glomerular” pattern) (Fig. 2D). SD-OCT imaging identified a subfoveal lesion with absence of sub-retinal fluid and absence of ellipsoid zone as well as empty space with choroidal atrophy (Fig. 2E). This CNV case appears to be type I as the RPE seems to curve up over the CNV, shown by the color-coded cross-sectional OCTA image (Fig. 2F). Two injections of anti-VEGF agents (bevacizumab) were administered to the left eye and visual acuity remained stable.

4. Discussion

CNV in children exhibit characteristic differences from those found in adults. Compared to adult CNV, pediatric CNV are typically classic type 2 membranes lacking retinal changes found in age-related macular degeneration (AMD), such as thickening and calcification of Bruch’s membrane or diffuse disruption of the retinal pigment epithelium. Additionally, CNV in children are more likely to have a solitary vascular in-growth site, as compared to multiple in-growth sites in AMD-associated CNV. The first case presented here is therefore classic in appearance for a pediatric CNV, with a single vascular in-growth site to a type 2 membrane identified on OCTA. In our second case, the findings were non-classic, as OCTA identified the CNV as a type 1 membrane. Notably, OCTA demonstrated the ability to detect and differentiate between type 1 and type 2 pediatric CNV.

Using OCTA, Kuehlewein et al. [8] described neovascularization exhibiting “medusa” and “seafan” patterns in AMD patients. In contrast, OCTA imaging identified two distinct patterns of neovascularization in our pediatric patients (which we have termed “tree-like” and “glomerular”). We hypothesize that pediatric CNV neovascular patterns are distinct from adult subtypes, resulting from the lack of thickening and calcification of Bruch’s

membrane. This hypothesis is based on our small case series of two patients, however, and larger studies are needed to confirm the distinct nature of pediatric CNV as compared to adult CNV.

By use of the color-coded display system for OCT angiograms, CNV can be highlighted relative to the inner retinal vascular patterns in composite en face angiograms. This improves the ability to classify CNV below the RPE (type I) or above the RPE (type II).

5. Conclusions

In conclusion, these two cases highlight the utility of OCTA as a non-invasive modality to evaluate and characterize pediatric CNV and its associated vascular patterns. While these cases do not demonstrate a role for OCTA in diagnosing or managing pediatric CNV, future studies should evaluate the clinical role of OCTA in its ability to diagnose pediatric CNV, detect responses to treatment, direct appropriate ophthalmologic treatment and follow-up, and assess for CNV recurrence following treatment.

References

1. Rishi P, Gupta A, Rishi E, et al. Choroidal neovascularization in 36 eyes of children and adolescents. *Eye Lond.* 2013; 27:1158–1168. [PubMed: 23887767]
2. Kozak I, Mansour A, Diaz RI, et al. Outcomes of treatment of pediatric choroidal neovascularization with intravitreal antiangiogenic agents: the results of the KKESH International Collaborative Retina Study Group. *Retina.* 2014; 34:2044–2052. [PubMed: 24978669]
3. Sivaprasad S, Moore AT. Choroidal neovascularization in children. *Br J Ophthalmol.* 2008; 92:451–454. [PubMed: 18369058]
4. Bhavsar KV, Wilson D, Margolis R. Multimodal imaging in handheld laser-induced maculopathy. *Am J Ophthalmol.* 2015; 159:227–231. [PubMed: 25448992]
5. Jia Y, Bailey ST, Wilson JD, et al. Quantitative optical coherence tomography angiography of choroidal neovascularization in age-related macular degeneration. *Ophthalmology.* 2014; 121:1435–1444. [PubMed: 24679442]
6. Jia Y, Bailey ST, Hwang ST, et al. Quantitative optical coherence tomography angiography of vascular abnormalities in the living human eye. *Proc Natl Acad Sci.* 2015; 112:E2395–E2402. [PubMed: 25897021]
7. Bonini Filho MA, de Carlo TE, Ferrara D, et al. Association of choroidal neovascularization and central serous chorioretinopathy with optical coherence tomography angiography. *JAMA Ophthalmol.* 2015; 122:1228–1238.
8. Kuehlewein L, Bansal M, Lenis TL, et al. Optical coherence tomography angiography of type 1 neovascularization in age-related macular degeneration. *Am J Ophthalmol.* 2015; 160:739–748.e2. [PubMed: 26164826]

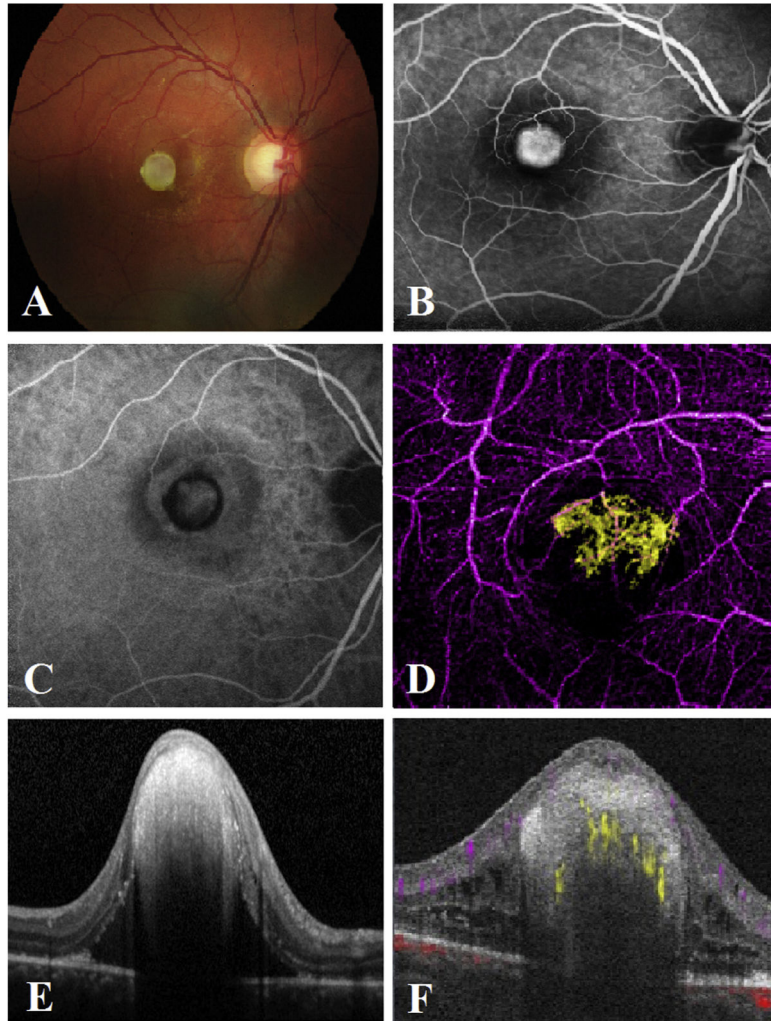


Fig. 1. Case of pediatric handheld laser-induced choroidal neovascularization

A, Color fundus photograph revealing a whitish subretinal lesion in the right macula with tenting of the internal limiting membrane. B, FA image showing macular lesion with surrounding hypofluorescence. C, ICGA image demonstrating subfoveal choroidal neovascularization. D, Color composite *en face* OCTA of retinal vessels (purple) and “tree-like” pattern CNV (yellow). E, Cross-sectional Spectral Domain-OCT image showing subfoveal lesion with subretinal fluid. F, Color-coded cross-sectional OCTA demonstrating a type 2 CNV. (For interpretation of the references to color in this figure legend, the reader is referred to the web version of this article.)

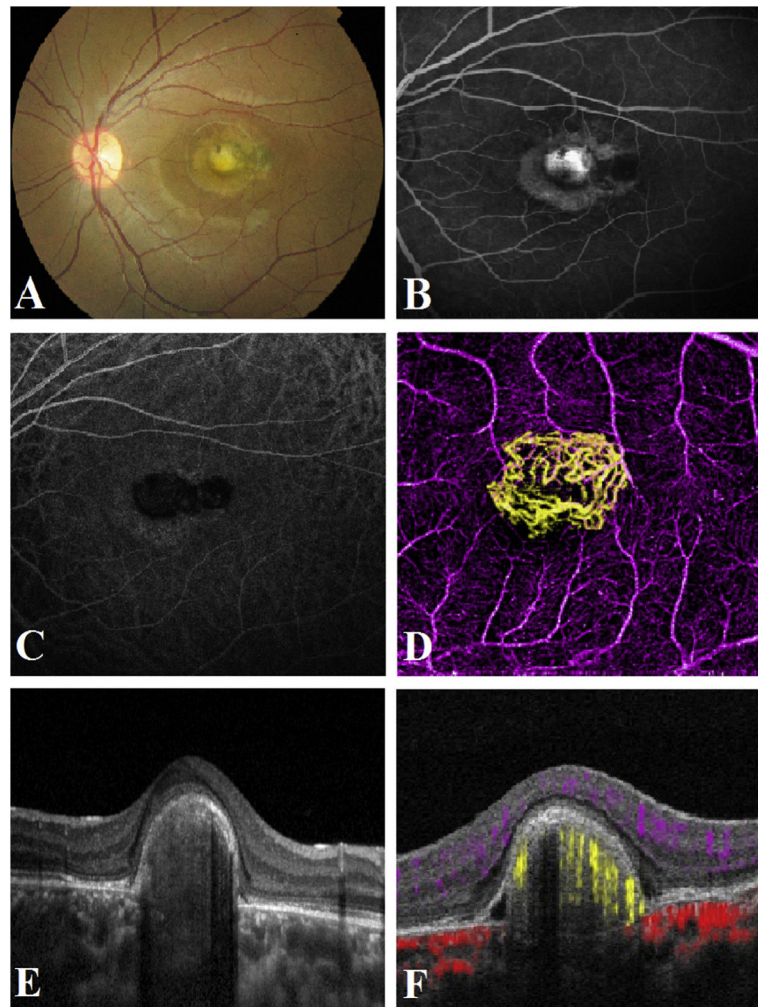


Fig. 2. Case of pediatric idiopathic choroidal neovascularization

A, Color fundus photograph revealing a whitish round lesion in the left macula with a scar temporal to the lesion and a pigmented spot over the lesion. B, FA image showing a macular lesion surrounded by a hyperfluorescent area corresponding to absence of ellipsoid zone. C, ICGA image demonstrating subfoveal macular choroidal neovascularization. D, Color-coded composite *en face* OCTA of retinal vessels (purple) and “glomerular” pattern CNV (yellow). E, Cross-sectional Spectral Domain-OCT image showing a subfoveal lesion with absence of subretinal fluid and absence of ellipsoid zone as well as empty space with choroidal atrophy. F, Color-coded cross-sectional OCTA demonstrating type I CNV (yellow). (For interpretation of the references to color in this figure legend, the reader is referred to the web version of this article.)