



Propranolol Inhibition of β -Adrenergic Receptor Does Not Suppress Pathologic Neovascularization in Oxygen-Induced Retinopathy

Citation

Chen, Jing, Jean-Sebastian Joyal, Colman J. Hatton, Aimee M. Juan, Dorothy T. Pei, Christian G. Hurst, Dan Xu, Andreas Stahl, Ann Hellstrom, and Lois E. H. Smith. 2012. "Propranolol Inhibition of β -Adrenergic Receptor Does Not Suppress Pathologic Neovascularization in Oxygen-Induced Retinopathy." *Investigative Ophthalmology & Visual Science* 53 (6) (May 17): 2968. doi:10.1167/iops.12-9691.

Published Version

doi:10.1167/iops.12-9691

Permanent link

<http://nrs.harvard.edu/urn-3:HUL.InstRepos:30754352>

Terms of Use

This article was downloaded from Harvard University's DASH repository, and is made available under the terms and conditions applicable to Other Posted Material, as set forth at <http://nrs.harvard.edu/urn-3:HUL.InstRepos:dash.current.terms-of-use#LAA>

Share Your Story

The Harvard community has made this article openly available. Please share how this access benefits you. [Submit a story](#).

[Accessibility](#)

Propranolol Inhibition of β -Adrenergic Receptor Does Not Suppress Pathologic Neovascularization in Oxygen-Induced Retinopathy

Jing Chen,¹ Jean-Sebastian Joyal,¹ Colman J. Hatton,¹ Aimee M. Juan,¹ Dorothy T. Pei,¹ Christian G. Hurst,¹ Dan Xu,¹ Andreas Stahl,^{1,2} Ann Hellstrom,³ and Lois E. H. Smith¹

PURPOSE. Retinopathy of prematurity (ROP) is a leading cause of blindness in children and is, in its most severe form, characterized by uncontrolled growth of vision-threatening pathologic vessels. Propranolol, a nonselective β -adrenergic receptor blocker, was reported to protect against pathologic retinal neovascularization in a mouse model of oxygen-induced retinopathy (OIR). Based on this single animal study using nonstandard evaluation of retinopathy, clinical trials are currently ongoing to evaluate propranolol treatment in stage 2 ROP patients who tend to experience spontaneous disease regression and are at low risk of blindness. Because these ROP patients are vulnerable premature infants who are still in a fragile state of incomplete development, the efficacy of propranolol treatment in retinopathy needs to be evaluated thoroughly in preclinical animal models of retinopathy and potential benefits weighed against potential adverse effects.

METHODS. Retinopathy was induced by exposing neonatal mice to 75% oxygen from postnatal day (P) 7 to P12. Three routes of propranolol treatment were assessed from P12 to P16: oral gavage, intraperitoneal injection, or subcutaneous injection, with doses varying between 2 and 60 mg/kg/day. At P17, retinal flatmounts were stained with isolectin and quantified with a standard protocol to measure vasoobliteration and pathologic neovascularization. Retinal gene expression was

analyzed with qRT-PCR using RNA isolated from retinas of control and propranolol-treated pups.

RESULTS. None of the treatment approaches at any dose of propranolol (up to 60 mg/kg/day) were effective in preventing the development of retinopathy in a mouse model of OIR, evaluated using standard techniques. Propranolol treatment also did not change retinal expression of angiogenic factors including vascular endothelial growth factor.

CONCLUSIONS. Propranolol treatment via three routes and up to 30 times the standard human dose failed to suppress retinopathy development in mice. These data bring into question whether propranolol through inhibition of β -adrenergic receptors is an appropriate therapeutic approach for treating ROP. (*Invest Ophthalmol Vis Sci.* 2012;53:2968-2977) DOI:10.1167/iovs.12-9691

Retinopathy of prematurity (ROP) is a leading cause of blindness in children, affecting approximately 16,000 U.S. infants per year.¹ ROP starts with an initial phase of delayed vascular growth resulting in retinal ischemia. Subsequent hypoxia then induces increased secretion of angiogenic factors such as vascular endothelial growth factor (VEGF) to stimulate growth of vision-threatening pathologic vessels.² Current ablation therapies are invasive, costly, and only partially effective, reducing blindness by only approximately 25%. Furthermore, ablation treatment does not increase the number of patients with normal vision. Extensive research has been carried out in search of safe, effective, and inexpensive treatment options for ROP.

Propranolol, a nonselective β -adrenergic receptor blocker, has been serendipitously identified as a new and promising treatment for infantile hemangioma (IH),³ a benign vascular tumor. In 2008, an infant with cardiac problems and an incidental facial hemangioma was treated with a β -adrenergic blocker, and the hemangioma regressed.³ Consequently, propranolol has been used over the past few years at doses up to about 2 mg/kg/day to treat hemangiomas with considerable success in causing tumor regression.⁴⁻⁶ However, some patients have suffered severe adverse effects including hypoglycemia.⁷ To date there are no reports of controlled prospective trials of safety and efficacy of propranolol. In addition, the mechanism of propranolol's action in hemangiomas is not established; hypotheses include vasoconstriction, suppression of angiogenic factors, and increased endothelial cell (EC) apoptosis.³

Interestingly, it was reported that in a mouse model of oxygen-induced ROP (OIR) that propranolol was effective in protecting against pathologic retinal neovascularization (NV) and blood barrier breakdown, presumably via suppression of β 3-adrenoreceptor induced VEGF overexpression.⁸ However,

From the ¹Department of Ophthalmology, Harvard Medical School, Children's Hospital Boston, Massachusetts; the ²University Eye Hospital Freiburg, Freiburg, Germany; and the ³Department of Ophthalmology, Institute of Neuroscience and Physiology, The Sahlgrenska Academy at University of Gothenburg, Gothenburg, Sweden.

Supported in part by the Children's Hospital Boston Manton Center for Orphan Disease Research Innovation Fund, Children's Hospital Boston Ophthalmology Foundation, Juvenile Diabetes Research Foundation International, Charles H. Hood Foundation Child Health Research Award (JC), National Eye Institute/National Institutes of Health Grants EY017017-04S1 and EY017017-05, V. Kann Rasmussen Foundation, Children's Hospital Boston Mental Retardation and Developmental Disabilities Research Center Grant PO1HD18655, Research to Prevent Blindness Senior Investigator Award, Alcon Research Institute Award, MacTel Foundation, Roche Foundation for Anemia Research (LEHS), Freifrau von Nauendorff Foundation (AS), and the German Ophthalmic Society (AS).

Submitted for publication February 13, 2012; revised March 23, 2012; accepted March 23, 2012.

Disclosure: **J. Chen**, None; **J.-S. Joyal**, None; **C.J. Hatton**, None; **A.M. Juan**, None; **D.T. Pei**, None; **C.G. Hurst**, None; **D. Xu**, None; **A. Stahl**, None; **A. Hellstrom**, None; **L.E.H. Smith**, None

Corresponding author: Lois E. H. Smith, Department of Ophthalmology, Harvard Medical School/Children's Hospital Boston, 300 Longwood Avenue, Boston, MA 02115; lois.smith@childrens.harvard.edu.

this work has not been independently verified, which is particularly important because this study used nonstandard techniques to quantify the severity of retinopathy.⁸ Based on this publication, a clinical trial (PROP-ROP) is currently ongoing to evaluate propranolol treatment in all stage 2 ROP patients,⁹ despite clinical evidence that most infants with stage 2 ROP regress spontaneously.¹⁰ Thus propranolol could be administered to many infants, most of whom are not at risk of disease progression or blindness. Because of the fragility of premature infants, with ongoing development of the central nervous system, great care must be taken to carefully weigh potential benefits of propranolol, if any, against the potential neurologic or systemic adverse effects.¹¹ Therefore the efficacy of propranolol as a novel treatment in retinopathy needs to be evaluated thoroughly in preclinical models of retinopathy, which is the focus of this study.

Here we evaluated the use of propranolol in OIR using three routes of administration (oral gavage, intraperitoneal [IP] or subcutaneous [SC] injection), with doses ranging from the standard human dose for treating hemangiomas (2 mg/kg/day) to up to 30 times greater (60 mg/kg/day). Retinopathy was induced by exposing mouse pups to 75% oxygen from postnatal day (P) 7 to P12. The mouse model of OIR mimics ROP in humans by generating oxygen-induced vessel loss during the first phase (P7 to P12), followed by retinal ischemia and hypoxia-induced pathologic NV after mice are returned to room air (P12–P17).^{12,13} Our results show that propranolol treatment at any dose (including 30 times the standard human dose) and any route of administration fails to suppress the development of retinopathy in mice, contrary to the prior report.⁸ These results therefore do not support a protective role of propranolol in retinopathy, and bring into question whether propranolol and its inhibition of β -adrenergic receptor is a reasonable therapeutic approach for treating ROP.

METHODS

Animals

These studies adhered to the Association for Research in Vision and Ophthalmology (ARVO) Statement for the Use of Animals in Ophthalmic and Vision Research and were approved by the Children's Hospital Boston Animal Care and Use Committee. For this study, traditional inbred mice (129S6/SvEvTac; Taconic Farms, Inc., Hudson, NY) were used.

Oxygen-Induced Retinopathy and Propranolol Treatment

To induce pathologic NV in the retina, mouse pups with their nursing mother were exposed to 75% oxygen from P7 to P12 followed by room air.¹² To assess the effect of propranolol in OIR, mice were treated with propranolol via three routes of intervention from P12 to P16: oral gavage, IP injection, or SC injection, with doses ranging from 2 up to 60 mg/kg/day. Mice were treated either daily (for most experiments), or three times per day (for SC 60 mg/kg/day). Propranolol (catalog no. P0884; Sigma-Aldrich) was solubilized in citric acid buffer (pH = 3) as concentrated stock and diluted in sterile saline immediately before use.

Retina Dissection, Staining, and Imaging

Pathologic retinal NV was evaluated at P17, when the neovascular response is greatest following oxygen-induced retinopathy. Mice were anesthetized with tribromoethanol (Avertin; Sigma-Aldrich) and euthanized by cervical dislocation. Eyes were enucleated and fixed in 4% paraformaldehyde for 1 hour at room temperature, followed by isolation and subsequent dissection of the retina. To visualize vessels,

retinas were stained overnight at room temperature with fluoresceinated *Griffonia Bandeiraea Simplicifolia* (Isolectin B₄, Alexa Fluor 594 conjugated I21413; 1:100 dilution; Invitrogen, Carlsbad, CA) in 1 mM CaCl₂ in PBS. Following 2 hours of washes in PBS, retinas were whole-mounted onto microscope slides (Superfrost/Plus, 12-550-15; Thermo Fisher Scientific, Waltham, MA), with the photoreceptor side down and embedded in antifade reagent (SlowFade, S2828; Invitrogen). Images of whole-mounted retina were taken at $\times 5$ magnification on a high-level materials microscope (AxioObserver.Z1 microscope; Carl Zeiss Microscopy) and merged using commercial software (AxioVision 4.6.3.0; Carl Zeiss) to produce an image of the entire retina.

Quantification of Vessel Loss and Neovascularization in OIR

Retinal image analysis was performed using standard published protocols.^{13,14} Vasoobliteration (VO) and neovascular tuft formation in OIR were quantified in digital imaging/photo editing software (Adobe Photoshop; Adobe Systems, San Jose, CA) and ImageJ software (developed by Wayne Rasband, National Institutes of Health, Bethesda, MD; available at <http://rsb.info.nih.gov/ij/index.html>). The number of pixels in the vascular area during development was visualized with isolectin staining (outlined in Adobe Photoshop) and compared with the total number of pixels in the whole retina. Retinal areas with pathologic neovascular tufts structures were visually identified by their abnormal aggregated morphology that is distinct from the normal finely branched vascular network. The number of pixels in the pathologic neovascular area was quantified and compared with the total number of pixels in the whole retina by a computer-aided method (the SWIFT_NV method),¹⁴ which consists of a set of macros on NIH's free ImageJ platform to isolate the neovascular structures from the background fluorescence of normal vessels. Percentages of NV in total retinas were compared between those from propranolol-treated mice or littermate control with identical oxygen conditions. Evaluation was done blind for the identity of the sample; n is the number of eyes quantified.

Retinal RNA Isolation and Gene Expression Analysis

Total RNA was extracted from the retinas of six mice, each from a different litter; the RNA was pooled to reduce biologic variability ($n = 6$). Retinas from each time point were lysed and homogenized with a mortar and pestle and filtered through a biopolymer-shredding system (QiaShredder columns; Qiagen, Chatsworth, MD). RNA was then extracted according to the manufacturer's instructions (RNeasy Kit; Qiagen). To generate cDNA, 1 μ g total RNA was treated with a DNase treatment and removal reagent (DNase I; Ambion Inc., Austin, TX) to remove any contaminating genomic DNA, and was then reverse transcribed using random hexamers and a commercial reverse transcriptase kit (SuperScript III;). All cDNA samples were aliquoted and stored at -80°C . RT-PCR primers were designed using a public database for PCR primers (Primer Bank and Primer BLAST [Basic Local Alignment Search Tool] software; National Center for Biotechnology Information [NCBI]). The sequences of primers are *ADRB1* (F: 5'-GTC ATG GGA TTG CTG GTG GT-3', R: 5'-GCA AAC TCT GGT AGC GAA AGG-3'), *ADRB2* (F: 5'-GAC AGC GAC TTC TTG CTG G-3', R: 5'-CGT CCC GTT CCT GAG TGA C-3'), *ADRB3* (F: 5'-TCT CTG GCT TTG TGG TCG GA-3', R: 5'-GTT GGT TAT GGT CTG TAG TCT CG-3'), *VEGF-A* (F: 5'-GCA CAT AGA GAG AAT GAG CTT CC-3', R: 5'-CTC CGC TCT GAA CAA GGC T-3'), *Epo* (F: 5'-AGG AAT TGA TGT CGC CTC CA-3', R: 5'-AGC TTG CAG AAA GTA TCC ACT GTG-3'), *Ang1* (F: 5'-CAT TCT TCG CTG CCA TTC TG-3', R: 5'-GCA CAT TGC CCA TGT TGA ATC-3'), *Ang2* (F: 5'-TTA GCA CAA AGG ATT CGG ACA AT-3', R: 5'-TTT TGT GGG TAG TAC TGT CCA TTC A-3'), and an unchanging control gene, *cyclophilin A* (F: 5'-CAG ACG CCA CTG TCG CTT T-3', R: 5'-TGT CTT TGG AAC TTT GTC TGC AA-3'). We used three methods to analyze

primer sequences for specificity of gene detection. First, the NCBI BLAST module was used to identify primer and probe sequences that specifically detected the sequence of choice. Second, amplicons generated during a PCR reaction were analyzed using the first derivative primer melting curve software (Applied Biosystems, Foster City, CA). This analysis determines the presence of amplicons on the basis of a specific melting point temperature. Third, amplicons generated were gel purified and sequenced by the Children's Hospital Boston Core Sequencing Facility. This further confirmed the selection of the desired sequence. Quantitative analysis of gene expression was determined using a sequence detection system (ABI Prism 7700, *TaqMan*; and SYBR Green master mix kit [KapaBiosystem, catalog no. KK4605]). Standard curves for each gene were plotted with quantified cDNA template during each real-time PCR reaction. Each target gene mRNA copy number was normalized to a million copies of the housekeeping gene, *cyclophilin A*, using the delta delta C(T) method, by comparing the C_t values of target genes in different samples, and normalized to the C_t values of an endogenous housekeeping gene *cyclophilin A* in these samples.

Retinal VEGF-A ELISA

Mouse VEGF-A quantitative ELISAs were used (Quantikine ELISA Kit, catalog no. MMV00; R&D Systems, Minneapolis, MN). Retinas were dissected from P17 OIR mice treated with propranolol (SC 60 mg/kg/day P12–P16) or control ($n=6$ per group). Retinas were homogenized in PBS with protease inhibitor and analyzed for protein concentration by a BCA protein assay. Subsequently, VEGF-A ELISA assay was performed following the manufacturer's instruction as described previously.¹⁵

Endothelial Cell Culture

Human retinal microvascular endothelial cells (HRMECs; Cell Systems, Kirkland, WA) were cultured in an enriched culture medium (Complete Medium; Cell Systems) and used from passages 3 to 7 for experiments. Monolayer cells were treated with varying concentrations of propranolol for 48 hours. Cells were harvested for RT-qPCR, or analyzed with MTT assay according to manufacturer's instruction as described previously.¹⁶ The primer sequences for RT-qPCR are *VEGFR1* (F: 5'-CCC TCG CCG GAA GTT GTA T-3', R: 5'-TTA ACG AGT AGC CAC GAG TCA AAT-3'), *VEGFR2* (F: 5'-GGC CCA ATA ATC AGA GTG GCA-3', R: 5'-TGT CAT TTC CGA TCA CTT TTG GA-3'), *cyclophilin A* (F: 5'-CTG GAC CCA ACA CAA ATG GTT-3', R: 5'-CCA CAA TAT TCA TGC CTT CTT TCA-3'). Each experiment was repeated three times ($n=6$ per group).

Statistics

Results are presented as mean \pm SEM for animal studies and mean \pm SD for nonanimal studies. For all statistical analysis, a two-sample *t*-test (or ANOVA if more than two groups of samples) was performed with values of $P < 0.05$ considered significant.

RESULTS

Oral Gavage of Propranolol Is Ineffective to Suppress Pathologic Neovascularization in Retinopathy

To assess the effect of propranolol in OIR, we first administered daily propranolol orally to mouse pups with induced OIR during the phase of proliferative retinopathy (P12–P16). Retinopathy development from P12 to P14 in OIR resembles stage 2 ROP in preterm infants with avascular retina and tissue hypoxia but no NV (stage 3) yet. Mice were gavaged with 2 mg/kg/day propranolol (equivalent of standard human dose for treating IH), whereas littermate control mice were fed

vehicle solution. At P17 when maximal neovascular response is observed, retinas were dissected and lectin-stained to visualize retinal vasculature. The extent of VO and NV was assessed according to a standard protocol, in which the area of VO and NV were quantified in retinal flatmounts as compared with total retinal area.^{13,14} The propranolol-treated group showed vasoobliterated areas of $21.4 \pm 1.1\%$ compared with $19.9 \pm 1.2\%$ in the control group ($P=0.40$; $n=4-6$ per group) (Figs. 1a, 1b). Pathologic NV in the propranolol group was $18.1 \pm 1.3\%$, compared with $18.4 \pm 1.4\%$ in the control group ($P=0.87$; $n=4-6$ per group) (Figs. 1a, 1c). There was no statistically significant difference between the propranolol-treated and control groups, which suggests that oral administration of propranolol at the given standard human dose is not effective in suppressing retinopathy.

IP Injection of Propranolol Fails to Protect against Pathologic Neovascularization

To confirm the results obtained by oral gavage, we next assessed the effect of propranolol treatment on OIR given via IP injection. After induction of retinopathy, mouse pups were injected daily with propranolol from P12 to P16, whereas littermate control mice were treated with saline injections. Compared with the control group, mice treated with 2 mg/kg/day of propranolol showed similar levels of VO ($18.9 \pm 0.9\%$ in the propranolol group vs. $18.8 \pm 0.9\%$ in controls, $n=17-23$ per group; $P=0.95$, Figs. 2a, 2b). However, mice treated with a higher dose of propranolol (20 mg/kg/day) showed significantly increased levels of VO compared with controls ($25.8 \pm 1.2\%$ in the propranolol group, $n=6$; vs. $18.8 \pm 0.9\%$ in controls, $n=23$; $P=0.001$; Figs. 2a, 2b). With respect to pathologic NV, mice treated with propranolol at 2 mg/kg/day ($18.7 \pm 0.7\%$) showed levels similar to those of the controls ($16.9 \pm 0.7\%$, $P=0.10$, Figs. 2a, 2c). However, for the higher dose of propranolol, a detrimental effect was also observed for NV. At 20 mg/kg/day of propranolol there was a significantly higher level of NV compared with that of controls ($22.4 \pm 0.7\%$ propranolol vs. $16.9 \pm 0.7\%$ control; $P=0.0008$, Figs. 2a, 2c). Together these data suggest that IP injection of propranolol at the standard human dose (2 mg/kg/day) does not protect against retinopathy, and a higher dose of propranolol (20 mg/kg/day) may even worsen both regrowth of normal vessels (as signified by increased VO at P17) and pathologic NV in retinopathy.

SC Injection of Propranolol Does Not Inhibit Pathologic Neovascularization

Having established that both oral gavage and IP injection of propranolol failed to improve retinopathy, we proceeded to evaluate the effect of propranolol with SC injection. Daily propranolol injections of 20 mg/kg/day from P12 to P16 again failed to protect against retinopathy. Similar levels of VO were found in the propranolol group ($14.1 \pm 0.8\%$, $n=21$) and in the controls ($13.5 \pm 0.9\%$, $n=16$, $P=0.65$, Figs. 3a, 3b). We did not observe any significant change in pathologic NV with SC propranolol treatment ($14.5 \pm 0.8\%$ in propranolol group vs. $14.8 \pm 1.1\%$ in controls, $P=0.80$, Figs. 3a, 3c).

To account for propranolol's half-life in circulation (3–6 hours),¹⁷ we evaluated SC propranolol injections three times per day (20 mg/kg/injection; i.e., 60 mg/kg/day, P12–P16). Despite such a high dosage, propranolol still failed to suppress the development of retinopathy, resulting in comparable levels of both VO ($11.5 \pm 1.0\%$ in the propranolol group vs. $10.9 \pm 0.6\%$ in controls, $n=12-13$ per group, $P=0.60$, Figs. 4a, 4b), and NV as littermate controls ($6.9 \pm 0.7\%$ in the propranolol group vs. $5.8 \pm 0.7\%$ in controls, $P=0.30$, Figs. 4a, 4c). These

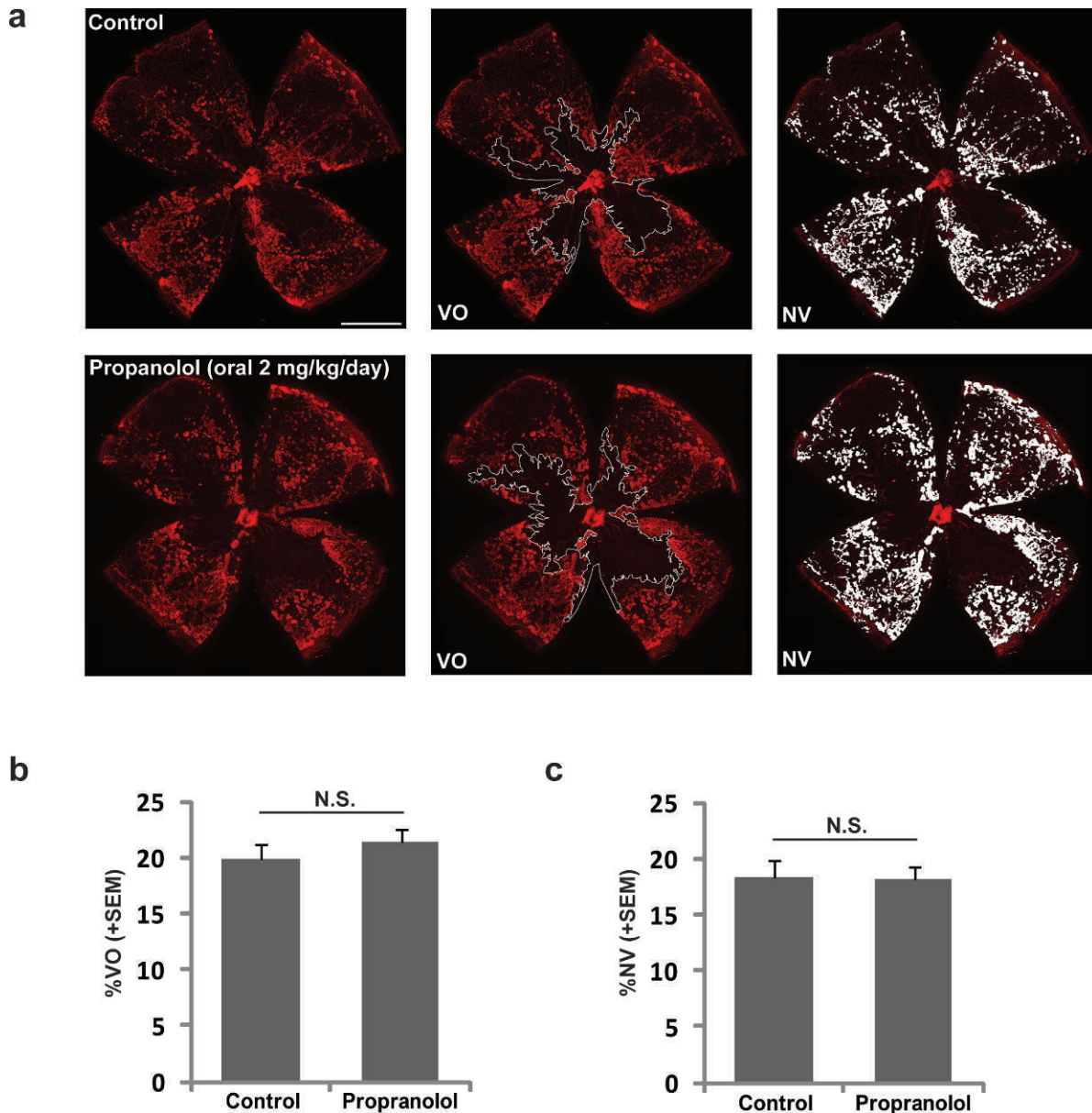


FIGURE 1. Oral gavage of propranolol does not protect against OIR. (a) Representative images of retinal whole mounts isolated from P17 mice with induced retinopathy treated with propranolol or vehicle control daily from P12 to P16 (2 mg/kg/day). Retinas were stained with isolectin B₄ (red) to visualize vasculature. Quantifications of vasoobliteration (VO) and neovascularization (NV) are highlighted. Scale bar: 1000 μ m. (b) Quantification of VO and (c) NV as percentage of total retinal area. N.S., not significant.

results, performed with identical doses and route of intervention as reported previously,⁸ do not support a protective effect of propranolol.

Propranolol Treatment Does Not Influence Expression of Angiogenic Factors

Increased levels of angiogenic factors such as VEGF, erythropoietin (Epo), angiopoietin-1 (Ang1), and angiopoietin-2 (Ang2) are found in the vitreous of patients with ROP.^{18–21} Proangiogenic growth factors such as VEGF and Epo, and the balance between Ang1 and Ang2, can mediate pathologic vascular growth in retinopathy.^{22–24} To evaluate whether propranolol treatment influences the expression of angiogenic factors in OIR, retinas from control and propranolol-treated mice (SC, 60 mg/kg/day) were isolated and retinal gene

expression analyzed with RT-qPCR. Compared with controls, propranolol-treated mice did not show a significant difference in the retinal expression of *Vegf-A*, *Epo*, *Ang1*, or *Ang2* (Fig. 4d). In addition, VEGF-A protein levels analyzed with ELISA were similar between the control and propranolol groups (Fig. 4e). These results suggest that blocking β -adrenergic receptors with propranolol does not influence the expression of these angiogenic factors, which is consistent with similar levels of pathologic NV observed between the control and propranolol-treated groups (Fig. 3).

Expression of β -Adrenergic Receptors in Retinopathy

Because propranolol is a nonspecific β -adrenergic receptor blocker that can potentially interact with all three isoforms of

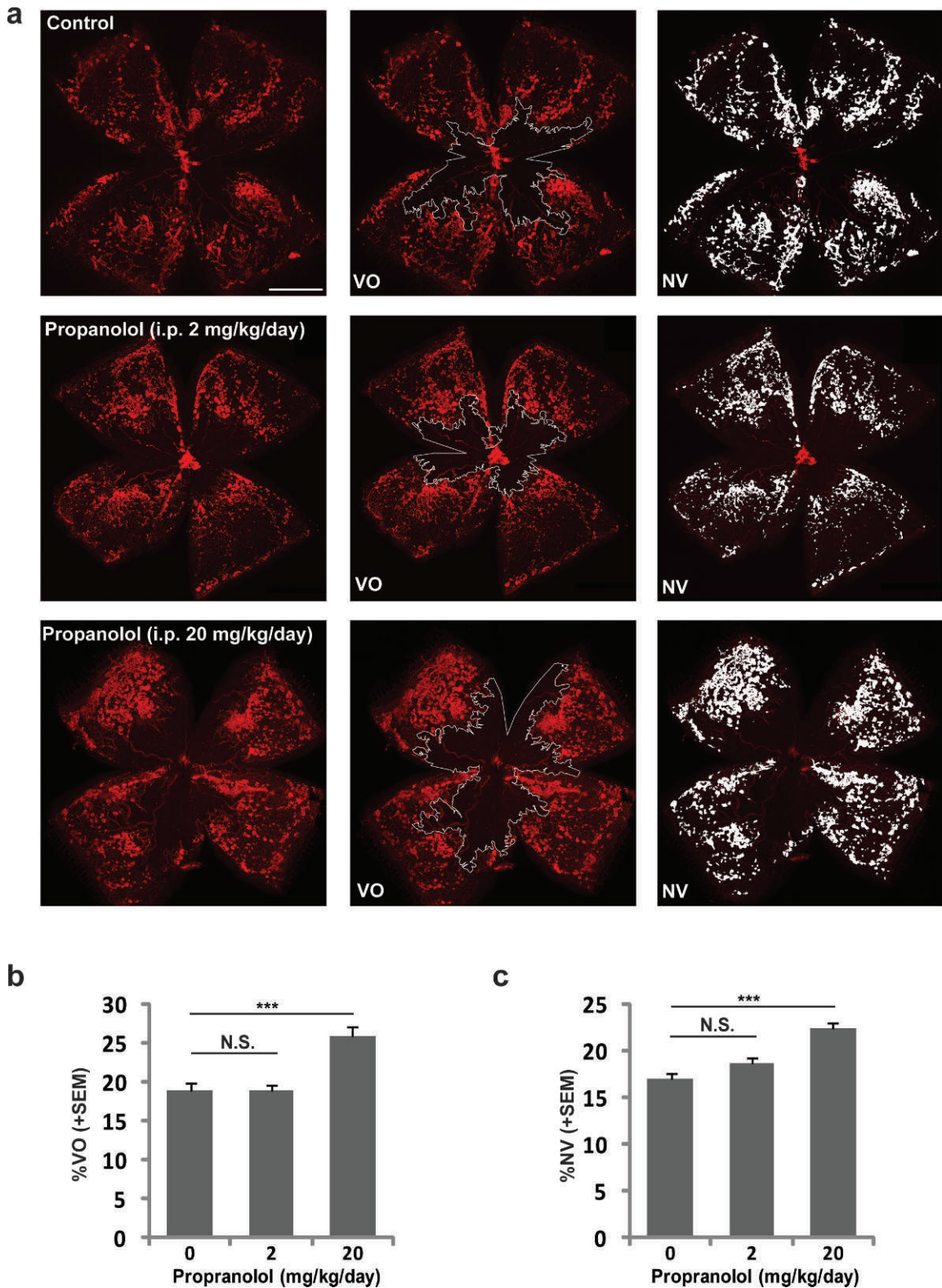


FIGURE 2. IP injection of propranolol does not suppress pathologic neovascularization in OIR. (a) Representative images of retinal whole mounts isolated from P17 mice with induced retinopathy treated with propranolol or vehicle control daily from P12 to P16 (2 or 20 mg/kg/day). Retinas were stained with isolectin B₄ (red) to visualize vasculature. Quantifications of VO and NV are highlighted. Scale bar: 1000 μ m. (b) Quantification of VO and (c) NV as percentage of total retinal area. N.S., not significant. *** $P < 0.001$.

the β -adrenergic receptor, we assessed the expression of β -adrenergic receptors in OIR-exposed retinas compared with room air controls. β -Adrenergic receptor1 (ADRB1) remained

unchanged in the second phase of OIR (P15 and P17) when neovessels proliferate (Fig. 5a). In contrast, β -adrenergic receptor2 (ADRB2) showed a modest upregulation at P17

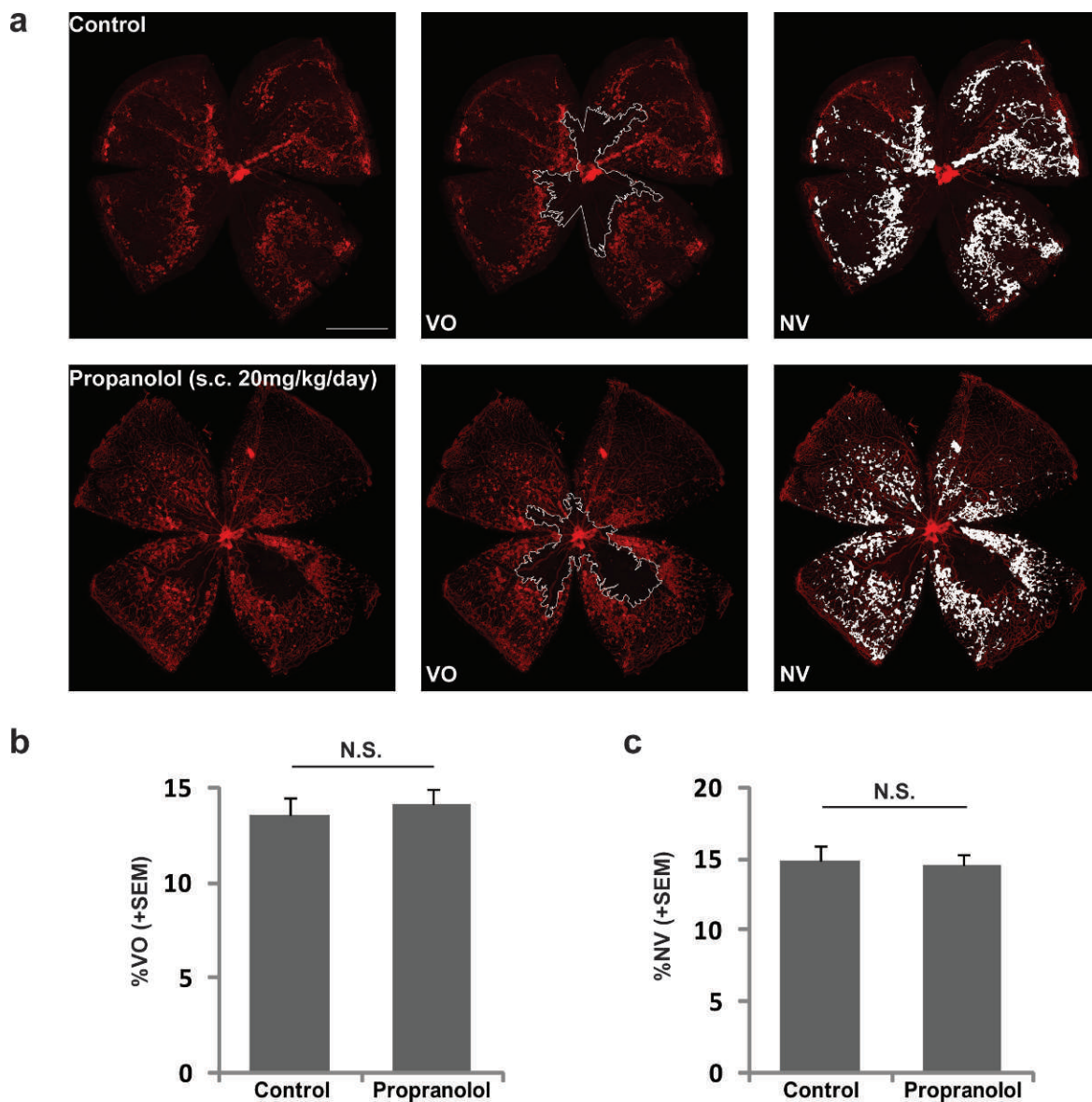


FIGURE 3. SC injection of propranolol fails to protect against retinopathy in OIR. (a) Representative images of retinal whole mounts isolated from P17 mice with induced retinopathy treated with propranolol (SC) or vehicle control daily from P12 to P16 (20 mg/kg/day). Retinas were stained with isolectin B₄ (red) to visualize vasculature. Quantifications of VO and NV are highlighted. Scale bar: 1000 μ m. (b) Quantification of VO and (c) NV as percentage of total retinal area. N.S., not significant.

(Fig. 5b). Interestingly, β -adrenergic receptor3 (ADRB3) was upregulated dramatically (>10-fold) at P17, but unchanged at P15 (Fig. 5c). Although these receptors are modulated in retinopathy, suppression of their activity using propranolol at the given doses was not sufficient to influence the retinopathy outcome. Therefore, the regulation of β -adrenergic receptors in OIR may represent a retinal response to OIR, but it is unlikely to be a major cause of pathologic vessel proliferation in retinopathy development.

Low Concentrations of Propranolol Do Not Suppress Human Retinal Microvascular Endothelial Cell Proliferation

To evaluate the effect of propranolol in vitro, we treated human retinal microvascular endothelial cells (HRMECs) with various concentrations of propranolol. We found that propranolol

treatment (up to 50 μ M) did not significantly affect expression levels of either VEGF receptor 1 (VEGFR1) or VEGF receptor 2 (VEGFR2) (Figs. 6a, 6b), which suggests that propranolol treatment does not influence VEGF receptor signaling by regulating receptor expression. In addition, endothelial cell proliferation was unaffected by physiologic doses of propranolol compared with vehicle-treated cells (Fig. 6c). Although it is difficult to estimate the amount of propranolol that actually reaches the retina, a standard dose of propranolol (2 mg/kg/day), assuming equal distribution of propranolol in all tissues, will yield approximately 2 μ M cellular concentration in the retina, a point at which EC proliferation is not suppressed (Fig. 6c). Only at high nonphysiological concentrations of propranolol (>10 μ M) is proliferation of HRMECs significantly yet modestly suppressed (Fig. 6c). This may help to explain in part the modest decrease in vascular regrowth (i.e., increased VO) observed in the second phase of OIR (P12–P17) with propranolol (IP injection

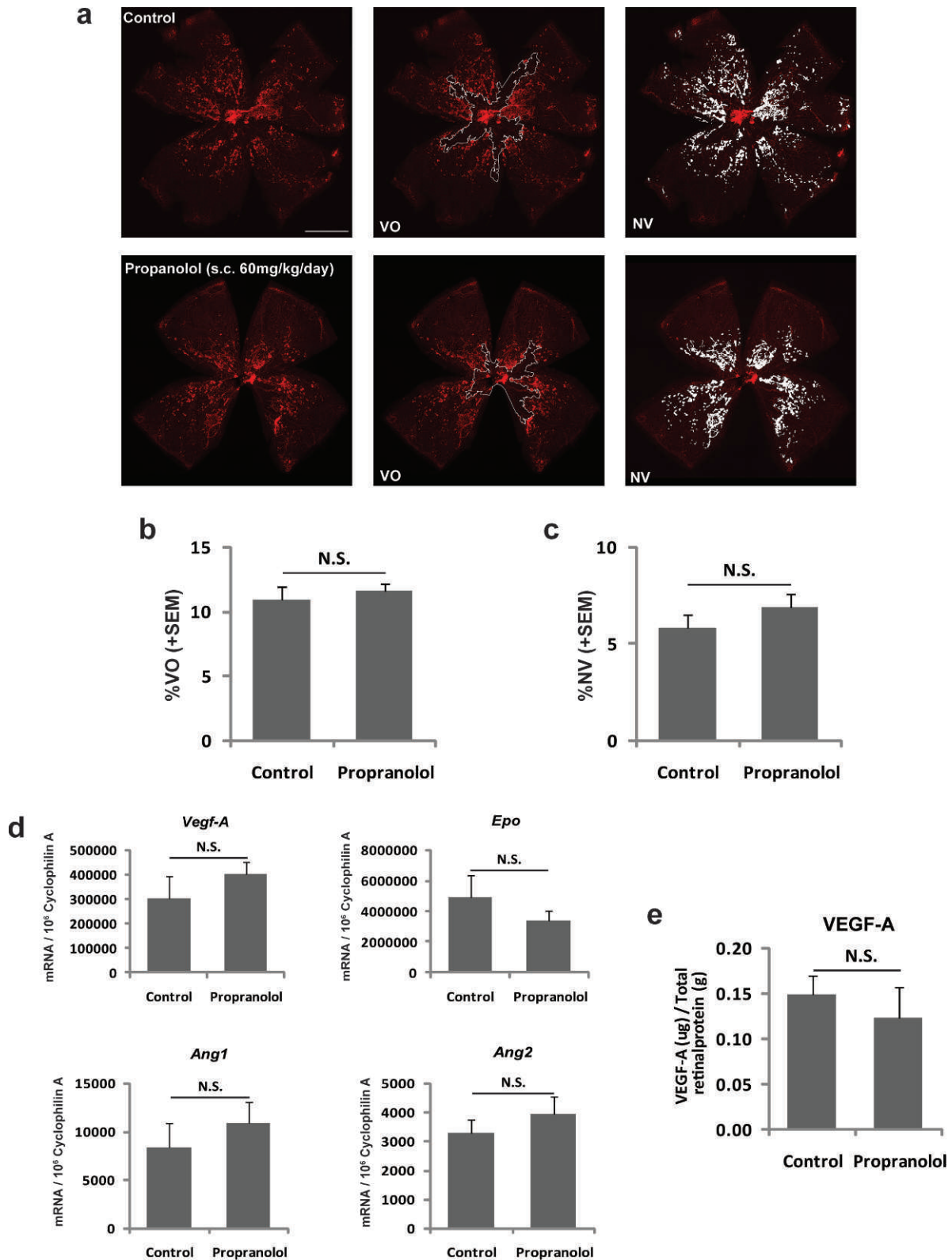


FIGURE 4. Propranolol fails to suppress OIR and does not affect angiogenic factors in OIR. **(a)** Representative images of retinal whole mounts isolated from P17 mice with induced retinopathy treated with propranolol (SC) or vehicle control three times per day from P12 to P16 (60 mg/kg/day). Retinas were stained with isolectin B₄ (red) to visualize vasculature. Quantifications of VO and NV are highlighted. Scale bar: 1000 μm. **(b)** Quantification of VO and **(c)** NV as percentage of total retinal area. **(d)** Retinal expression of angiogenic factors (*Vegf*, *Epo*, *Ang1*, and *Ang2*) in OIR mice treated with propranolol (SC, 60 mg/kg/day) or control were quantified with RT-qPCR. **(e)** Protein levels of retinal VEGF from OIR mice treated with propranolol (SC, 60 mg/kg/day) or control were measured with ELISA assay. N.S., not significant.

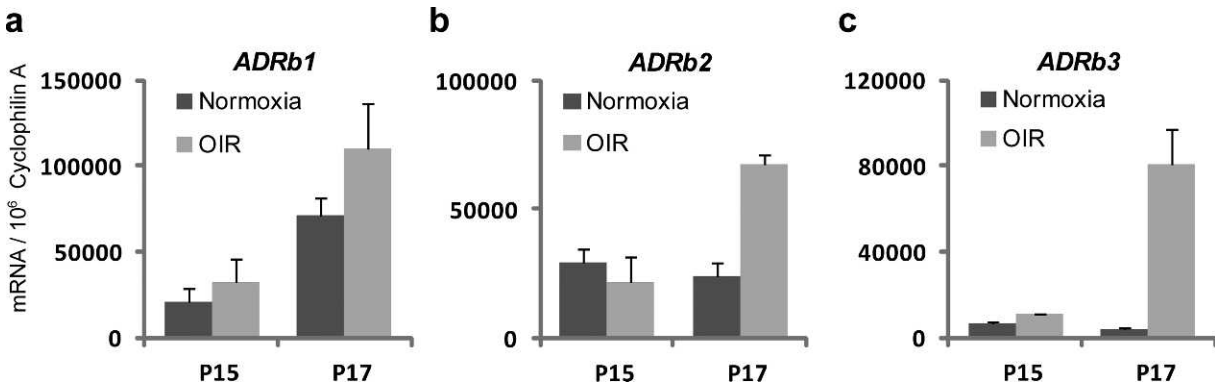


FIGURE 5. Retinal expression of three β -adrenergic receptors in OIR: (a) β -adrenergic receptor 1 (*ADRB1*), (b) β -adrenergic receptor 2 (*ADRB2*), and (c) β -adrenergic receptor 3 (*ADRB3*). Total retinal RNA was isolated from P15 and P17 mice with induced OIR or control mice raised in room air. Gene expression was measured with RT-qPCR and normalized to housekeeping gene *cyclophilin A* expression.

20 mg/kg/day, Fig. 2b). Increased VO can lead to more tissue ischemia and retinal hypoxia, thus subsequent worsening of pathologic NV (Fig. 2c).

DISCUSSION

In this study we evaluated three routes of delivery for propranolol (oral gavage, IP injection, and SC injection) using varying doses (2-60 mg/kg/day) up to 30 times the standard human dose (2 mg/kg/day) in retinopathy. We found that none of the treatment approaches at any dose of propranolol was

effective against the development of retinopathy in a mouse model of OIR. Importantly, a higher dose of IP injections of propranolol worsened retinopathy, with increases in both VO and pathologic NV. These results contradict the previous report of propranolol's protective effects against the development of retinopathy in the same mouse model, using SC injection of propranolol (0.06-60 mg/kg/day) or IP injection (40 mg/kg/day).⁸ This discrepancy may be due to the different methods of evaluating retinopathy in OIR. The former study used fluorescent angiography to assess the extent of pathologic vessels in retinopathy and a nonstandard scoring method of quantification. Since a pathologic neovascular tuft usually does

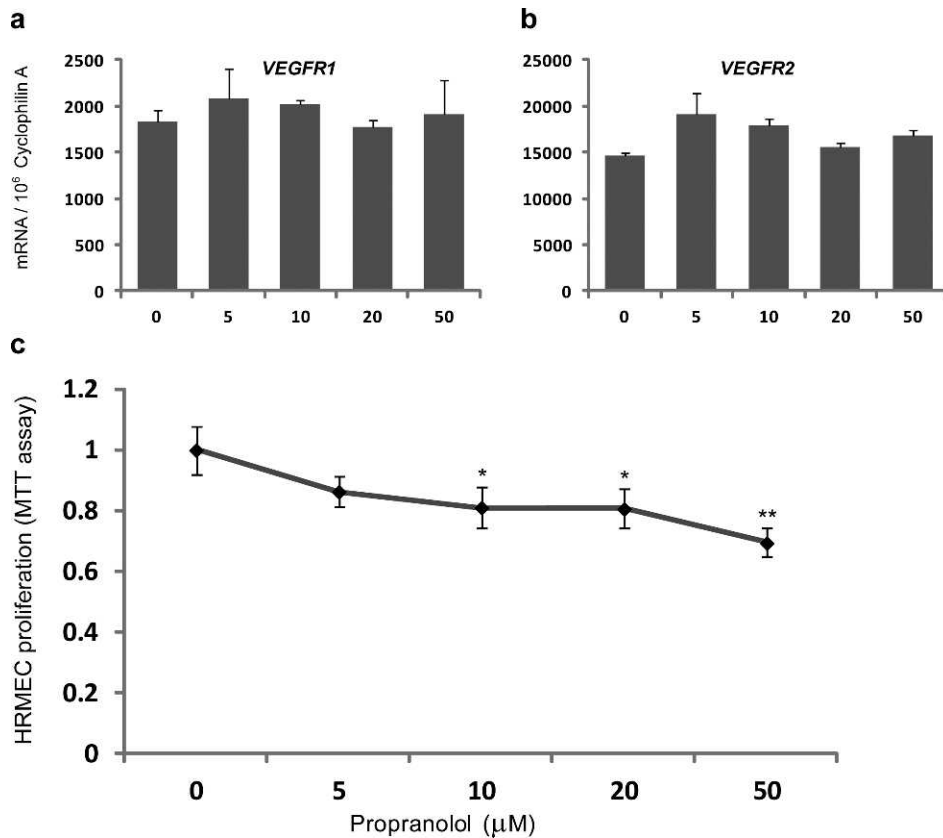


FIGURE 6. Effect of propranolol on human retinal microvascular endothelial cell culture (HRMEC). (a, b) Expression of two VEGF receptors (*VEGFR1* and *VEGFR2*) is not affected with varying concentrations of propranolol treatment (0-50 μ M, 48 hours). (c) Propranolol treatment (48 hours) suppresses HRMEC proliferation at high concentrations (>10 μ M) as measured by MMT assay. **P* < 0.05, ***P* < 0.01.

not have a fully formed lumen and is often inadequately perfused, fluorescent angiography may fail to define all pathologic vessels, compared with the standard method of staining retinal vessels in with specific endothelial markers such as isolectin or CD31.^{13,14}

Our work also showed that in OIR, propranolol at a physiologic dose does not influence retinal expression levels of VEGF, a major angiogenic growth factor regulating pathologic vessel growth in OIR and ROP. This result is consistent with our finding of propranolol's lack of protection in OIR. Similarly, another study showed that propranolol does not affect retinal VEGF induction in a diabetic rat model.²⁵ These data again do not agree with the previous study showing that propranolol suppresses VEGF production via activation of β_3 -adrenergic receptor.⁸ Interestingly, the same study also presented specific localization of β_3 -adrenergic receptors in neovascular tufts. However, in the retina, neovessels are not considered a significant source of VEGF in retinopathy, in that VEGF is secreted mostly by neuroglial cells, which do not reside in neovascular tufts or clusters but are localized in the neurosensory layers of the retina.^{26,27} It is therefore unclear how VEGF expression in these glial and neuronal cells would be altered by propranolol acting specifically on β_3 -adrenergic receptors in EC tufts. In line with this argument, an independent study ruled out a role of β_3 -adrenergic receptors in OIR, since a specific inhibitor against β_3 -adrenergic receptors (SR59230A) failed to suppress retinopathy.²⁸ This work evaluated retinopathy with standard methods of CD31 staining in retinal flatmounts, but did not reexamine the efficacy of propranolol with standard quantification methods. Together these results bring into question whether propranolol regulates retinal levels of VEGF and whether the β_3 -adrenergic receptor plays a role in retinopathy. Interestingly, we also found that the β_3 -adrenergic receptor is highly upregulated at P17 in OIR. Yet the functional role of this upregulation may not necessarily be related to pathologic angiogenesis, but may for example conversely signify a role for β_3 -adrenergic receptors in NV regression, which starts at P17, leading to complete regression of retinal tufts and clusters by P23 to P25.¹⁵

Our in vitro results using human retinal EC culture suggests that propranolol may suppress EC proliferation, but only at very high nonphysiological concentrations. This is consistent with two previous in vitro studies showing that high concentrations of propranolol suppress EC proliferation and migration,^{29,30} and increase EC apoptosis.³ The concentrations that can produce profound effects on ECs are generally higher than the doses we used in our in vivo studies of retinopathy. Consequently, failure of propranolol protection against OIR is evidence of its inability to suppress EC proliferation at lower nonapoptotic concentrations.

Interestingly in a rat model of diabetic retinopathy, activation of β -adrenergic receptor with the agonist isoproterenol is reported to be protective against diabetes-induced retinal damages,³¹ without affecting VEGF production.^{25,31} Although the disease mechanisms are different in diabetic retinopathy and OIR, these results suggest an important role of the adrenergic system in the retina as well as a potentially detrimental effect of suppressing β -adrenergic receptor, especially considering that propranolol produced decreased electroretinogram amplitudes in normal rats.³²

Although propranolol has been generally well tolerated in treating hemangiomas, serious adverse effects have been reported, including hypotension, bradycardia, and potentially serious metabolic changes such as hypoglycemia.^{33,34} Because very premature infants are at a higher risk of hypotension³⁵ and insulin resistance,³⁶ propranolol treatment may further derange glucose metabolism and lipid metabolism.³⁷ It is important to note that a highly lipophilic drug such as

propranolol can pass the blood brain barrier and reach high concentrations in the brain.³⁸ However, the roles of adrenergic system and the β -adrenergic receptor in the brain development of the premature infants are not well known. With the reports that propranolol can cause memory loss in chicks³⁹ and affects learning in rats,⁴⁰ the administration of potent beta blockers during such a critical period of brain development in preterm infants is of great concern, particularly in those infants with relatively mild stage 2 retinopathy as recruited in the clinical trial investigating the effects of propranolol (PROP-ROP).⁹ This trial uses only oral administration of propranolol (2 mg/kg/day) until NV resolves or for a maximum of 90 days. In these infants, however, ROP at stage 2 is likely to be self-limiting and regress spontaneously without treatment.¹⁰ Propranolol may thus pose an unnecessary and not well-studied risk factor for ocular and/or overall development of these infants.

References

1. Good WV. Final results of the Early Treatment for Retinopathy of Prematurity (ETROP) randomized trial. *Trans Am Ophthalmol Soc.* 2004;102:233-250.
2. Chen J, Smith LEH. Retinopathy of prematurity. *Angiogenesis.* 2007;10:133-140.
3. Léauté-Labrèze C, Dumas de la Roque E, Hubiche T, Boralevi F, Thambo JB, Taïeb A. Propranolol for severe hemangiomas of infancy. *N Engl J Med.* 2008;358:2649-2651.
4. Price CJ, Lattouf C, Baum B, et al. Propranolol vs corticosteroids for infantile hemangiomas: a multicenter retrospective analysis. *Arch Dermatol.* 2011;147:1371-1376.
5. Manunza F, Syed S, Laguda B, et al. Propranolol for complicated infantile haemangiomas: a case series of 30 infants. *Br J Dermatol.* 2010;162:466-468.
6. Peridis S, Pilgrim G, Athanasopoulos I, Parpounas K. A meta-analysis on the effectiveness of propranolol for the treatment of infantile airway haemangiomas. *Int J Pediatr Otorhinolaryngol.* 2011;75:455-460.
7. de Graaf M, Breur JM, Raphaël MF, Vos M, Breugem CC, Pasmans SG. Adverse effects of propranolol when used in the treatment of hemangiomas: a case series of 28 infants. *J Am Acad Dermatol.* 2011;65:320-327.
8. Ristori C, Filippi L, Dal Monte M, et al. Role of the adrenergic system in a mouse model of oxygen-induced retinopathy: antiangiogenic effects of beta-adrenoreceptor blockade. *Invest Ophthalmol Vis Sci.* 2011;52:155-170.
9. Filippi L, Cavallaro G, Fiorini P, et al. Study protocol: safety and efficacy of propranolol in newborns with Retinopathy of Prematurity (PROP-ROP): ISRCTN18523491 (Abstract). *BMC Pediatrics.* 2010;10:83.
10. Fledelius HC. Retinopathy of prematurity in Frederiksborg County 1988-1990. A prospective investigation, an update. *Acta Ophthalmol Suppl.* 1993;210:59-62.
11. Hård A-L, Hellström A. On the use of antiangiogenic medications for retinopathy of prematurity. *Acta Paediatr.* 2011;100:1063-1065.
12. Smith LE, Wesolowski E, McLellan A, et al. Oxygen-induced retinopathy in the mouse. *Invest Ophthalmol Vis Sci.* 1994;35:101-111.
13. Connor KM, Krah NM, Dennison RJ, et al. Quantification of oxygen-induced retinopathy in the mouse: a model of vessel loss, vessel regrowth and pathological angiogenesis. *Nat Protoc.* 2009;4:1565-1573.
14. Stahl A, Connor KM, Sapiha P, et al. Computer-aided quantification of retinal neovascularization. *Angiogenesis.* 2009;12:297-301.
15. Stahl A, Chen J, Sapiha P, et al. Postnatal weight gain modifies severity and functional outcome of oxygen-induced proliferative retinopathy. *Am J Pathol.* 2010;177:2715-2723.

16. Sapieha P, Stahl A, Chen J, et al. 5-Lipoxygenase metabolite 4-HDHA is a mediator of the antiangiogenic effect of ω -3 polyunsaturated fatty acids. *Sci Transl Med.* 2011;3:69ra12.
17. Shand DG. Pharmacokinetics of propranolol: a review. *Postgrad Med J.* 1976;52(suppl 4):22-25.
18. Sato T, Kusaka S, Shimojo H, Fujikado T. Simultaneous analyses of vitreous levels of 27 cytokines in eyes with retinopathy of prematurity. *Ophthalmology.* 2009;116:2165-2169.
19. Sato T, Kusaka S, Shimojo H, Fujikado T. Vitreous levels of erythropoietin and vascular endothelial growth factor in eyes with retinopathy of prematurity. *Ophthalmology.* 2009;116:1599-1603.
20. Sonmez K, Drenser KA, Capone A Jr, Trese MT. Vitreous levels of stromal cell-derived factor 1 and vascular endothelial growth factor in patients with retinopathy of prematurity. *Ophthalmology.* 2008;115:1065-1070.
21. Sato T, Shima C, Kusaka S. Vitreous levels of angiopoietin-1 and angiopoietin-2 in eyes with retinopathy of prematurity. *Am J Ophthalmol.* 2011;151:353-357.
22. Aiello LP, Pierce EA, Foley ED, et al. Suppression of retinal neovascularization in vivo by inhibition of vascular endothelial growth factor (VEGF) using soluble VEGF-receptor chimeric proteins. *Proc Natl Acad Sci USA.* 1995;92:10457-10461.
23. Chen J, Connor KM, Aderman CM, Smith LE. Erythropoietin deficiency decreases vascular stability in mice. *J Clin Invest.* 2008;118:526-533.
24. Chen J, Connor KM, Aderman CM, Willett KL, Aspegren OP, Smith LEH. Suppression of retinal neovascularization by erythropoietin siRNA in a mouse model of proliferative retinopathy. *Invest Ophthalmol Vis Sci.* 2009;50:1329-1335.
25. Zheng Z, Chen H, Xu X, Li C, Gu Q. Effects of angiotensin-converting enzyme inhibitors and beta-adrenergic blockers on retinal vascular endothelial growth factor expression in rat diabetic retinopathy. *Exp Eye Res.* 2007;84:745-752.
26. Pierce EA, Avery RL, Foley ED, Aiello LP, Smith LE. Vascular endothelial growth factor/vascular permeability factor expression in a mouse model of retinal neovascularization. *Proc Natl Acad Sci USA.* 1995;92:905-909.
27. Pierce EA, Foley ED, Smith LE. Regulation of vascular endothelial growth factor by oxygen in a model of retinopathy of prematurity. *Arch Ophthalmol.* 1996;114:1219-1228.
28. Martini D, Dal Monte M, Ristori C, et al. Antiangiogenic effects of β_2 -adrenergic receptor blockade in a mouse model of oxygen-induced retinopathy. *J Neurochem.* 2011;119:1317-1329.
29. Lamy S, Lachambre MP, Lord-Dufour S, Béliveau R. Propranolol suppresses angiogenesis in vitro: inhibition of proliferation, migration, and differentiation of endothelial cells. *Vascul Pharmacol.* 2010;53:200-208.
30. Steinle JJ, Booz GW, Meininger CJ, Day JN, Granger HJ. Beta 3-adrenergic receptors regulate retinal endothelial cell migration and proliferation. *J Biol Chem.* 2003;278:20681-20686.
31. Jiang Y, Walker RJ, Kern TS, Steinle JJ. Application of isoproterenol inhibits diabetic-like changes in the rat retina. *Exp Eye Res.* 2010;91:171-179.
32. Jiang Y, Steinle JJ. Systemic propranolol reduces b-wave amplitude in the ERG and increases IGF-1 receptor phosphorylation in rat retina. *Invest Ophthalmol Vis Sci.* 2010;51:2730-2735.
33. Lawley LP, Siegfried E, Todd JL. Propranolol treatment for hemangioma of infancy: risks and recommendations. *Pediatr Dermatol.* 2009;26:610-614.
34. Bonifazi E, Acquafredda A, Milano A, Montagna O, Laforgia N. Severe hypoglycemia during successful treatment of diffuse hemangiomatosis with propranolol. *Pediatr Dermatol.* 2010;27:195-196.
35. Dempsey EM, Barrington KJ. Evaluation and treatment of hypotension in the preterm infant. *Clin Perinatol.* 2009;36:75-85.
36. Mitanchez-Mokhtari D, Lahlou N, Kieffer F, Magny JF, Roger M, Voyer M. Both relative insulin resistance and defective islet beta-cell processing of proinsulin are responsible for transient hyperglycemia in extremely preterm infants. *Pediatrics.* 2004;113:537-541.
37. Fonseca VA. Effects of beta-blockers on glucose and lipid metabolism. *Curr Med Res Opin.* 2010;26:615-629.
38. Pardridge WM, Sakiyama R, Fierer G. Blood-brain barrier transport and brain sequestration of propranolol and lidocaine. *Am J Physiol Regul Integr Comp Physiol.* 1984;247:R582-R588.
39. Gibbs ME, Hutchinson DS, Summers RJ. Noradrenaline release in the locus coeruleus modulates memory formation and consolidation; roles for α - and β -adrenergic receptors. *Neuroscience.* 2010;170:1209-1222.
40. Wilson DA, Sullivan RM. Olfactory associative conditioning in infant rats with brain stimulation as reward. II. Norepinephrine mediates a specific component of the bulb response to reward. *Behav Neurosci.* 1991;105:843-849.