



Gemcitabine induced cardiomyopathy: a case of multiple hit cardiotoxicity

Citation

Mohebbali, Donya, Jason Matos, and James Ducksoon Chang. 2016. "Gemcitabine induced cardiomyopathy: a case of multiple hit cardiotoxicity." *Esc Heart Failure* 4 (1): 71-74. doi:10.1002/ehf2.12113. <http://dx.doi.org/10.1002/ehf2.12113>.

Published Version

doi:10.1002/ehf2.12113

Permanent link

<http://nrs.harvard.edu/urn-3:HUL.InstRepos:31731630>

Terms of Use

This article was downloaded from Harvard University's DASH repository, and is made available under the terms and conditions applicable to Other Posted Material, as set forth at <http://nrs.harvard.edu/urn-3:HUL.InstRepos:dash.current.terms-of-use#LAA>

Share Your Story

The Harvard community has made this article openly available.
Please share how this access benefits you. [Submit a story](#).

[Accessibility](#)

Gemcitabine induced cardiomyopathy: a case of multiple hit cardiotoxicity

Donya Mohebbali¹, Jason Matos² and James Ducksoon Chang^{3*}

¹Department of Internal Medicine, Beth Israel Deaconess Medical Center, Boston, MA, USA; ²Department of Internal Medicine, Division of Cardiology, Beth Israel Deaconess Medical Center, Boston, MA, USA; ³Program in Cardio-oncology, Department of Internal Medicine, Division of Cardiology, Beth Israel Deaconess Medical Center, Harvard Medical School, Boston, MA, USA

Abstract

Gemcitabine is a commonly used antineoplastic agent used to treat a variety of cancers with rarely reported cardiac side effects. We describe a case of a 67-year-old woman with follicular lymphoma who experienced a rarely reported side effect of gemcitabine: cardiomyopathy. This case highlights a multiple hit mechanism of myocyte damage that may occur following the use of multiple cardio-toxic agents despite their administration in doses not associated with cardiotoxicity.

Keywords Cardiomyopathy; Cardio-oncology; Chemotherapy

Received: 25 February 2016; Revised: 28 June 2016; Accepted: 8 August 2016

*Correspondence to: James Ducksoon Chang, Advanced Heart Failure Center, The Cardiovascular Institute, Beth Israel Deaconess Medical Center, Harvard Medical School, 330 Brookline Avenue, Boston, MA 02215, USA. Tel: +1 617 632 7752; Fax: +1 617 632 7760. Email: jchang@bidmc.harvard.edu

Introduction

Gemcitabine is a commonly used antineoplastic agent that is a nucleoside analog and pyrimidine antimetabolite that inhibits RNA synthesis.¹ It is most commonly used in solid organ malignancies such as non-small cell lung cancer, and breast, ovarian, and pancreatic cancer, although is also used in diffuse large B-cell lymphoma in relapsed or refractory elderly patients.² It has rare cardiac side effects including acute myocardial infarction, but is not well known to cause cardiomyopathy.

Case report

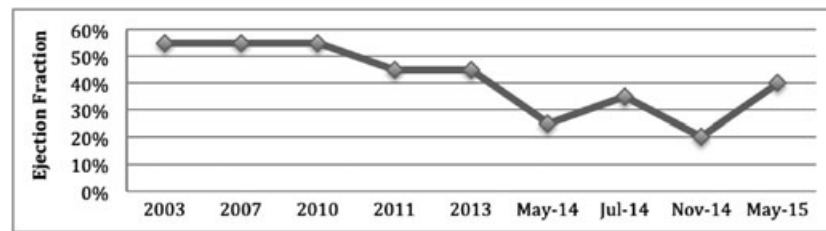
A 67-year-old woman with past medical history significant for follicular lymphoma with transformation to diffuse large B cell lymphoma status post multiple cycles of chemotherapy complicated by transient left ventricular systolic dysfunction presented with sensation of throat closing and difficulty breathing upon completion of Cycle 2 of Rituximab plus Gemcitabine and Oxaliplatin (R-GemOx).

Her follicular lymphoma was initially diagnosed in 2007 and treated with Rituximab, Cyclophosphamide, Doxorubicin, and

Vincristine (R-CHOP). Prior to initiation of chemotherapy, her left ventricular ejection fraction (LVEF) was normal. Three years following treatment with doxorubicin, her LVEF remained normal. Her only risk factor for cardiovascular disease was hyperlipidemia (total cholesterol 248 mg/dL, LDL 171 mg/dL); with no known hypertension, diabetes, or family history of coronary disease, and a normal exercise nuclear stress test.

In 2010, her cancer transformed to diffuse large B cell lymphoma (DLBCL) requiring autologous stem cell transplant. She was then treated with Rituximab, Ifosfamide, Carboplatin, and Etoposide (R-ICE). Her disease remained in remission until 2013. At that time, a left groin biopsy revealed recurrent DLBCL. She was placed on Bretuximab/Rituximab, but once her disease progressed on this regimen, she was transitioned to Rituximab, Dexamethasone, Cytarabine, and platinum (R-DHAP). One month into treatment with R-DHAP, the patient's echocardiogram showed severely depressed LVEF (25–30%) with global hypokinesis. R-DHAP was discontinued, and a repeat echocardiogram 3 months later showed an improved LVEF to 35–40% (Figure 1, Table 1). All ejection fractions were determined by visual estimation.

In October 2014, Rituximab, Gemcitabine, and Oxaliplatin (R-Gem-Ox) were started. One month later, the patient presented to the hospital with sensation of

Figure 1 Ejection fraction over time.**Table 1** Chemotherapy agent by year, drug class, and frequency of cardiac adverse event

Date	Chemotherapy/treatment regimen	Drug class/name	Cardiac adverse event	Frequency of adverse effect
2003	None			
2007	R-CHOP ^a	Anthracycline/donorubicin	CHF/LV dysfunction	+++
2010	Autologous stem cell transplant (cytoxan-cardiotoxic)	Alkylating agent/cytoxan (cyclophosphamide)	Pericarditis/myocarditis CHF	+ ++
05/2011	R-ICE ^b	Biologic agent/rituximab	Arrhythmias	++
11/2013	Bretuximab/rituximab	Biologic agent/rituximab	Arrhythmias	++
05/2014	R-DHAP ^c (04/2014)	Alkylating agents/cisplatin	Ischemia Hypertension CHF	++ ++++ +++
07/2014	None			
11/2014	R-GemOx ^a	Pyrimidine analog/gemcitabine	Supraventricular Tachycardia Ischemia cardiomyopathy	++ ++ +
05/2015	None			

^aRituximab, gemcitabine, oxaliplatin.

^bRituximab, ifosfamide, carboplatin, and etoposide.

^cRituximab, cyclophosphamide, doxorubicin, and vincristine.

throat closing and difficulty breathing. She was admitted with suspicion of laryngospasm from Oxaliplatin. Upon further questioning, since initiation of R-GemOx, the patient noted exertional dyspnea and fatigue. She was previously able to walk three to four laps around her local shopping mall although now endorsed dyspnea upon ambulation to the nearby bathroom.

On examination, she was found to have a new oxygen requirement and a 7 pound weight gain. Her jugular venous pressure was elevated with diminished bibasilar lung sounds and 2+ pitting edema of the lower extremities. Cardiac auscultation revealed an S3 gallop and III/VI holosystolic murmur. Chest X-ray showed bilateral pleural effusions. NT pro-BNP was noted to be 40 000 with a lactate of 4.2. EKG demonstrated no acute ST or T wave changes. Transthoracic echocardiogram revealed an LVEF of 20% with global free wall hypokinesis and severe mitral regurgitation. The patient was treated with intravenous furosemide. Her renal function subsequently improved and lactate normalized. Home dosing of lisinopril and beta-blocker were reintroduced. Given the concern for gemcitabine-induced cardiomyopathy, this agent was discontinued. Repeat echocardiogram 6 months later

showed an improved LVEF of 40% and mild mitral regurgitation.

Discussion

Our patient was exposed to multiple chemotherapy agents with known cardio-toxicity, and her ejection fraction therefore fluctuated throughout the course of her treatment. Cardiomyocytes, as well as other cell types comprising the heart, have a limited capacity for repair after sustaining injury from one agent or another. Perhaps, the most cogent example of the multiple hit hypothesis is found in cardiotoxicity occurring after chemotherapy for HER-2/neu-amplified breast cancer. When administered alone, the anti-HER-2/neu monoclonal antibody trastuzumab is associated with a low incidence of subsequent left ventricular contractile dysfunction, in the range of 4–6%.³ However, when administered after an anthracycline-based adjuvant regimen, the incidence of left ventricular systolic dysfunction is as high as 28%.³ The most plausible explanation for this finding is that when

anthracycline-induced cardiomyocyte injury occurs, the limited ability of cardiomyocytes to repair this damage is abrogated by the subsequent administration of trastuzumab, which, by inhibiting HER-2/neu-dependent signalling (including phosphoinositide 3-kinase/Akt) in the cardiomyocyte, inactivates cell survival pathways.

Our patient was initially exposed to doxorubicin at a total cumulative dose of 450 mg/m². The mechanism of cardiotoxicity here involves disruption of topoisomerase-II-mediated DNA repair and generation of oxygen-derived free radicals.^{4–7} Serial echocardiograms during several years after doxorubicin administration showed stable LVEF. The fact that her LVEF fluctuated, rather than displaying a secular downward trend, in her later course is more consistent with acute cardiomyocyte injury following administration of individual agents, and not with chronic anthracycline-induced left ventricular systolic dysfunction which is irreversible.

Three years after treatment with doxorubicin, the patient was exposed to cyclophosphamide at the time of her stem cell transplant. Cyclophosphamide can cause endothelial and myocyte injury mediated through its toxic metabolic phosphoramidate mustard that leads to DNA crosslinking and subsequent apoptosis.⁴ The patient was then exposed to R-DHAP, of which, cisplatin has been shown to cause congestive heart failure, particularly in the elderly. Its mode of toxicity involves crosslinking with purine bases on the DNA and thus interfering with DNA repair mechanisms, causing DNA damage and cell apoptosis.^{4,6}

Following cessation of R-DHAP, and prior to initiation of GemOx, our patient's LVEF improved to 35–40%. After two cycles of R-GemOx, her LVEF became severely depressed to 20–25%. Oxaliplatin, although commonly known for many side effects including laryngospasm (for which the patient was likely initially referred for hospitalization), peripheral neuropathy, and ototoxicity, is not associated with cardiomyopathy. The co-administration of this agent with intravenous fluids may have contributed to volume overload. However, this alone would not explain the abrupt development of acute kidney injury, lactic acidosis, and pronounced drop in ejection fraction. The more likely culprit for this was gemcitabine. Acute kidney injury and lactic acidosis resolved with intravenous diuresis. Upon cessation of gemcitabine, the patient's LVEF improved to 40%, near her baseline prior to initiation of all chemotherapy agents.

Cardiotoxicity secondary to gemcitabine has rarely been reported in the literature.

A handful of case reports describe arrhythmias as a side effect of gemcitabine use. Most of these report supraventricular tachycardias including atrial fibrillation.^{8,9} Atrial fibrillation is typically seen 18–24 h of infusion. This side effect is likely because of a gemcitabine metabolite, 2',2'-difluorodeoxyuridine (diFdU), which has an equivalent half-life of approximately 18–24 h similar to the time of onset of atrial fibrillation.^{8,9} Several case reports have demonstrated acute myocardial

infarction acutely post-gemcitabine infection secondary to drug-induced vascular injury or endothelial damage.^{10–12}

Of all the possible cardiac toxicities, cardiomyopathy appears to be the least reported. In phase I clinical trials of gemcitabine use, significant reduction in LVEF occurred in 0.2% of patient, whereas 0.4–1.7% of patients developed cardiac arrhythmias.¹³ Review of the literature of phase II clinical trials of approximately 979 patients revealed 0.2% arrhythmias, 0.4% cardiomyopathies, and 0.2% with exudative pericarditis.¹⁴ In these trials, patients who developed cardiomyopathies had underlying coronary artery disease, whereas our patient had no history of coronary disease. Outside of clinical trials, gemcitabine-induced cardiomyopathy has been reported only once in the literature.² The patient described was similar to ours. He did not have prior coronary artery disease or risk factors. As with our described case, the patient presented with signs and symptoms of congestive heart failure after the second cycle of gemcitabine for pancreatic cancer. The patient's LVEF at the time of presentation with symptoms of exertional dyspnea was noted to be 15–20% with findings of global hypokinesis in addition to functional mitral regurgitation. Gemcitabine was discontinued, and two months later an echocardiogram showed recovery of LVEF to 40% and resolution of mitral regurgitation.

We propose a multiple hit mechanism that ultimately led to a severely depressed LVEF in our patient. The delayed toxicity of doxorubicin, in combination with the direct cytotoxic effects and apoptosis seen with cyclophosphamide, led to her initial drop in LVEF.^{4,15} Subsequent exposure to cisplatin in May 2014 further damaged DNA repair mechanisms and quickly depressed our patient's LVEF to 25%. Upon discontinuation of cisplatin, her LVEF rapidly improved to 35–40%. It was not until the administration of gemcitabine in November 2014 that her LVEF once again decreased to 25%.

The primary message of our report is that the administration of multiple cytotoxic cancer treatments, each with a different mechanism of action, can result in major cardiotoxicity despite being given in doses that for each individual agent may not be cardiotoxic. In the era of combination chemotherapy employing multiple chemotherapeutic drugs, it is important to recognize that an interaction may exist between the effects of individual agents resulting in cardiac dysfunction that is either unexpected or more severe than expected.

Conclusions

This case highlights a multiple hit mechanism of cardiomyocyte damage that may occur when employing multiple cardio-toxic agents in doses that, individually, may not be associated with cardiotoxicity.

Conflicts of interest

None declared.

References

1. Plunkett W, Huang P, Xu YZ, Heinemann V, Grunewald R, Gandhi V. Gemcitabine: metabolism, mechanisms of action, and self-potential. *Semin Oncol* 1995; **22**: 3–10.
2. Khan M, Gottesman S, Boyella R, Juneman E. Gemcitabine-induced cardiomyopathy: a case report and review of the literature. *J Med Case Rep* 2014; **8**: 220 previously.
3. Ewe MS, Ewer SM. Cardiotoxicity of anticancer treatments: what the cardiologist needs to know. *Nat Rev Cardiol* 2010; **7**: 564–575.
4. Yeh E. Cardiovascular complications of cancer therapy: diagnosis, pathogenesis, and management. *Circulation* 2004; **109**: 3122–3131.
5. Thorn C, Oshiro C, Marsh S, Hernandez-Boussard T, McLeod H, Klein T. Doxorubicin pathways. *Pharmacogenetics and Genomics* 2011; **21**: 440–446.
6. Shakir D. Chemotherapy induced cardiomyopathy: pathogenesis, monitoring and management. *J Clin Med Res* 2009; **1**: 8–12.
7. Kremer C. Anthracycline-induced clinical heart failure in a cohort of 607 children: long-term follow-up study. *Journal of Clinical Oncology*. 2001; **19**: 191–196.
8. Ferrari D, Carbone C, Codeca C, Fumagalli L, Gilardi L, Marussi D, Tartaro T, Oldani S, Zannier F, Foa P. Gemcitabine and atrial fibrillation: a rare manifestation of chemotherapy toxicity. *Anti-Cancer Drugs* 2006; **17**: 359–361.
9. Santini D, Tonini G, Abbate A, Di Cosimo S, Gravante G, Vincenzi B. Gemcitabine-induced atrial fibrillation: a hitherto unreported manifestation of drug toxicity. *Ann Oncol*. 2000; **11**: 479–481.
10. Bdair F, Graham S, Smith P, Javle M. Gemcitabine and acute myocardial infarction: a case report. *Angiology* 2006; **57**: 367–371.
11. Kalapura T, Krishnamurthy M, Reddy C, Reddy C. Acute myocardial infarction following gemcitabine therapy: a case report. *Angiology* 1999; **50**: 1021–1025.
12. Dasanu C. Gemcitabine: vascular toxicity and prothrombotic potential. *Expert Opin Drug Saf* 2008; **7**: 703–716.
13. Storniolo A, Allerheiligen S, Pearce H. Preclinical, pharmacologic, and phase I studies of gemcitabine. *Semin Oncol* 1997; **24**: 2–7.
14. Duvic M, Talpur R, Wen S, Kurzrock R, David C, Apisarnthanarax N. Phase II evaluation of gemcitabine monotherapy for cutaneous T-cell lymphoma. *Clinical Lymphoma and Myeloma* 2006; **7**: 51–58.
15. Atalay F, Gulmez O, Ozsancak A. Cardiotoxicity following cyclophosphamide therapy: a case report. *Journal of Medical Case Reports* 2014; **8**: 252.