



Anti-PD-1-Related Pneumonitis during Cancer Immunotherapy

The Harvard community has made this
article openly available. [Please share](#) how
this access benefits you. Your story matters

Citation	Nishino, Mizuki, Lynette M. Sholl, Hiroto Hatabu, Nikhil H. Ramaiya, and F. Stephen Hodi. 2015. "Anti-PD-1-Related Pneumonitis During Cancer Immunotherapy." <i>New England Journal of Medicine</i> 373 (3) (July 16): 288-290. doi:10.1056/nejmc1505197.
Published Version	doi:10.1056/NEJMc1505197
Citable link	http://nrs.harvard.edu/urn-3:HUL.InstRepos:32705581
Terms of Use	This article was downloaded from Harvard University's DASH repository, and is made available under the terms and conditions applicable to Other Posted Material, as set forth at http://nrs.harvard.edu/urn-3:HUL.InstRepos:dash.current.terms-of-use#LAA

worse outcomes than outcomes after colectomy, and the ability to undergo reanastomosis after recovery is a benefit of an intact colon. Although data are lacking on which surgical technique offers the best survival and long-term outcomes, we would argue that this question is secondary to the question of how best to predict which patients will not have a response to antibiotic therapy and would benefit from surgery before becoming critically ill. Recently published results of a study on predicting severe *C. difficile* infection may help to inform this difficult clinical decision.⁵

Daniel A. Leffler, M.D.

J. Thomas Lamont, M.D.

Beth Israel Deaconess Medical Center
Boston, MA
dleffler@bidmc.harvard.edu

Since publication of their article, the authors report no further potential conflict of interest.

1. Seto CT, Jeraldo P, Orenstein R, Chia N, DiBaise JK. Prolonged use of a proton pump inhibitor reduces microbial diversity: implications for *Clostridium difficile* susceptibility. *Microbiome* 2014;2:42.
2. Novack L, Kogan S, Gimpelevich L, et al. Acid suppression therapy does not predispose to *Clostridium difficile* infection: the case of the potential bias. *PLoS One* 2014;9(10):e110790.
3. Gerding DN, Meyer T, Lee C, et al. Administration of spores of nontoxicogenic *Clostridium difficile* strain M3 for prevention of recurrent *C. difficile* infection: a randomized clinical trial. *JAMA* 2015;313:1719-27.
4. Stewart DB, Hollenbeak CS, Wilson MZ. Is colectomy for fulminant *Clostridium difficile* colitis life saving? A systematic review. *Colorectal Dis* 2013;15:798-804.
5. Na X, Martin AJ, Sethi S, et al. A multi-center prospective derivation and validation of a clinical prediction tool for severe *Clostridium difficile* infection. *PLoS One* 2015;10(4):e0123405.

DOI: 10.1056/NEJMc1506004

Anti-PD-1-Related Pneumonitis during Cancer Immunotherapy

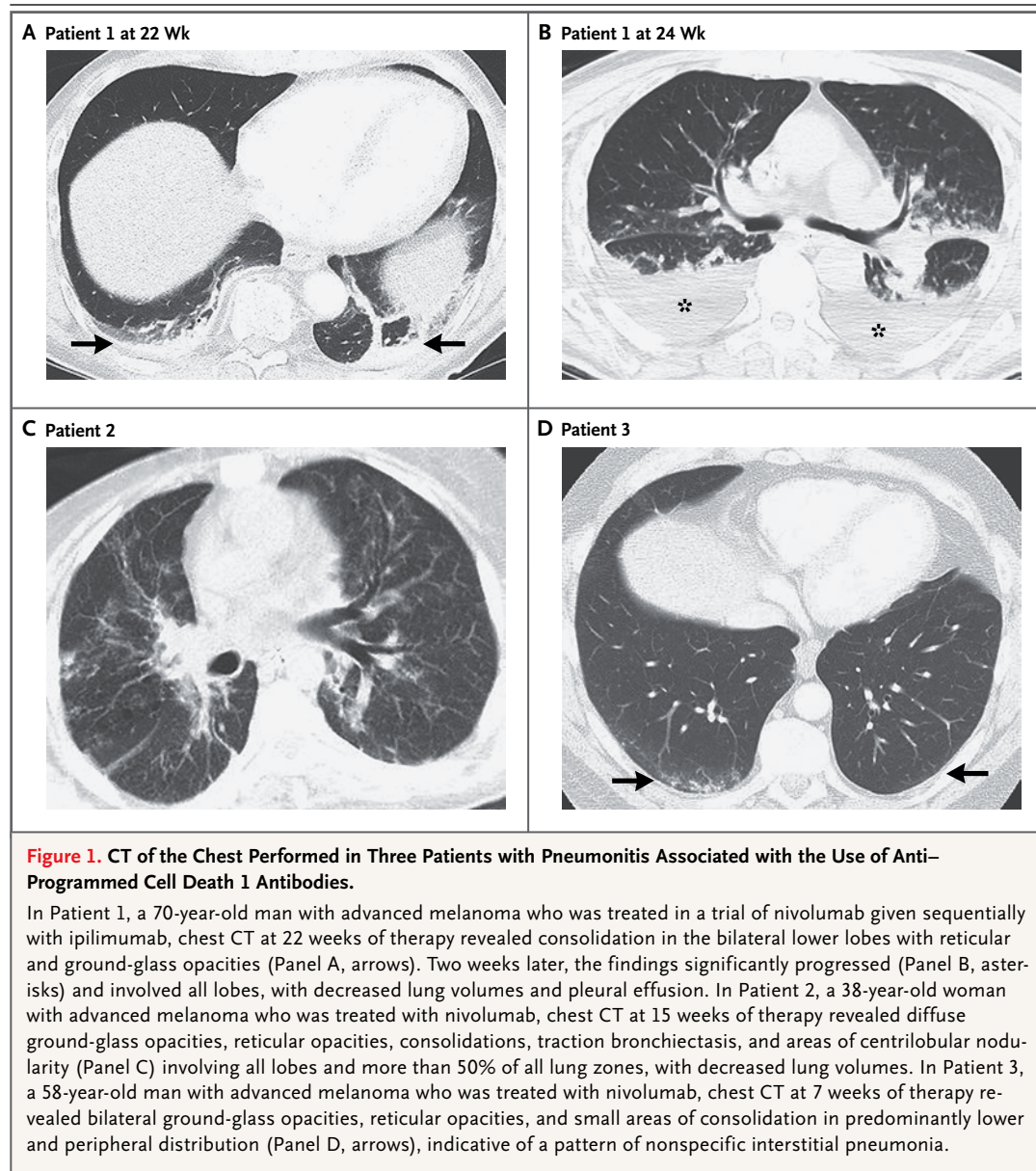
TO THE EDITOR: The use of antibodies against programmed cell death 1 (PD-1), which block inhibitory T-cell checkpoints, is a promising new therapy for advanced cancers.¹ Recent trials have shown substantial clinical activity of anti-PD-1 antibodies in advanced cancers and led to the approvals of these agents, including pembrolizumab for melanoma and nivolumab for melanoma and squamous-cell lung cancer.²⁻⁴ Pneumonitis related to the use of antibodies against PD-1 is an immune-mediated toxic effect that resulted in three drug-related deaths in a phase 1 trial.¹ Clinical identification and management of pneumonitis are contingent on radiographic assessment. We report three cases of pneumonitis associated with the use of anti-PD-1 antibodies in patients with melanoma.

A 70-year-old man (Patient 1) received nivolumab and ipilimumab sequentially. A 38-year-old woman (Patient 2) and a 58-year-old man (Patient 3) were treated with nivolumab alone; Patient 2 had previously received ipilimumab before starting the nivolumab trial. The onset of pneumonitis occurred 7.4 to 24.3 months after the initiation of therapy (Table S1 in the Supplementary Appendix, available with the full text of this letter at NEJM.org). Computed tomographic

(CT) imaging of pneumonitis at the time of diagnosis showed a spectrum of findings that are typically seen in interstitial pneumonias.⁵ These conditions were morphologically classified as acute interstitial pneumonia-acute respiratory distress syndrome (ARDS) in Patients 1 and 2 and as nonspecific interstitial pneumonia in Patient 3 (Table S2 in the Supplementary Appendix).

In Patients 1 and 2 with ARDS-pattern pneumonitis, diffuse ground-glass opacities, reticular opacities, consolidation, and traction bronchiectasis involved all lobes, with decreased lung volumes and effusions (Fig. 1A, 1B, and 1C). In Patient 1, the symptoms rapidly progressed during the 2 weeks before the diagnosis (Fig. 1A and 1B). The two patients were admitted to the intensive care unit and received intravenous antibiotic agents, glucocorticoids, and infliximab. Patient 1 required intubation, and his condition improved over the course of 10 weeks. Patient 2 died 4 weeks after the diagnosis of pneumonitis.

Patient 3 had ground-glass opacities and reticular opacities in the peripheral and lower lungs, indicative of nonspecific interstitial pneumonia (Fig. 1D). He discontinued nivolumab for 8 weeks and received oral glucocorticoids as an outpatient, and the pneumonitis resolved after



2 weeks. The patient restarted nivolumab and has completed the 2-year treatment period with 12 cycles; he is currently participating in the follow-up period of the trial. He remains progression-free from melanoma, with no recurrent pneumonitis for 39 months.

The clinical oncology community has rapidly expanding access to a variety of immunotherapeutic agents for the treatment of several types of cancers. Thus, knowledge of the spectrum of

manifestations of autoimmune pneumonitis may assist other clinicians in managing this rare but potentially serious toxic effect.

Mizuki Nishino, M.D.

Lynette M. Sholl, M.D.

F. Stephen Hodi, M.D.

Dana-Farber/Brigham and Women's Cancer Center

Boston, MA

mizuki_nishino@dfci.harvard.edu

and Others

A complete list of authors is available with the full text of this letter at NEJM.org.

Supported by a grant from the National Cancer Institute (1K23CA157631, to Dr. Nishino).

Disclosure forms provided by the authors are available with the full text of this letter at NEJM.org.

1. Topalian SL, Hodi FS, Brahmer JR, et al. Safety, activity, and immune correlates of anti-PD-1 antibody in cancer. *N Engl J Med* 2012;366:2443-54.
2. Rizvi NA, Mazières J, Planchard D, et al. Activity and safety of nivolumab, an anti-PD-1 immune checkpoint inhibitor, for patients with advanced, refractory squamous non-small-cell lung cancer (CheckMate 063): a phase 2, single-arm trial. *Lancet Oncol* 2015;16:257-65.
3. Topalian SL, Sznol M, McDermott DF, et al. Survival, durable

tumor remission, and long-term safety in patients with advanced melanoma receiving nivolumab. *J Clin Oncol* 2014;32:1020-30.

4. Robert C, Ribas A, Wolchok JD, et al. Anti-programmed-death-receptor-1 treatment with pembrolizumab in ipilimumab-refractory advanced melanoma: a randomised dose-comparison cohort of a phase 1 trial. *Lancet* 2014;384:1109-17.

5. American Thoracic Society, European Respiratory Society. American Thoracic Society/European Respiratory Society International Multidisciplinary Consensus Classification of the Idiopathic Interstitial Pneumonias: this joint statement of the American Thoracic Society (ATS), and the European Respiratory Society (ERS) was adopted by the ATS board of directors, June 2001 and by the ERS Executive Committee, June 2001. *Am J Respir Crit Care Med* 2002;165:277-304.

DOI: 10.1056/NEJMc1505197

Linezolid for XDR-TB — Final Study Outcomes

TO THE EDITOR: We previously reported 4-month culture conversion rates among patients with chronic extensively drug-resistant tuberculosis (XDR-TB) who received linezolid.¹ By 4 months, 15 of 19 patients (79%) in the immediate-start group and 7 of 20 (35%) in the delayed-start group had conversion to a negative sputum culture (P=0.001). After 6 months of linezolid treatment, 34 of 39 patients (87%) had negative sputum cultures. Here, we report final study outcomes for these patients 1 year after the end of treatment, 36 months after they began the study.

Among 39 patients who were enrolled in this trial, 38 received linezolid. Of these patients, 27 had negative results on sputum culture 1 year after the end of treatment, 3 were lost to follow-up, and 8 withdrew before the end of the study, including the 4 patients in whom linezolid failed, as reported previously. The median duration of tuberculosis treatment was 789 days overall, with 781 days of linezolid. Final regimens included any remaining active second-line drugs (as described in the Supplementary Appendix of our original article, available with the full text of the article at NEJM.org).

Among the 27 patients who completed the study, 4 had a dose reduction from 600 mg to 300 mg of linezolid per day before the second randomization. Among the 13 patients who were assigned to continue receiving the 600-mg dose, 9 had a subsequent reduction in the dose to 300 mg. All the dose reductions were due to

adverse events. Additional serious adverse events beyond our original report included 3 patients with optic neuropathies and 1 with anemia; all these conditions resolved after the discontinuation of linezolid.

Acquired linezolid resistance was observed only in the 4 patients who were originally reported (11% of the 38 patients who received linezolid). This observed rate with monotherapy may be related to the infrequent emergence of resistance to this drug that has been observed in vitro.² Thus, 27 of 38 patients (71%) with chronic XDR-TB were cured of the infection at 1 year after the termination of the study.

In the 2 years since our original report, the results of one additional prospective clinical trial of linezolid for XDR-TB have been published, with findings reported at the end of the study.³ Our final study results provide prospective evidence of the durable efficacy of linezolid for the treatment of XDR-TB, although our findings are limited by the small number of patients. Because relapses in TB mainly occur in the first year,⁴ the lack of relapses in our cohort is reassuring.

This report adds to the growing evidence of the efficacy of linezolid for XDR-TB, with use that was limited by side effects.⁵ Notably, these side effects were dose-related, which suggests that in future trials involving a lower dose of linezolid, the drug may have an improved side-effect profile. Newer oxazolidinones, some of which have shown potent activity against *Mycobacterium tuberculosis* in vitro, are also in develop-