



Trans-Fontan baffle placement of an endocardial systemic ventricular pacing lead

Citation

DeWitt, Elizabeth, Ryan Callahan, Elizabeth Blume, Audrey Marshall, and Douglas Mah. 2016. "Trans-Fontan baffle placement of an endocardial systemic ventricular pacing lead." *HeartRhythm Case Reports* 3 (2): 129-132. doi:10.1016/j.hrcre.2016.10.002. <http://dx.doi.org/10.1016/j.hrcre.2016.10.002>.

Published Version

doi:10.1016/j.hrcre.2016.10.002

Permanent link

<http://nrs.harvard.edu/urn-3:HUL.InstRepos:33029706>

Terms of Use

This article was downloaded from Harvard University's DASH repository, and is made available under the terms and conditions applicable to Other Posted Material, as set forth at <http://nrs.harvard.edu/urn-3:HUL.InstRepos:dash.current.terms-of-use#LAA>

Share Your Story

The Harvard community has made this article openly available. Please share how this access benefits you. [Submit a story](#).

[Accessibility](#)

Trans-Fontan baffle placement of an endocardial systemic ventricular pacing lead



Elizabeth DeWitt, MD, Ryan Callahan, MD, Elizabeth Blume, MD, Audrey Marshall, MD, Douglas Mah, MD

From the Department of Cardiology, Boston Children's Hospital, Harvard Medical School, Boston, Massachusetts.

Introduction

Patients with single-ventricle physiology palliated to a Fontan can be at risk for high-grade atrioventricular block, necessitating permanent pacemaker placement. Historically, epicardial leads have been used for these patients given the concern for clot formation within the Fontan pathway or systemic ventricle. However, epicardial pacing systems are fraught with issues, including higher pacing thresholds and increased risk for lead failure. Given this, transvenous leads are being used more routinely for atrial pacing,¹ with some case reports even reporting atrial leads within the pulmonary venous atrium.^{2,3} This is the first report of a transvenous ventricular lead in a Fontan patient.

Case presentation

An 11-year-old boy with hypoplastic left heart syndrome (mitral stenosis / aortic stenosis) presented after staged palliation that culminated in a lateral tunnel Fontan and a prosthetic aortic valve. He had a permanent epicardial pacemaker placed previously owing to surgical complete heart block and no escape rate.

A biventricular repair was initially attempted, with his earlier surgeries performed to “recruit” his left ventricle (LV), while also providing palliation for his circulation. These included initial stage I with Sano conduit, with extensive endocardial fibroelastosis resection, and a fenestrated atrial septal defect closure and a subsequent bidirectional Glenn, with enlargement of his atrial septal defect, endocardial fibroelastosis resection, and mitral and aortic valvuloplasty. This was complicated by severe native aortic valve regurgitation and aortic stenosis, and he consequently underwent aortic valve replacement at 3 years of age. Despite interval growth of his LV following these procedures, his

ventricular compliance remained poor and he ultimately was palliated to a lateral tunnel fenestrated Fontan at 4 years of age, with re-replacement of his aortic valve that resulted in complete heart block with no escape rate. He therefore underwent insertion of a dual-chamber “biventricular” pacing system, with epicardial bipolar leads placed on the right atrium and the anterior apical portion of the right ventricle (RV), and a unipolar lead on the apical posterior LV, tunneled to an abdominal generator.

The patient subsequently developed failing Fontan physiology, presenting at age 10 years with ascites and severe mitral and aortic regurgitation. His prosthetic aortic valve was replaced with a 21-mm Magna valve and a repeat mitral valvuloplasty was performed. Given elevated pacing thresholds on both ventricular leads, 2 new screw-in leads were placed on the anterior RV, his chronic LV lead was removed, and the existing apical RV lead was left in position. Given his multiple prior surgeries and sternotomies, finding a paceable area on the epicardial surface of his RV was difficult, with the surgeon sampling numerous spots before finding tissue with an acceptable capture threshold. Unfortunately, his new RV lead was noted to have increasing thresholds several weeks after the leads were replaced. Despite changing of the lead to a unipolar pacing setting, the thresholds continued to climb over a period of 8 months, eventually leading to the decision to revise his pacing system. In the meantime, the patient's clinical condition and RV function deteriorated, resulting in the patient's being listed Status 1B for transplant.

A left lateral thoracotomy was performed at the time of this surgery to offer improved exposure and 2 posterior unipolar RV screw-in epicardial leads were placed and connected with a Y-adaptor. Acute exit block was noted several days later on 1 of the poles, resulting in a shift to a unipolar pacing configuration prior to discharge. Unfortunately, he presented to his local cardiologist 2 months later after an episode of syncope. Interrogation of his pacemaker showed a significant rise in his ventricular capture threshold.

With the difficulty in placing the patient's 2 prior epicardial leads and the lack of paceable tissue noted from both an anterior and posterior approach, the decision was

KEYWORDS Pediatrics; Congenital heart disease; Single ventricle; Pacing; Fontan (Heart Rhythm Case Reports 2017;3:129–132)

Dr DeWitt's salary is supported in part by a National Institutes of Health T32 Training Grant (Grant number 2T32HL7572-32). **Address reprint requests and correspondence:** Dr Elizabeth DeWitt, Department of Cardiology, Boston Children's Hospital, 300 Longwood Avenue, Boston, MA 02115. E-mail address: elizabeth.dewitt@cardio.chboston.org.

KEY TEACHING POINTS

- Patients with complex congenital heart disease often have indications for pacing, but their anatomy may limit traditional approaches to lead placement.
- Transbaffle atrial pacing has been described previously in single-ventricle patients with Fontan palliation for sinus node dysfunction, but a systemic ventricular lead placed via baffle approach has not previously been described.
- In a complex single-ventricle patient who had failed epicardial lead placement, transbaffle ventricular lead placement was accomplished with no evidence of ventricular thrombus and resulted in improved and stable ventricular pacing thresholds in over 1 year of follow-up.

made in concert with the patient's outpatient cardiologist, surgeon, heart failure specialist, and electrophysiologist to attempt placement of an endocardial systemic right ventricular lead via a transbaffle puncture. As he was already on Coumadin for his prosthetic aortic valve, no changes were made to his anticoagulation regimen.

Description of procedure

Informed consent pertaining to the procedure, including the risk of thromboembolic complications, was obtained from the patient's parents prior to the procedure. The patient was brought to the cardiac catheterization laboratory and placed under general anesthesia. Access was obtained in the right femoral vein, right femoral artery, right internal jugular vein (RIJV), and the left subclavian vein (LSCV).

A Fontan baffle angiogram was obtained and demonstrated an unobstructed Fontan pathway with no existing baffle leaks identified. A location at the superior/posterior aspect of the Fontan baffle, adjacent to the previously placed lateral tunnel stent, was chosen for transbaffle puncture. Via the RIJV approach, a transseptal sheath was introduced. Transbaffle puncture was performed with a Brockenbrough transseptal needle directed leftward and slightly anterior into the atrium (**Figure 1**). After the sheath was advanced into the atrium, the needle and dilator were removed. A balloon end-hole catheter was advanced into the RV and replaced by an Amplatzer super-stiff wire (distal end manually curved). A 5-mm high-pressure balloon was advanced over the wire and positioned across the puncture site; the sheath was then withdrawn to the Fontan side of the circuit and the site was dilated by hand. Via the LSCV approach, a cut Judkins left coronary catheter guided a torque wire through the newly created baffle puncture alongside the super-stiff wire and into the heart. After catheter position in the RV apex was secured with a balloon end-hole catheter, the super-stiff wire was removed from the RIJV sheath and placed in the RV apex via the LSCV catheter. A Medtronic 7F S5 sheath was then advanced into the RV over the wire. Once the sheath was in position, a Medtronic SelectSecure 3830 bipolar lead was inserted through the sheath and secured to the septal aspect of the mid-RV. After stable capture and sensing thresholds were confirmed, the lead was secured in a prepectoral pocket and then tunneled down to the abdominal pocket and inserted into the patient's old Medtronic CRT-P generator (**Figure 2**).

One year after this transvenous lead implant, the patient continues to have moderate RV dysfunction but his clinical status has improved such that his listing status for transplant was downgraded to Status 2. He remains on Coumadin and his international normalized ratios are followed closely. His transvenous ventricular pacing lead tests well, with stable pacing characteristics. A cardiac computed tomography was performed, noting no thrombus within the Fontan pathway,

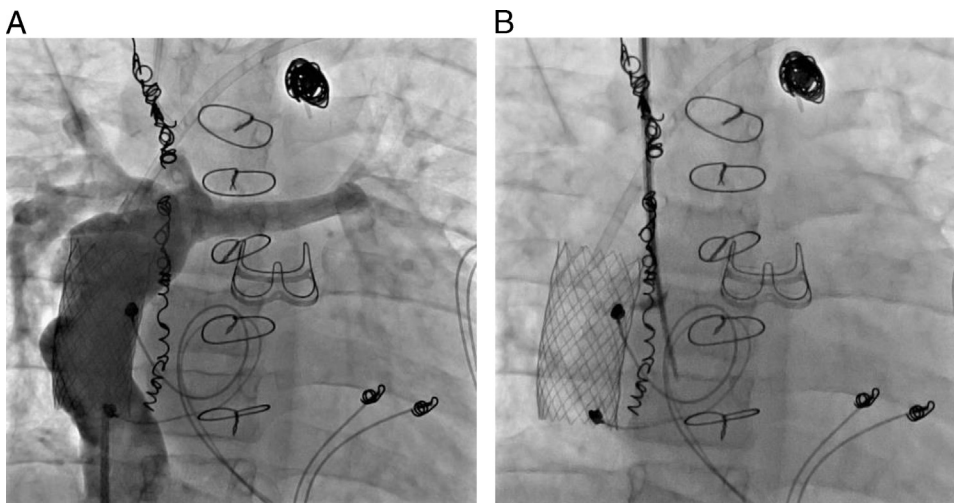


Figure 1 A: Anteroposterior projection of Fontan baffle angiogram demonstrating the unobstructed Fontan pathway with no significant baffle leaks observed. B: Transseptal needle visualized puncturing through wall of baffle. Contrast stain is visible in the baffle wall at the location of perforation. The needle and dilator are advanced into the systemic venous atrium.

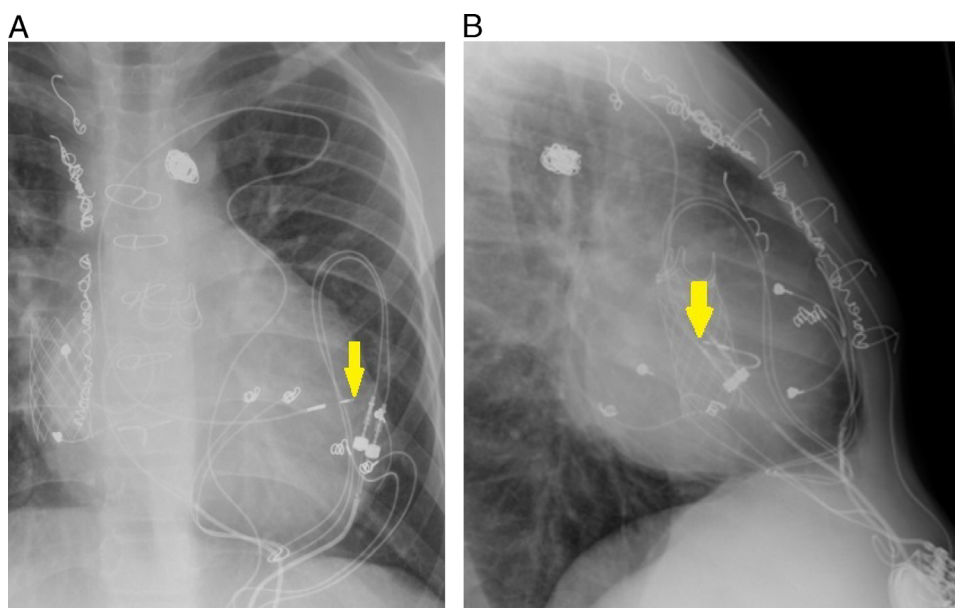


Figure 2 Chest radiographs of the pacing system with arrow showing the new transvenous ventricular pacing lead. **A:** Posteroanterior. **B:** Lateral.

pulmonary venous atrium, and systemic ventricle, and a cardiac catheterization performed around the same time also demonstrated no evidence of thrombus. He will continue to receive follow-up in the heart failure clinic every 3 months and will be evaluated every 6–12 months in the pacemaker clinic, with another computed tomography scan to assess for intracardiac thrombus in 1–2 years.

Discussion

This report represents the first case in the medical literature describing the successful placement of an endocardial ventricular pacing lead via a trans-Fontan-baffle puncture in a patient with a systemic single ventricle.

The use of pacemakers in Fontan patients is common. With sinus node dysfunction affecting 9% of patients, pacemaker implantation is the most common cardiac procedure for this population.^{4,5} As epicardial leads are more prone to failure,⁶ there has been an increasing trend toward placing transvenous atrial leads within the Fontan pathway.¹ In patients with lateral tunnel Fontans, these implants have been shown to have stable atrial sensing characteristics over follow-up and lower implantation capture thresholds than epicardial leads, without significantly different rates of complications. Patients with extracardiac Fontans are more difficult to pace given the lack of paceable tissue within their Fontan circuit. To overcome this, several case studies have demonstrated the efficacy of endocardial atrial leads within the pulmonary venous atria via a puncture through the pulmonary artery into the roof of the common atrium, with no thromboembolic complications reported over short-term follow-up.^{2,3}

Within the adult population, the use of endocardial leads within a systemic ventricle is growing. Although once thought to be too risky given the possibility of thromboembolic complications,⁷ alternative pacing strategies are being

sought for heart failure patients who do not respond to more standard cardiac resynchronization strategies. Studies have described the technical feasibility of placing transvenous leads via an atrial transeptal puncture,⁸ as well as a relatively acceptable thromboembolic risk: a study by Rademakers et al⁹ noted a thromboembolic rate of 6.1 events per 100 patient-years, with all of the affected patients having subtherapeutic anticoagulation at the time of their event.

As the use of leads within the systemic circulation grows in both the adult and pediatric population, novel implants through the Fontan baffle into the systemic circulation may become more common, as this approach provides an attractive alternative to high-risk epicardial interventions. The risk–benefit balance of this approach will likely not be favorable for most pediatric patients with single-ventricle physiology; however, for a limited subset, the benefit afforded by avoiding an additional sternotomy may outweigh the potential thromboembolic risk.

References

1. Takahashi K, Cecchin F, Fortescue E, Berul CI, Alexander ME, Walsh EP, Fynn-Thompson F, Triedman JK. Permanent atrial pacing lead implant route after Fontan operation. *Pacing Clin Electrophysiol* 2009;32:779–785.
2. Arif S, Clift PF, De Giovanni JV. Permanent trans-venous pacing in an extracardiac Fontan circulation. *Europace* 2016;18:304–307.
3. Moore JP, Shannon KM. Transpulmonary atrial pacing: an approach to transvenous pacemaker implantation after extracardiac conduit Fontan surgery. *J Cardiovasc Electrophysiol* 2014;25:1028–1031.
4. Fishberger SB, Wernovsky G, Gentles TL, Gamble WJ, Gauvreau K, Burnett J, Mayer JE, Walsh EP. Long-term outcome in patients with pacemakers following the Fontan operation. *Am J Cardiol* 1996;77:887–889.
5. Petko M, Myung RJ, Wernovsky G, Cohen MI, Ryckik J, Nicolson SC, Gaynor JW, Spray TL. Surgical reinterventions following the Fontan procedure. *Eur J Cardiothorac Surg* 2003;24:255–259.

6. Fortescue EB, Berul CI, Cecchin F, Walsh EP, Triedman JK, Alexander ME. Patient, procedural, and hardware factors associated with pacemaker lead failures in pediatrics and congenital heart disease. *Heart Rhythm* 2004;1:150–159.
7. Mihalcz A, Kassai I, Geller L, Szili-Torok T. Alternative techniques for left ventricular pacing in cardiac resynchronization therapy. *Pacing Clin Electrophysiol* 2014;37:255–261.
8. Bordachar P, Ploux S, Lumens J. Endocardial pacing: the wave of the future? *Curr Cardiol Rep* 2012;14:547–551.
9. Rademakers LM, van Gelder BM, Scheffer MG, Bracke FA. Mid-term follow up of thromboembolic complications in left ventricular endocardial cardiac resynchronization therapy. *Heart Rhythm* 2014;11:609–613.