



# Persistent sinus node suppression caused by thrombotic occlusion of an arteriovenous fistula: A report of two cases

## Citation

Huang, Henry D., Jonathan W. Waks, Mark E. Josephson, and Peter Zimetbaum. 2015. "Persistent sinus node suppression caused by thrombotic occlusion of an arteriovenous fistula: A report of two cases." *HeartRhythm Case Reports* 1 (4): 190-192. doi:10.1016/j.hrccr.2015.02.004. <http://dx.doi.org/10.1016/j.hrccr.2015.02.004>.

## Published Version

doi:10.1016/j.hrccr.2015.02.004

## Permanent link

<http://nrs.harvard.edu/urn-3:HUL.InstRepos:33029853>

## Terms of Use

This article was downloaded from Harvard University's DASH repository, and is made available under the terms and conditions applicable to Other Posted Material, as set forth at <http://nrs.harvard.edu/urn-3:HUL.InstRepos:dash.current.terms-of-use#LAA>

## Share Your Story

The Harvard community has made this article openly available. Please share how this access benefits you. [Submit a story](#).

[Accessibility](#)

# Persistent sinus node suppression caused by thrombotic occlusion of an arteriovenous fistula: A report of two cases



Henry D. Huang, MD,<sup>\*</sup> Jonathan W. Waks, MD,<sup>\*</sup> Mark E. Josephson, MD,<sup>\*</sup> Peter Zimetbaum, MD<sup>†</sup>

From the <sup>\*</sup>Harvard-Thorndike Electrophysiology Institute, Beth Israel Deaconess Medical Center, Harvard Medical School, Boston, Massachusetts, and <sup>†</sup>Cardiovascular Research Institute, Maastricht, The Netherlands.

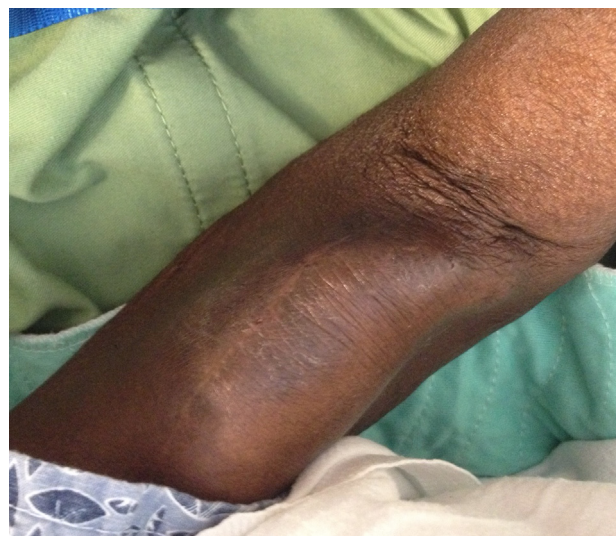## Introduction

The Nicoladoni-Israel-Branham (Branham) sign is an eponym given to the observation that acute compression of an arteriovenous (AV) fistula results in transient slowing of heart rate owing to alterations in baroreceptor activity and autonomic tone. In this report, we describe 2 cases of persistent severe sinus dysfunction attributed to thrombotic occlusion of an AV fistula used for hemodialysis (HD) access.

## Case 1

A 73-year-old African American woman with a history of hypertension, non-insulin-dependent diabetes, coronary artery disease, and end-stage renal disease (ESRD) on HD through a left upper extremity AV fistula placed 2 years prior was in her usual state of health until developing syncope at home preceded by dizziness, nausea, and chest pressure. Upon regaining consciousness, she remained nauseated but was able to later travel to her dialysis center, where HD could not be performed owing to dysfunction of her AV fistula. She was sent to the Emergency Department and was subsequently admitted to the Medicine service for suspected AV fistula occlusion, given that her AV fistula site was engorged and noncompressible (Figure 1) and no bruit could be auscultated. Her blood pressure was 150/84 mm Hg, heart rate was 62 bpm, and cardiac and pulmonary examinations were unremarkable. Her serum potassium was 5.5 mEq/L (close to her pre-HD baseline).

The patient was given her home dose of carvedilol and shortly thereafter developed bradycardia with a heart rate of 28 bpm and transient hypotension with a systolic blood pressure of 68/32 mm Hg. Electrocardiogram revealed a junctional rhythm. Intravenous atropine was administered with transient improvement in heart rate (Figure 2A). The



**Figure 1** Picture of arteriovenous fistula site following thrombotic occlusion for patient in case 1.

patient remained in a junctional rhythm with periods of sinus bradycardia followed by sinus pauses lasting up to 4 seconds. Angiography revealed total occlusion of her AV fistula, and balloon angioplasty was successfully performed (Figure 3).

After patency of the AV fistula was restored, the patient's resting heart rate in sinus rhythm improved to 70–90 bpm and no further sinus pauses were observed. Prior to discharge carvedilol was restarted without further evidence of bradycardia on follow-up.

## Case 2

An 86-year-old white woman with non-insulin-dependent diabetes, hypertension, and ESRD on HD was admitted to the Medicine service following a failed attempt at outpatient HD through her brachial-brachial AV fistula, placed 12 months prior to presentation. On telemetry she had sinus bradycardia with intermittent episodes of junctional bradycardia and a heart rate as low as 30 bpm. Her hospital and prior home medications did not include any AV nodal blocking agents. The following day, the patient was found unresponsive while eating lunch. Telemetry revealed that she

**KEYWORDS** AV fistula; Thrombosis; Bradycardia; Syncope; Hemodialysis; Sinus pause

**ABBREVIATIONS** AV = arteriovenous; ESRD = end-stage renal disease; HD = hemodialysis (Heart Rhythm Case Reports 2015;1:190–192)

**Address reprint requests and correspondence:** Dr Henry D. Huang, Beth Israel Deaconess Medical Center, 185 Pilgrim Road, Baker 4, Boston, MA 02215. E-mail address: hduang@bidmc.harvard.edu.

## KEY TEACHING POINTS

- Persistent sinus node suppression is a possible complication of thrombotic occlusion of arteriovenous fistulas used for hemodialysis.
- Administering intravenous atropine or performing maneuvers that increase venous return may transiently reverse bradycardia.
- If there is no prior history of symptomatic bradycardia, placement of permanent pacemakers should be avoided, as sinus node dysfunction resolves once patency of the arteriovenous fistula is restored.

had been in a persistent junctional rhythm with an HR as low as 20 bpm (Figure 2B). After regaining consciousness, she complained of feeling tired and weak for approximately 5 minutes, though her HR was between 50 and 57 bpm. Her serum potassium, checked immediately after the syncopal event, was 4.3 mEq/L. She continued to have sinus bradycardia with intermittent episodes of symptomatic sinus arrest lasting up to 5 seconds. On physical examination her cardiac examination was unremarkable but inspection of her AV fistula site revealed absence of the expected thrill and bruit. Administration of intravenous atropine was not attempted to reverse the patient's bradycardia.

Upper extremity angiography demonstrated complete occlusion of her AV fistula, and balloon angioplasty and stenting was successfully performed. After AV fistula patency was restored she remained in sinus rhythm without further sinus pauses. Follow-up ambulatory Holter monitoring after discharge did not reveal any episodes of sinus pauses or heart block, and the patient had no further episodes of presyncope or syncope.

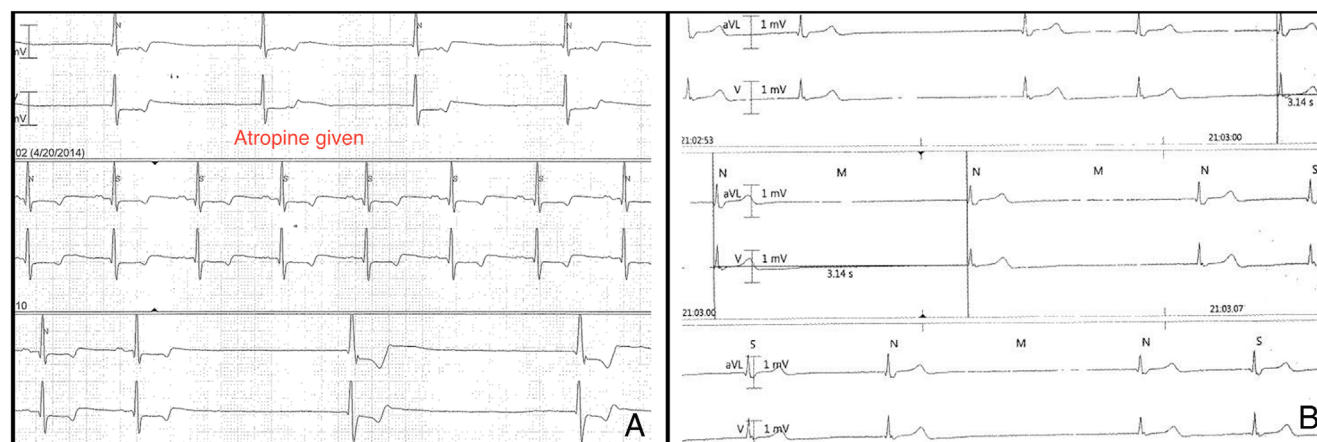
## Discussion

The Nicoladoni-Israel-Branham (Branham) sign, first described in 1890 in gunshot wound victims,<sup>1</sup> refers to an acute and transient decrease in heart rate following manual, proximal occlusion of an AV fistula. In World Wars I and II, the Branham sign was used by vascular surgeons to assist in the diagnosis of traumatic AV fistulas in wounded soldiers. Vagal involvement was demonstrated by blunting the expected decrease in heart rate with administration of atropine sulfate preceding compression of AV fistulas in a cohort of patients.<sup>2</sup>

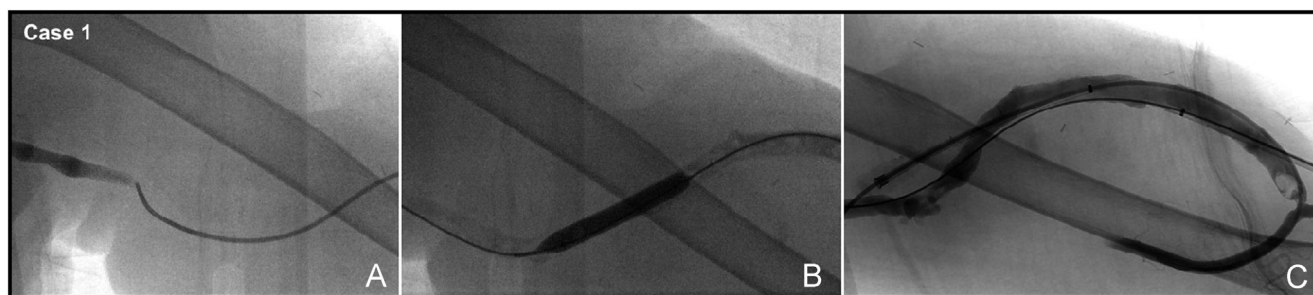
The mechanism behind bradycardia associated with Branham sign is likely similar to the reflex arc that occurs during the Bezold-Jarisch reflex. Presence of an AV fistula results in increased cardiac output because of low resistance across the AV shunt. Occlusion of an AV fistula leads to an increase in arterial impedance and decreased effective cardiac output as blood flow is redirected through the higher-resistance peripheral vasculature. A compensatory increase in cardiac contractility paradoxically activates baroreceptors and increases vagal tone.<sup>3,4</sup> Thus, obliteration of an AV fistula results in a physiologic, bradycardic response.

In small physiologic studies, acute occlusion of stable AV fistulas used for HD increased baroreceptor sensitivity to a greater degree than did carotid sinus massage.<sup>5</sup> Further vagal-mediated bradycardia from AV fistula occlusion may also be mitigated with atropine<sup>3</sup> or possibly with increased venous return achieved by lifting the lower extremities when the subject is in a supine position.

The 2 cases described in this report are somewhat atypical because Branham sign, as classically defined, describes transient bradycardia with acute occlusion of an AV fistula, yet the patients described above each had persistent bradycardia and sinus node suppression until AV fistula patency was restored days later. In the cases presented it was unknown whether occlusion of the AV fistulas were truly



**Figure 2** A: The bradycardia for the patient in case 1 is secondary to sinus node dysfunction. Following administration of 1 mg intravenous atropine there is transient return of sinus rhythm before reversion back to junctional rhythm. B: Slow junctional rhythm at time of syncope in case 2.



**Figure 3** Case 1: Balloon angioplasty performed (A and B), restoring patency of the patient's occluded arteriovenous fistula (C).

acute or developed gradually, but this distinction could be important. While the incidence of this phenomenon is unknown, symptomatic bradycardia in the ESRD population is not as uncommon as previously thought and appears to be the only arrhythmia unrelated to time from last hemodialysis session.<sup>6</sup>

Clearly, the clinical recognition of this phenomenon would be advantageous, as unnecessary placement of a permanent pacemaker and its accompanying hazards (ie, bleeding, infection, vascular complications, pneumothorax) in this high-risk population<sup>7</sup> would be avoided. Furthermore, placement of permanent pacemaker systems may be especially difficult in patients with ESRD, as vascular access is oftentimes limited because of a history of chronic venous occlusion and the desire to avoid use of venous structures ipsilateral to the AV fistulas.

## Conclusion

Persistent sinus node suppression is an under-recognized complication of thrombotic occlusion of arteriovenous fistulas used for hemodialysis, a relatively commonly encountered condition. In this situation, placement of a

permanent pacemaker in a patient without prior history of symptomatic bradycardia should be avoided, as sinus node dysfunction is reversible once patency of the arteriovenous fistula is restored.

## References

1. Branham H. Aneurysmal varix of the femoral artery and vein following a gunshot wound. *Internat J Surg* 1890;250.
2. Milton LK, Kahn JW. Effect of atropine on the Branham sign in arteriovenous fistula. *Arch Intern Med* 1946;78(1):28–30.
3. Mark AL. The Bezold-Jarisch reflex revisited: clinical implications of inhibitory reflexes originating in the heart. *J Am Coll Cardiol* 1983;1:90–102.
4. Wattanasirichaigoon S, Pomposelli FB. Branham's sign is an exaggerated Bezold-Jarisch reflex of arteriovenous fistula. *J Vasc Surg* 1997;26(1):171–172.
5. Velez-Roa S, Neubauer J, Wissing M, Porta A, Somers VK, Unger P, van de Borne P. Acute arterio-venous fistula occlusion decreases sympathetic activity and improves baroreflex control in kidney transplanted patients. *Nephrol Dial Transplant* 2004;19(6):1606–1612.
6. Charytan DM, Koplan BA, Podoll AS, Redd V, Roy-Chaudhury P, Chandra S, Tunlin JA, Williamson DE. Greater frequency of clinically significant bradycardia than ventricular tachycardia in hemodialysis patients: preliminary results of the Monitoring in Dialysis (MiD) study. Abstract presented at: American Society of Nephrology Meeting; 2014; Philadelphia, Pennsylvania.
7. Tompkins C, McLean R, Cheng A, Brinker JA, Marine JE, Nazarian S, Spragg DD, Sinha S, Halperin H, Tomaselli GF, Gerger RD, Calkins H, Henrikson CA. End-stage renal disease predicts complications in pacemaker and ICD implants. *J Cardiovasc Electrophysiol* 2011;22(10):1099–1104.