White matter tractography for neurosurgical planning: A topography-based review of the current state of the art

NeuroImage: Clinical 15 (2017) 659–672

Contents lists available at ScienceDirect

NeuroImage: Clinical

journal homepage: www.elsevier.com/locate/ynicl

White matter tractography for neurosurgical planning: A topography-based review of the current state of the art

Walid I. Essayed[a,b,*], Fan Zhang[a], Prashin Unadkat[a], G. Rees Cosgrove[a,b], Alexandra J. Golby[a,b], Lauren J. O'Donnell[a,**]

[a] Brigham and Women's Hospital and Harvard Medical School, Boston, MA, USA
[b] Department of Neurosurgery, Brigham and Women's Hospital and Harvard Medical School, Boston, MA, USA

ARTICLE INFO

Keywords:
Neurosurgical planning
Review
Tractography
White matter

ABSTRACT

We perform a review of the literature in the field of white matter tractography for neurosurgical planning, focusing on those works where tractography was correlated with clinical information such as patient outcome, clinical functional testing, or electro-cortical stimulation. We organize the review by anatomical location in the brain and by surgical procedure, including both supratentorial and infratentorial pathologies, and excluding spinal cord applications. Where possible, we discuss implications of tractography for clinical care, as well as clinically relevant technical considerations regarding the tractography methods.

We find that tractography is a valuable tool in variable situations in modern neurosurgery. Our survey of recent reports demonstrates multiple potentially successful applications of white matter tractography in neurosurgery, with progress towards overcoming clinical challenges of standardization and interpretation.

1. Introduction

The visualization of the brain's white matter pathways via diffusion magnetic resonance imaging is receiving increasing attention for neurosurgical planning, as these methods can allow preoperative, three-dimensional, non-invasive, in vivo demonstration of the location and trajectory of white matter tracts. White matter tractography (WMT), as a way for spatially analyzing the brain's white matter, can guide surgical planning in different settings, not only directly when important white matter tracts are involved in the vicinity of the resection cavity of a superficial lesion, but also indirectly when targeting a deeply located lesion or functional structure through probable eloquent white matter. However, validity and reliability issues are hindering tractography's widespread implementation. Consequently, the challenge facing precursor “tractography teams” is demonstrating the real clinical value of tractography in a clinical and surgical setting. For a clearer overview of the current state of the art techniques and clinical impact of modern tractography, we propose to critically review existing studies of tractography methods for neurosurgical planning. A high variability of anatomical, technical, and surgical particularities is faced when summarizing the ever-increasing array of challenging conditions to which modern tractography can be applied.

In this review, we propose to classify the cited reports as supratentorial or infratentorial pathologies (Fig. 1). Supratentorial pathologies will be subdivided into neoplastic, vascular, or functional indications, while reports involving infratentorial pathologies will be grouped according to their anatomical location: brainstem, cerebellum, and cranial nerves (Fig. 1). This review process is not exhaustive and will focus on reports analyzing WMT for surgical planning. For each pathology or location, we report the most recent pertinent publications examining the relevant key tracts.

As reproducibility and standardization across the different methods and teams are of high interest in the field of WMT, we report and discuss the different technical challenges described in the cited reports. By providing a longitudinal locations and pathologies based view of new published research, this review is aimed at clinicians, technical researchers generally interested in tractography, and investigators with interest in a specific disease.

2. General technical considerations

It is useful to have some familiarity with the techniques available for performing WMT, both to better appreciate the contents of this review and to assess the potential utility of future advances. We note that

Abbreviations: DBS, Deep brain stimulation; DES, Direct electrical stimulation; DTT, Direct tract targeting; FA, Fractional anisotropy; FN, Facial nerve; WMT, White matter tractography

* Correspondence to: W. I. Essayed, Brigham and Women's Hospital, Department of Neurosurgery, 75 Francis street, Boston, MA 02215, USA.
** Correspondence to: L. J. O'Donnell, Harvard Medical School, 1249 Boylston St., Room #210, Boston, MA 02215, USA.
E-mail addresses: wibnessayed@bwh.harvard.edu (W.I. Essayed), odonnell@bwh.harvard.edu (L.J. O'Donnell).

http://dx.doi.org/10.1016/j.nicl.2017.06.011
Received 24 January 2017; Received in revised form 17 April 2017; Accepted 8 June 2017
Available online 15 June 2017

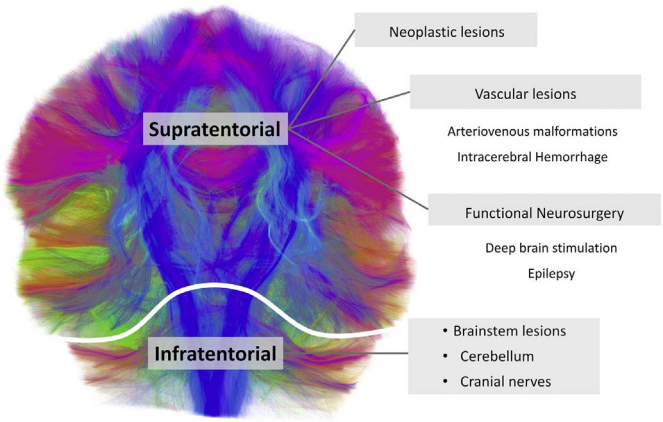

Fig. 1. Illustration of the anatomical subdivision structuring this report.

mathematical modeling of the white matter fibers from diffusion MRI data, development of WMT methods, and testing and validation of these methods are still open areas of research (Pujol et al., 2015). Several in-depth review articles are available (Assaf and Pasternak, 2008; Jones et al., 2013; O'Donnell and Westin, 2011), including recent neurosurgery-specific reviews and commentaries (Bi and Chiocca, 2014; Nimsky et al., 2016a), so here we present a brief overview of the most relevant considerations, which include data acquisition, fiber modeling, fiber reconstruction, and expert interpretation including choices of seed regions and stopping thresholds.

The most important parameters during the data acquisition are the number of gradient directions and the b-value. The number of gradient directions is the number of magnetic field gradients used to encode diffusion-weighted images, and the b-value is a factor representing the amount of diffusion weighting, which relates to the strength and timing of the gradients (Hagmann et al., 2006). The most common and widely used diffusion model, diffusion tensor imaging (DTI) (Basser et al., 1994), typically employs 30 or fewer gradient directions at a b-value near 1000 s/mm^2. Larger numbers of gradient directions and higher or multiple b-values can increase angular resolution and provide information about multiple diffusion compartments to improve the accuracy of fiber tracking estimation (Alexander et al., 2007; Jones, 2004). The field of diffusion imaging is rapidly evolving. Current advanced acquisitions may include high angular resolution (HARDI) (Tuch et al., 2002), which generally has a higher number of gradient directions than DTI and may have b-values over 1000, diffusion spectrum imaging (DSI) (Wedeen et al., 2008), which uses multiple b-values up to 7000 s/mm^2 or higher to sample q-space in a grid fashion, and multi-shell acquisitions that acquire multiple b-values (sampling spherical shells in q-space). Another consideration during acquisition is the possible presence of spatial distortions in the echo-planar imaging (EPI) diffusion MRI scan on the order of 2 mm (Treiber et al., 2016), which can affect WMT (Jones and Cercignani, 2010). Regions near air-bone interfaces, such as the orbitofrontal cortex, temporal poles, and brain stem, were the regions most affected by DWI distortion in a recent study of 250 brain tumor patients (Treiber et al., 2016). Advanced acquisitions using phase encoding gradients of opposite polarity are designed to address this but are not yet widely used clinically (Irfanoglu et al., 2015; Van Essen et al., 2013).

Another technical consideration is the type of mathematical modeling used for fiber reconstruction. DTI enables single-fiber reconstruction, which accounts for one fiber tract per voxel, an anatomically implausible scenario (Duffau, 2014; Jeurissen et al., 2013; Nimsky, 2014). In contrast, multi-fiber reconstruction can enable tracking though crossing fiber regions. Multi-fiber models, such as q-ball (Fernandez-Miranda et al., 2012; Tuch, 2004) (also called high-definition fiber tractography (Fernandez-Miranda et al., 2012)), constrained spherical deconvolution (CSD) (Descoteaux et al., 2009; Farquharson et al., 2013; Mormina et al., 2015; Smith et al., 2013; Tournier et al., 2011), and multi-tensor models (Chen et al., 2015; Chen et al., 2016a; Malcolm et al., 2010), can be beneficial for neurosurgical planning with the potential of an accurate reconstruction of white matter fiber tracts. Note that the more complex models have MRI acquisition requirements, and it is important to use a model that is appropriate for the available data (Ning et al., 2015).

The next technical concern is the choice of a method to compute the tractography. While multiple computational tracking methods are available, the most popular can be categorized as either deterministic or probabilistic. Both methods can start from a point in the brain and trace connections. However, in general, deterministic methods generate a single fiber connection from the start point (Basser et al., 2000), while probabilistic methods aim to detect many possible connections from the start point (Behrens et al., 2007). Often, deterministic methods are visualized as curved lines (streamlines), while probabilistic methods may output a map of connection probabilities. New research in tractography, including microstructure-informed (Daducci et al., 2016), global (Mangin et al., 2013), and machine learning tractography (Neher et al., 2015), has promise for the future.

A final important consideration is the expert processing and interpretation of tractography. Many choices must be made at this step, including tract seeding, tract selection, stopping thresholds, and final interpretation of results. These choices have a large effect on the final tractography output.

Tract seeding (initiation of tractography) and selection (choosing fibers from already-created tractography data) have been studied extensively. For deterministic tractography, it has long been known that the most robust, reproducible seeding method is the “brute-force” or “holistic” approach that seeds tractography in the entire brain and then employs multiple expert regions of interest (ROIs) to select tractography (Huang et al., 2004; Wakana et al., 2007). However, whole-brain seeding may not always be practical clinically, and therefore smaller seeding ROIs or fast interactive seeding may be useful (Chamberland et al., 2014; Golby et al., 2011). Of note is the fact that an optimal seeding region will depend not only on the neuroanatomy, but also on the tractography method. For example in the corticospinal tract of patients with brain tumors, deterministic methods are generally best seeded in a large region of white matter and not in the cortex where diffusion anisotropy is low (Radmanesh et al., 2015), while probabilistic methods are often seeded many times within specific regions in the brainstem and cortex (Farquharson et al., 2013; Niu et al., 2016). Many studies have provided guidelines for ROI placement or anatomical atlas usage to define fiber tracts (Catani and Thiebaut de Schotten, 2008; Lawes et al., 2008; Wakana et al., 2004; Wassermann et al., 2016), though methods that rely on normal neuroanatomy may not produce sufficient results in patients with tract displacement due to mass lesions (Schonberg et al., 2006). Specifically in patients with brain tumors, several groups have investigated optimal structural and functional ROIs for tract seeding and selection of the corticospinal tract (Holodny et al., 2001a; Niu et al., 2016; Radmanesh et al., 2015; Schonberg et al., 2006; Weiss et al., 2015). However, even when the ROIs are held constant, there is known variability in tract selection across expert raters and across tractography methods (Burgel et al., 2009; Colon-Perez et al., 2016). This has led to neurosurgical planning research into standardization using automated placement of ROIs and automated identification of key tracts based on their trajectories (O'Donnell et al., 2017; Tunc et al., 2015; Zhang et al., 2008).

In addition to the seeding and selection regions, the thresholds for starting and stopping WMT are important choices. Early investigations demonstrated that lowering the fractional anisotropy (FA) threshold could enable increased tracking in edema and tumors (Akai et al., 2005; Schonberg et al., 2006). Today, each state-of-the-art multi-fiber WMT method relies on a different threshold, which is necessarily specific to the fiber model and tractography framework (e.g. fiber orientation distribution (FOD) based thresholds, apparent fiber density, generalized

anisotropy, bundle-specific thresholds, and free-water corrected thresholds) (Chamberland et al., 2014; Malcolm et al., 2010; Pasternak et al., 2009; Raffelt et al., 2012; Tournier et al., 2012). Recent research has proposed sophisticated rules for rejecting incorrectly-traced fibers according to anatomical constraints (such as a tract should end in gray matter) to reduce bias in tractography (Girard et al., 2014; Smith et al., 2012). However, these rules rely on automated brain segmentation, which is not yet robust in the presence of brain tumors.

The final expert interpretation of WMT should be performed in the complete context of the patient's structural and functional imaging and case presentation. A diffusion MRI voxel is much larger than the scale of an axon (O'Donnell and Westin, 2011), and thus any WMT reconstruction is only an informative estimate of a white matter tract, with known limitations including the following. WMT cannot directly provide functional information about the eloquence of a fiber tract (Duffau, 2014). WMT can suffer from false negatives, i.e. missed or inadequately traced fibers (especially in the case of DTI (Chung et al., 2011)), while DTI and multi-fiber models are known to suffer from false positives (Maier-Hein et al., 2016; Wakana et al., 2007). Neurosurgery-specific WMT challenges include edema and tract displacement (Jellison et al., 2004; Nimsky et al., 2016a). Due to these limitations and challenges, improving tractography is an active field of technical research.

3. Supratentorial lesions

In this section, we will review applications of WMT in supratentorial neoplastic and vascular pathologies. We also discuss the supratentorial application of tractography in functional neurosurgery, principally in epilepsy surgery and deep brain stimulation.

3.1. Neoplastic lesions

Tractography is a highly valuable technique during the planning of surgery in patients suffering from supratentorial intra-axial lesions (Nimsky et al., 2016b). Surgery is central to the management of a majority of these lesions. We will focus on glioma surgery, as a model of anatomically and functionally challenging lesions. The first objective of this surgery is to establish a histological, molecular and genetic grading of the tumor, which will guide further adjuvant therapies. The other principal goal of surgery is to safely maximize the extent of resection which has been repeatedly proved to be an independent major prognosis factor (McGirt et al., 2009; Sanai et al., 2011). The frequent absence of clear normal parenchyma/tumor interface with variable dynamic interactions between neoplastic invasiveness and brain plasticity are the major challenges in the resection of glial lesions.

Glioma management has benefited greatly from multiple refinements of the different treatment modalities. In conjunction with other modern advances (functional MRI, neuronavigation, intraoperative fluorescence guidance, intraoperative MRI), WMT-based surgery is currently recognized as a valuable tool for balancing the trade-off between function preservation and maximized resection in both high grade and low grade gliomas (Barbosa et al., 2016; Charras et al., 2015; Kekhia et al., 2011; Kuhnt et al., 2012; Wu et al., 2007). The importance of understanding the individual patient's white matter configuration during surgical planning comes from the relatively unpredictable nature of fiber/tumor interaction in the context of intra-axial tumors, particularly slowly growing low grade gliomas. Tracts can display different alterations: anatomical distortion (from mass effect), infiltration by tumor cells, edema, complete interruption, and sometimes functional reorganization (Duffau, 2005). This so-called brain plasticity should be viewed as a dynamic phenomenon that encompasses both the pre- and post-operative periods.

WMT helps evaluate the configuration of the underlying important white matter fibers (Fig. 2) (Chamberland et al., 2015; Chamberland et al., 2014; Golby et al., 2011). Sparing these tracts is essential since white matter displays relatively limited functional reorganization possibilities, when compared to the cortex (Yogarajah et al., 2010). White matter tracts also play a crucial part in local then distal functional cortical recruiting (Charras et al., 2015; van Geemen et al., 2014), which not only helps patients compensate for preoperative functional cortex damage but also aids recuperation from possible surgery-inflicted deficits. Accordingly, sparing these important connections is an important prognosis factor not only for the acute postoperative phase, but also for the long term functional surgical outcome. We will review current reports comparing WMT to direct electrical stimulation, before discussing the recent literature assessing the impact of WMT on the extent of resection and functional outcome. We then consider lesions in the language areas in a separate subchapter given the specific challenges facing surgery in these locations.

3.1.1. WMT vs direct electrical stimulation

Direct electrical stimulation (DES) is considered by many to be the gold standard for intraoperative identification of eloquent structures (Andrea Szelényi et al., 2010; Duffau, 2005, 2015; Kombos and Süss, 2009). Multiple authors have attempted to compare WMT to direct electrical stimulation results, with variable outcomes. Comparisons of these two methods are difficult and inherently suffer various limitations. First, the estimation of fiber location from DES is not faultless and can be subject to a high variability, particularly when using bipolar stimulation. Even though slightly less precise than bipolar, monopolar subcortical stimulation is gaining popularity since it allows a more objective analysis of the results (Kombos and Süss, 2009; Szelenyi et al., 2010). Brain shift and particularly white matter tract shift in the vicinity of the resection cavity can represent a major limitation when comparing intraoperatively registered stimulation points to tracts reconstructed on pre- or post-operative images (Nimsky et al., 2005). Even though multiple indirect methods have been proposed to limit brain shift associated errors (ultrasounds, stereovision, etc. (Fan et al., 2016; Gerard and Collins, 2015; Prada et al., 2014; Sun et al., 2005)), the best currently available solution for WMT comparisons to DES is the direct use of data from intra-operative MRI. We summarize the existing literature in Table 1. These reports support a high linear correlation between distances to reconstructed tracts and positive DES intensities (Javadi et al., 2017; Maesawa et al., 2010; Ostry et al., 2013) or post-operative deficits (Prabhu et al., 2011). In addition to intra-operative morphological data, DTI sequences can be relatively quick to acquire and could be obtained intra-operatively in operating rooms with intra-operative MRI capability. Intra-operative WMT has been shown to be able to detect the variable possible shift patterns of major tracts (Nimsky et al., 2005), with a better correlation to the intraoperative DES (Maesawa et al., 2010). Interestingly, it is able in some cases to identify fibers that went undetected on the preoperative tractography, as reported by Javadi et al. in a series of twenty patients, where CST fibers where unidentifiable on preoperative WMT in three patients, then subsequently successfully trackable on intraoperative scans (Javadi et al., 2017). This is conceivably associated with local changes after tumor removal (Javadi et al., 2017).

3.1.2. WMT versus extent of resection and post-operative functional outcome

As the methods and techniques of WMT continue to evolve, more robust and reproducible fiber tracking is helping to increase the extent and safety of tumor resections (Abdullah et al., 2013; Castellano et al., 2012; Caverzasi et al., 2016; Chen et al., 2016b; Pujol et al., 2015). Advantages of using WMT, in conjunction with other modern standards of care (f-MRI, neuronavigation, DES, intraoperative MRI, etc.), are clear with significant correlation to an increased extent of resection (Barbosa et al., 2016; Nimsky et al., 2006; O'Donnell et al., 2012). WMT is the only preoperative noninvasive tool for studying white matter tracts, which is advantageous for risk stratification, patient counseling, and surgical planning (Berman, 2009; Farshidfar et al., 2014; Romano

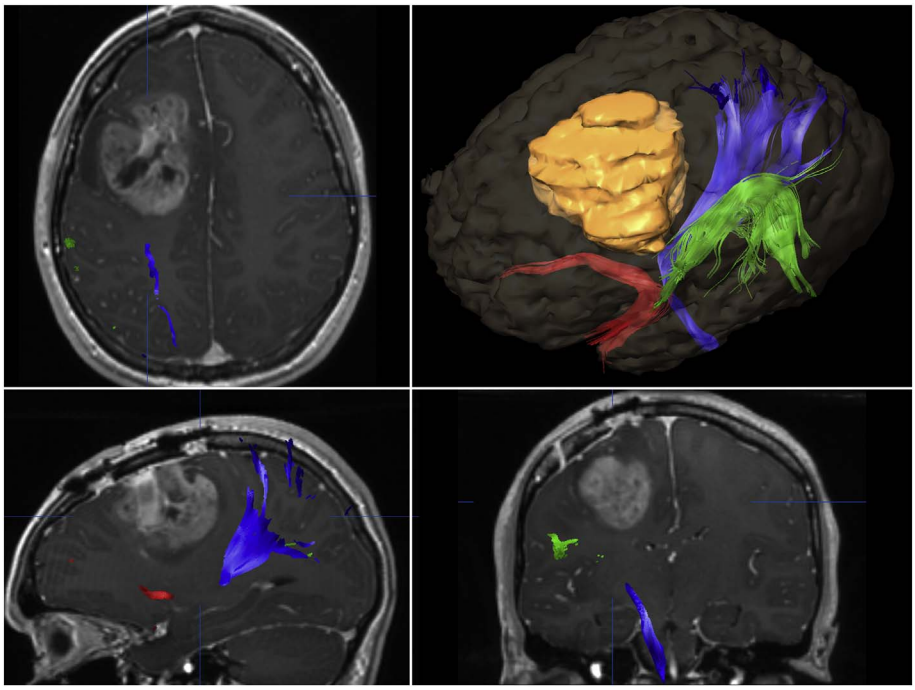

Fig. 2. Pre-surgical plan of right handed 18 y.o. patient presenting with left frontal glioblastoma. White matter tractography allowed to assess the relationships between the tumor (orange) and eloquent tracts (green: arcuate fasciculus, red: uncinate fasciculus, blue: corticospinal tract). These results are valuable for planning the safest surgical route and resection. (For interpretation of the references to color in this figure legend, the reader is referred to the web version of this article.)

et al., 2009; Rosenstock et al., 2017). Understanding the spatial configuration of the white matter helps finding the safest corridor particularly in deeply situated lesions (Farshidfar et al., 2014; Spena et al., 2015; Tunc et al., 2015). For instance, Barbosa et al. reported a statistically significant improvement of the post-operative Karnofsky Performance Scale by the implementation of WMT during the resection of insular gliomas (Barbosa et al., 2016). When combined with neuronavigation, WMT offers an intraoperative approximation of major tract positions, decreasing the number of subcortical stimulations needed, making surgery quicker and easier, particularly for awake patients (Bello et al., 2008). Reduced DES decreases also the risk of stimulation-induced seizures. In patients with tumors involving language areas, if awake surgery is impossible or unavailable, WMT constitutes the only available solution for assessing and trying to spare involved white matter tracts (D'Andrea et al., 2016). It is also important to have tractography data available in the unfortunate cases where stimulation-induced seizures and patient fatigue prevent further language monitoring during awake surgery.

3.1.3. WMT and language area surgery

Fiber tracking and modeling was first applied to the cortico-spinal tracts with improving robustness (Chen et al., 2016b; Ciccarelli et al., 2003; Coenen et al., 2001; Holodny et al., 2001b; Itoh et al., 2006; Qazi et al., 2009; Talos et al., 2003). Progressively, with the improvement of imaging and processing techniques, tracking of smaller and more complex structures has become possible. The application of these new advances to the mapping of white matter tracts involved in cognitive and specifically language function is a major challenge, given the relative subjectivity and complexity of the involved structures (Chang et al., 2015; Yagmurlu et al., 2016). We focus here on reports correlating pre- and post-operative tractography to language function. Caverzasi et al. reported, in a series of 35 patients, that preservation of the tracked left arcuate fasciculus (AF) and the temporo-parietal component of the superior longitudinal fasciculus (SLF-tp) was statistically correlated to the absence of postoperative language deficit (Caverzasi et al., 2016). Damage to these two pathways also was statistically predictive of a long-term language deficit (Caverzasi et al., 2016). In another series of 27 patients presenting with a high grade glioma that involved the dominant angular gyrus, supramarginal gyrus, and/or the inferior parietal sulcus, D'Andrea et al. attained satisfactory resection (77% of complete resection) while conserving or improving the preoperative neurologic status in 85% of the cases, demonstrating that in wisely selected cases, WMT based surgical planning can represent a safe alternative to awake surgery (D'Andrea et al., 2016).

3.1.4. Technical considerations

Regardless of the limitations of quantitative data, tractography can, when interpreted with available functional and anatomical studies, help achieve a better regional spatial understanding by providing data regarding local configuration and eventual disruptions of eloquent white matter. While many fibers can be successfully detected in the vicinity of low grade gliomas using simple tractography techniques, high grade gliomas are usually more aggressive with more local invasiveness in addition to peritumoral edema (Goebell et al., 2006). Complex methods and models such as high-definition fiber tractography (HDFT) (Abhinav et al., 2015), two-tensor unscented Kalman filter (UKF) tractography (Chen et al., 2015; Chen et al., 2016b), and constrained spherical deconvolution tractography (Lim et al., 2015), are now being developed to improve fiber tracking in these circumstances with encouraging results. However, the interpretation of the results using these advanced modeling techniques is still under evaluation. While probably decreasing the risk of false negatives, these methods may inherently lead to more false positive reconstructions (Maier-Hein et al., 2016). This could encompass anomalies stretching from making false connections between tracts to tracing tracts in areas completely devoid of fibers (Chen et al., 2015; Chen et al., 2016b). A different method would be a holistic approach by mapping all the white matter, followed by the use of specific tools to analyze regions of interest (Chen et al., 2015; O'Donnell et al., 2013). This kind of approach necessitates evidently more processing power and time, which can limit its applicability. Even if structurally accurate, the provided reconstruction might also be possibly visualizing tracks that are anatomically accurate but progressively became functionally obsolete, in the context of brain plasticity (Campbell and Pike, 2014). Preoperative cross-validation of WMT with other techniques (functional MRI, transcranial magnetic stimulation) might be helpful in identifying those instances (Lemaire et al., 2013; Weiss et al., 2015; Weiss Lucas et al., 2017).

Table 1
Summary of reports using intraoperative MRI in comparing DTI white matter tractography with DES.

Authors	Year	# pts	DTI			DES		Results
			Acquisition	Tracking method	iDTI possible	Stimulation	Positive DES	
Javadi et al.	2016	20	b = 1000; Dir = 12	Deterministic (FACT[a], in iPlan v.3.0 BrainLab)	20 (100%)	Bipolar (12 pts); monopolar (8 pts)	17 (85%)	Statistically significant linear correlation between the intensity of stimulation and the distance from the CST The sensitivity, PPV, and NPV of DTI tractography to localize the CST were 100%, 78%, and 100%, respectively
Maesawa et al.	2010	28	b = 1000; Dir = 12	Deterministic (FACT, in iPlan v.2.6 BrainLab)	28 (100%)	Bipolar	27 (96%)	Significant positive correlation between the distance from intra-CST tractography and the intensity of stimulation (P 0.01)
Ostry et al.	2013	25	b = 1000; Dir = 25	Deterministic (FACT, in iPlan v.2.6 BrainLab)	16 (64%)	Monopolar (C)	25 (100%)	Linear current-distance correlation was found both in pre-iMRI and in post-iMRI data
Prabhu et al.	2011	12	b = 750; Dir = 20	Deterministic (FACT, in iPlan v.2.6 BrainLab)	12 (100%)	Monopolar (A)	10 (83%)	Trend towards linear increase of neurological deficits when the distance from the probe to the reconstructed CST was short (< 5 mm)

pts: total number of patients; (A): anode; (C): cathode; CST: corticospinal tract; iMRI: intraoperative MRI; PPV: positive predictive value; NPV: negative predictive value.
[a] FACT: fiber assignments derived by continuous tracking.

3.2. Vascular lesions

Natural history, perilesional modifications, surgery goals, and treatment options of vascular lesions are different from those encountered in neoplastic lesions. Globally, vascular lesions are benign and noninvasive. These lesions threaten the functional and vital prognosis principally through hemorrhagic, ischemic and sometimes epileptogenic mechanisms. For lesions, such as arteriovenous malformations and cavernomas, the surgical goal is total resection to prevent future bleedings. When successful, surgery is curative, which emphasizes the importance of preserving neurologic function, particularly since surgery is often not the exclusive curative treatment option. WMT is not routinely used in aneurysm surgery since aneurysms develop most frequently on superficial large caliber vessels where white matter involvement is limited and the surgical approach is usually through the subarachnoid spaces. On the other hand, arteriovenous malformations, cavernous malformations, and spontaneous intracerebral hemorrhages can be partially or totally deeply located, which supports the usefulness of white matter identifying techniques. Here, we will mainly discuss arteriovenous venous malformations and spontaneous intracerebral hematomas (Table 2), while cavernous malformations will be discussed with brainstem lesions.

3.2.1. Arteriovenous malformations (AVM)

Multiple treatment options are now available for treating AVMs: surgery, endovascular treatment, and stereotactic radiosurgery (SRS). Each of these treatments has its own advantages and disadvantages, adding an extra layer of complexity to the decision making. Many reports are now available on the functional cortical and subcortical reorganization induced by a neighboring AVM (Alkadhi et al., 2000; Scantlebury et al., 2014; Schlosser et al., 1997; Vates et al., 2002). This remodeling redefines the classical eloquent areas by which we classically evaluate AVMs (Jiao et al., 2016). Understanding the spatial configuration of the underlying white matter tract can have a significant impact on the prognosis evaluation (Kikuta et al., 2008). Accordingly, proximity of an eloquent white matter tract has been associated with a decline of the long term functional treatment outcome (Jiao et al., 2016). Surgery in AVMs cannot afford to be subtotal, as might be the case in other eloquent brain lesions, since incomplete resection increases potential bleeding risk and morbidity. Neighboring tract evaluation helps in deciding if surgery is the safest treatment option for a specific lesion. When resection is decided upon, WMT helps to demonstrate nearby tracts in superficial lesions and the safest corridor avoiding eloquent fibers in deeper lesions (Ellis et al., 2012; Itoh et al., 2006; Jiao et al., 2016; Okada et al., 2007). Tractography results might favor alternative treatment options when the spatial tract configuration is functionally unsafe for surgery. One of the other treatment options of AVM is SRS. Current evidence suggests that the integration of WMT in the SRS treatment planning significantly decreases post treatment adverse effects (Koga et al., 2012; Pantelis et al., 2010).

3.2.2. Intracerebral hemorrhage ICH

The role of surgical evacuation is still unclear during the management of spontaneous intracerebral hemorrhages. Most of the controversy is associated with the high morbidity inherent to approaching deeply located hematomas. WMT can help identify the eloquent white matter tract around the clot and help to plan the safest approach corridor (Labib et al., 2016). Several authors have shared their experience with the systematic use of tractography for surgical planning of deep spontaneous intracerebral hematomas with encouraging results (Labib et al., 2016; Ritsma et al., 2014). Multicentric randomized prospective trials are currently being directed to validate these preliminary reports (Labib et al., 2016). WMT can also be a useful tool for monitoring the damages and recovery of eloquent white matter tracts during the subacute phase of the hemorrhage, giving some long-term functional prognosis information (Jang et al., 2016; Kumar et al., 2016).

Table 2
Summary of the reviewed reports using WMT for surgical planning for arteriovenous malformations and spontaneous intracranial hematomas.

AVM	Authors	Year	# pts	DTI			Results/techniques
				Acquisition	Tracking method	Tract of interest	
Surgery	Ellis et al.	2012	3	N/A	Deterministic (FACT, in iPlan, BrainLab)	CST	Feasibility of CST mapping in children with ruptured AVMs using MEG fMRI guided DTI tractography.
	Itoh et al.	2006	24	b = 1000; Dir = 13	Deterministic (in Volume-one and dTV v.II)	CST	In the patients with hemiparesis, DTT-CSTs were involved in the AVM or its surrounding lesion and their volumes at the affected side was significantly decreased compared to the contralateral side; in the patients whose DTT-CSTs were free from lesion had no hemiparesis.
	Jiao et al.	2016	41	b = n/a; Dir = 30	Deterministic (FACT, in iPlan v.3.0, BrainLab)	AF; Optic radiation	TOJ-AVMs patients have a high risk of surgical morbidity, although they often have relatively low Spetzler–Martin scores; LFD is a crucial risk factor associated with postoperative neurological deficits of patients with TOJ-AVMs.
	Okada et al.	2007	34	b = 700; Dir = 40	Deterministic (FACT, in DTIStudio v2.02)	CST; optic radiation	In patients with both hemorrhagic and nonhemorrhagic AVM, the 2 fiber tracts close to the nidus were less visualized in the affected hemisphere than those distant from the nidus. Tracts were less visualized in patients with neurologic symptoms than in asymptomatic patients.
SRS	Koga et al.	2012	144	b = 1000; Dir = 13	Deterministic (in Volume-one v.1.72 and dTV v.II)	CST; optic radiation; AF	Integrating tractography helped prevent morbidity of radiosurgery in patients with brain arteriovenous malformations.
	Pantellis et al.	2010	4	b = 1000; Dir = 18	Deterministic (fourth-order Runge-Kutta method on 3 T MAGNETOM Trio scanner (Siemens))	Tracts situated near brain stem, optic chiasm, and optic nerves	Functional structures and fiber tracts could receive high doses if they were not considered during treatment planning. With the aid of fMRI and tractography images, they can be delineated and spared.
ICH	Labib et al.	2016	39	NR	NR	NR	DTI helps in identifying the white matter tracts affected by the hematoma and therefore helps patients and their families understand the potential for functional recovery and in planning the best trajectory to the hematoma while avoiding important tracts.
	Ritsma et al.	2014	1	NR	NR	AF	Successful application of the Mi SPACE model to ICH in dominant, eloquent cortex and subcortical regions. MRI tractography illustrates collateral tissue preservation.

pts: total number of patients; AF: arcuate fasciculus; AVM: arteriovenous malformation; CST: corticospinal tract; ICH: intracerebral hematoma; NR: not reported; SRS: stereotactic radiosurgery.

3.2.3. Technical considerations

Fiber tracking in AVM patients can be highly variable depending on the AVM status. Non-hemorrhagic AVMs are associated with a limited peri-nidal disruption, leading to minimal fractional anisotropy (FA) variations, only due to local microvascular changes. Otherwise, the non-infiltrating nature of these lesions preserves the normal appearing white matter in the vicinity of the AVM, preserving the reliability of WMT (Okada et al., 2007). On the other hand, after hemorrhage, peri-lesion vasogenic edema, gliosis, and other disruptions can be challenging for DTI tracking, as previously discussed for brain tumors. However, fiber tracking was shown to be still feasible and useful in some of these situations (Ellis et al., 2012; Okada et al., 2007).

3.3. Functional neurosurgery

Functional neurosurgery covers a vast array of central and peripheral nervous system pathologies. Multiple reports assessing the different possible applications of WMT in these different diseases have been recently published, mainly in epilepsy surgery and deep brain stimulation. Consequently, we focused on these two areas in this section. We discussed successively the general applications then the technical considerations in each of these fields.

3.3.1. Deep brain stimulation (DBS)

Currently, DBS represents a major therapeutic option for an ever-growing array of pathologies ranging from Parkinson's disease to resistant depression disorders. The physiological effect for brain stimulation was first thought to be only linked to a conjugation of inhibition and stimulation of local neurons. However, it has become progressively clear that the functional efficacy of chronic stimulations is not only correlated to the local micro-circuitry, but is also interconnected with a more globally integrated neural model (Gradinaru et al., 2009; Henderson, 2012; McIntyre et al., 2004).

Tractography based DBS aims to unravel the possible links entangled within normal and pathological functioning of well described targets of classic DBS. Multiple experiences and reviews have now been published on the different possible applications of WMT in the context of DBS (Calabrese, 2016; Henderson, 2012; Torres et al., 2014). In a recent exhaustive review, Calabrese et al. divided the different methodologies into two groups: retrospective tract stimulation modeling and tract proximity analysis, versus prospective direct tract targeting (DTT) (Calabrese, 2016). Retrospective methods are based on the spatial and electrophysiological study of the configuration of specific tracts in relation to electrodes in already implanted patients. These analyses can allow identification of patterns associated with successful versus unsuccessful stimulation, particularly in treating pathologies such as depression for which the neural circuitry is less well understood (Johansen-Berg et al., 2008; Lujan et al., 2012; Vanegas-Arroyave et al., 2016). Such analyses help to pinpoint precise targets associated with the most effective therapy, as demonstrated by Varnegas-Arroyave et al. in sub-thalamic nucleus stimulation for Parkinson's disease, with clinically effective contacts statistically more connected to the superior frontal gyrus (Fig. 3A,B) (Vanegas-Arroyave et al., 2016).

An explanation of some DBS associated adverse effects can be formulated using the same approach. WMT allows in some cases to visualize the anatomo-physiological link between the stimulated contact and a specific side effect. For instance, Barkhoudarian et al. reported an association between motor side effects (facial pulling, involuntary arm movement) and tracts leading to the supplementary motor area (SMA) or premotor cortex (Barkhoudarian et al., 2010).

WMT might also play a role during candidate selection for DBS. Some authors have suggested that preoperative tract patterns could help to identify cases where DBS might be less effective. For example, McNab et al. proposed that reduced amygdalar-thalamic and amygdalar-subgenual anterior cingulate cortex connections could be a contraindication to the use of DBS for resistant major depressive disorder (McNab et al., 2009).

The success of these retrospective reports has paved the way for more direct prospective approaches using DTT to preoperatively select the best targets for DBS. Currently, few direct targeting reports have been published, with promising results (Table 3) (Coenen et al., 2011; Hunsche et al., 2013; Schlaepfer et al., 2013).

So far, whether through retrospective or more direct approaches, a clear prospect of tractography as tool for improving DBS results is emerging; however, more thorough comparative evaluations are still necessary.

3.3.2. Technical considerations

Highly sensitive WMT methods, such as probabilistic or multi-fiber model WMT, might represent the methods of choice for DBS targeting, as the efficacy of a given electrical stimulation is thought to be dependent on the connection pattern of the stimulation site (Descoteaux et al., 2009; Jeurissen et al., 2013; Johansen-Berg et al., 2008; Pouratian et al., 2011). Nevertheless, the inherent complexity of most highly sensitive tractography methods limits their application. For instance, the interpretation of results is less intuitive in probabilistic methods than with deterministic ones, as the contact between a target and the DBS site is expressible only in terms of probability or strength (Pouratian et al., 2011). Accordingly, existing direct targeting reports have opted more towards the use of deterministic methods (Table 3).

3.3.3. Epilepsy

There are multiple clinical applications of tractography in epilepsy patients. By helping assess pre-surgical memory and language status, WMT provides valuable neuropsychological prognosis data that can help for counseling and then surgically treating patients (McDonald et al., 2008). White matter can display some alterations associated with epileptogenic cortical lesions as reported by Whelhan et al. who described significant alterations of the fractional anisotropy and mean diffusivity of multiple tracts in mesial temporal epilepsy patients (Whelan et al., 2015). A better evaluation of these changes as well as any concomitant functional reorganization helps explain ictal spread patterns and provides a more comprehensive view when planning for surgery, particularly in when facing multiple epileptogenic lesions (Diehl et al., 2010).

One of the major goals of epilepsy surgery is avoiding causing a neurologic deficit, particularly in already functionally challenged patients. When approaching the temporal lobe, one of the main concerns is localizing the fibers of Meyer's loop (Daga et al., 2012). The inter and intra-subject heterogeneity of the course of Meyer's loop is a key variable to consider when counseling patients and planning for surgery (Nilsson et al., 2007; Yasargil et al., 2004). WMT provides a practical complementary method to study the OR and the Meyer loop anatomy in vivo with reference to individual 3-dimensional brain anatomy (Wu et al., 2012). Multiple reports have found a statistical correlation between the degree of postoperative visual field deficit and independently reconstructed Meyer's loop tracts (Table 4) (Chen et al., 2009; Daga et al., 2012; Taoka et al., 2008; Winston et al., 2012; Yogarajah et al., 2009). Chen et al. reported a correlation between pre- and intra-operative tracking results and postoperative visual deficit in a prospective study of 48 patients (Chen et al., 2009). In another prospective study, Winston et al. reported achieving no postoperative visual field deficit when surgical indication and preplanning were based on tractography results, in a series of 5 patients. Interestingly, the authors also used tractography results to counter-indicate or delay surgery in five other patients of the same series (Winston et al., 2011). Integrating tractography data with intra-operative microscope display might also help avoid visual complications (Winston et al., 2014).

In addition to visual field deficit avoidance, functional language preservation is a key concern in patient selection and surgical planning for epilepsy surgery. Usually results of WMT of language circuits are challenging to interpret, particularly through perilesional disruptions;

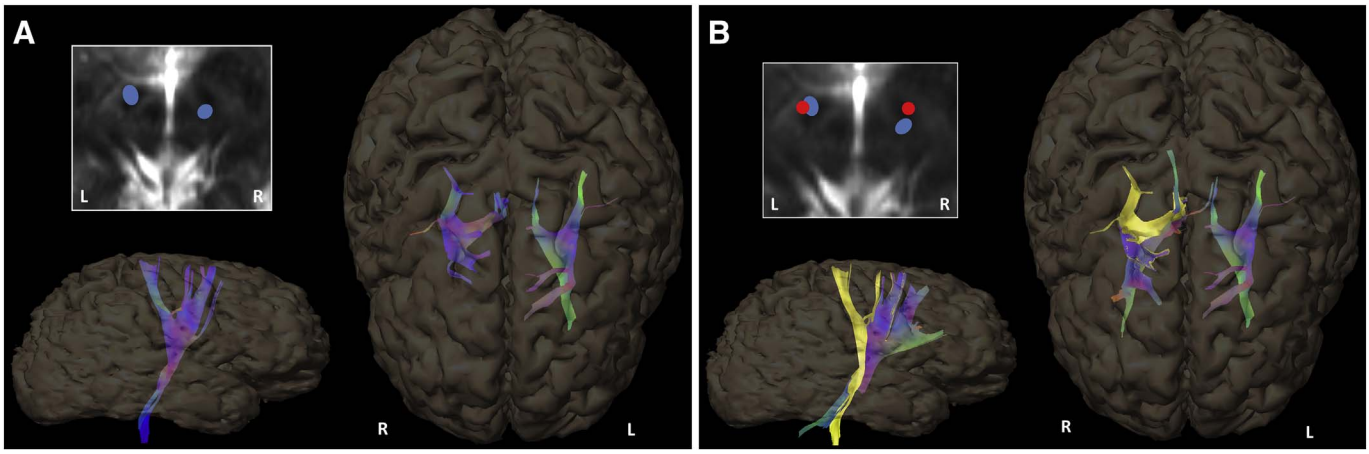

Fig. 3. Tractography efficacy patterns in a bilateral DBS of the sub thalamic nucleus in a Parkinson's disease patient.
A: Patient underwent bilateral electrode implantation; tremor control was better in the patient's right side. Post-operative imaging confirmed that the right-side electrode location was slightly posterior to the selected target (blue). The connectivity patterns obtained from stimulation sites were asymmetric with more superior frontal gyrus connectivity in the left hemisphere. B: After five years, patient underwent bilateral re-implantation; old and new stimulation sites were superimposed on the left side (blue/red). The new right side stimulation site was anterior to the old site (blue/red). Bilateral tremor control was achieved by the new surgery. New tractography patterns became more symmetrical (yellow: old tracts). (For interpretation of the references to color in this figure legend, the reader is referred to the web version of this article.)

Table 3
DBS direct targeting reports.

Author	Year	# pts	Indication	DTI			Results
				Acquisition	Tracing method	Tract of interest	
Coenen et al.	2011	1	Refractory tremor	b = 1000; Dir = 32	Deterministic (in StealthViz DTI, Medtronic)	Dentato-rubro-thalamic tract	90% improvement of the tremor
Hunsche et al.	2013	4	Thalamic pain	b = 800; Dir = 32	Deterministic (FACT)	Spinothalamocortical tract	Pain relief of > 40% was achieved in 3 of 4 patients
Schlaepfer et al.	2013	6	Resistant major depressive disorder	b = 1000; Dir = 32	Deterministic (in StealthViz DTI, Medtronic)	Supero-lateral branch of the medial forebrain bundle	6/7 response criterion

pts: total number of patients.

however, in epilepsy patients, white matter displays few abnormalities, allowing more reliable results (Anastasopoulos et al., 2014; Carlson et al., 2014). Accordingly, some evidence already suggests a functional language outcome benefit from performing tractography as part of the pre-surgical planning for epilepsy surgery (Jeong et al., 2015; Szmuda et al., 2016).

3.3.4. Technical considerations

The sharp angle of the Meyers' loop fibers, in close contiguity of multiple other white matter tracts and the CSF in the anterior tip of the temporal horn of the lateral ventricle, are major obstacles for deterministic tracking methods. These latter have been shown to consistently underestimate the most anterior extent of the fibers (Lilja et al., 2014; Piper et al., 2014; Yamamoto et al., 2007; Yamamoto et al., 2005). Though more time consuming, probabilistic methods have been increasingly used in recent related literature (Lilja et al., 2014; Piper et al., 2014). The development of new methods and techniques of acquisition and analysis such as multi-tensor imaging, q-ball, HARDI, and

Table 4
Summary of reports correlating the degree of post-operative visual field deficit to reconstructed Meyer's loop tracts.

Author	Year	# pts	DTI		Results
			Acquisition	Tracking method	
Chen et al.	2009	48	b = 1000; Dir = 6	Deterministic (FACT, in iPlan v.2.5, BrainLab)	Significant correlation between visual field loss and the degree of optic radiation injury depicted by DTI based FT
Daga et al.	2012	20	b = N/A; Dir = 52/30[a]	Probabilistic (PICo[b], in Camino)	The predicted damage to the optic radiation correlated strongly with the measured visual field deficit
Taoka et al.	2008	14	b = 1000; Dir = 6	Deterministic (in dTV v.II)	Statistically significant correlation between the degree of the visual field defect and the Meyer loop-resection distance
Winston et al.	2012	20	b = 1200; Dir = 6	Probabilistic (PICo, in Camino)	Statistically significant correlation between the degree of the visual field defect and the Meyer loop-resection distance
Yogarajah et al.	2009	21	b = 1200; Dir = 52	Probabilistic (PICo, in Camino)	Statistically significant correlation between the degree of the visual field defect and the distance from the tip of Meyer's loop to the temporal pole

pts: total number of patients.
[a] Two DMRI scans were conducted.
[b] PICo: probabilistic index of connectivity.

high order spherical harmonics, can help obtain more reproducible and robust results when reconstructing such a complex white matter region (Chamberland et al., 2017; Kammen et al., 2016; Lilja et al., 2014; Martinez-Heras et al., 2015; Nowell et al., 2016; Piper et al., 2014).

4. Infratentorial

In this section, we will review the recent literature assessing possible applications of WMT for surgical planning in infratentorial pathologies, then discuss overall technical challenges facing tractography in this region. We considered as infratentorial all lesions involving the brainstem, the cranial nerves and the cerebellum.

4.1. Brainstem lesions

Brainstem tumors are one of the most challenging neurosurgical pathologies. The dense concentration of nuclei and fibers is related to significant pre- and post-operative morbidity (Cavalcanti et al., 2016). Cranial nerve deficits are the most common presenting symptoms and are typically associated with an irritation of one or multiple white matter tracts. The safety of any surgical approach to the brainstem is dependent on avoiding major tracts running through its different levels. WMT is currently the only method available for pre-operative evaluation of these tracts. Advances in tractography methods presently allow the identification in healthy individuals, not only of the major tracts, but also smaller structures such as the medial longitudinal fasciculus, the rubrospinal tract, and the spinothalamic tract (Meola et al., 2016). In a clinical context, robust evaluation of the major tracts is the principal goal. DTI tractography was shown to be able to identify CST invasion as well as early extra-pontine tumor extension in diffuse brainstem gliomas, before it becomes apparent on standard MRI sequences (Wagner et al., 2016). In a series of 14 patients, Kovanlikaya et al. reported that all the patients with normal reconstructed tracts had conserved preoperative motor function, reflecting a 100% negative predictive value of WMT at this level (Kovanlikaya et al., 2011). This suggests that tractography can play an important role during surgical planning.

As it is the case with any imaging technique, the surgical strategy shouldn't be blindly guided by the WMT results alone, and interpretation of the tractography results should be made with caution. For example, in brainstem cavernomas, the classic perilesional hemosiderin deposits can be responsible for susceptibility artifacts that can falsely interrupt nearby tracts (Faraji et al., 2015; Kovanlikaya et al., 2011). The close proximity of large arteries (vertebral and basilar) can also produce pulsation artifacts (Kovanlikaya et al., 2011).

Despite these limitations, the results of introducing WMT in the neurosurgical planning process already demonstrate a positive impact (Table 5). Januszewski et al. compared 5 patients whom surgery for brainstem cavernomas was performed in accordance to tractography results planning, to 5 other cases where surgery was undertaken without any fiber study. In this latter group, two patients developed post-operative deficits, while no postoperative deficit was seen in the WMT group (Januszewski et al., 2016). These results are encouraging but further investigations will be necessary to confirm this impact on the postoperative outcome.

Once surgery has been decided on, WMT can aid the selection of the safest approach corridor, particularly when choosing from the multitude of different approaches that are now described for each region of the brainstem (Abla et al., 2011; Essayed et al., 2017; Flores et al., 2015). Also, exploiting the high negative predictive value of WMT at the level of the brainstem, a more radical resection strategy can be safely adopted if major tracts are shown to be spared by the tumor. Similarly, when clear infiltration of major tracts is visible on the preoperative WMT, a more conservative surgery can be decided, particularly in paucisymptomatic patients with diffuse tumors. More prospective and standardized qualitative and quantitative studies will be necessary to consolidate current available evidence on the usefulness of the WMT in this setting.

4.2. Cerebellum

Presently, WMT has limited applications in cerebellar lesions, as classic surgery in hemispheric superficial lesions usually achieves satisfying results. However, functional outcome is frequently less favorable when resected lesions involve cerebellar nuclei or the vermis (Daszkiewicz et al., 2009; Robertson et al., 2006), hence the importance of eventual tractography applications. A better understanding of the connectivity of the cerebellum with the rest of the neuraxis (Milardi et al., 2016; van Baarsen et al., 2016) is progressively enlarging the indication for WMT in cerebellar lesions, as demonstrated by a recent report by Fernandes-Cabral et al. who used high-definition fiber tractography for the surgical planning of a patient suffering from a Lhermitte-Duclos disease (Fernandes-Cabral et al., 2016). In this case, HDFT helped identify displaced middle cerebellar peduncle fibers around the dysplastic gangliocytoma, a distinction impossible to achieve with conventional imaging.

4.3. Cranial nerves

Skull base tumors have complex relationships with local structures. Along with preserving vascular structures, preservation of cranial nerves (CN) is one of the challenging principles of skull base surgery. During surgery, the identification of the different CN in the surroundings of a large skull base tumor is still problematic, particularly through the limited access usually attainable to the skull base. In modern practice, imaging advances can guide preoperative planning with precision (Dolati et al., 2015).

WMT is a new tool for refining these pre-operative studies. The improvement of tractography protocols allowed multiple teams to publish extensive and detailed CN reconstructions not only in normal, but also pathological situations (Chen et al., 2011; Hodaie et al., 2010; Vos et al., 2015; Yoshino et al., 2016; Yoshino et al., 2015). One of the

Table 5
Summary of reports of WMT use for brainstem lesions surgery.

Authors	Year	# pts	Acquisition	Tracing method	Results
Faraji et al.	2005	3	DSI; b = 7000; Dir = 257	Deterministic (GDFT, in DSI Studio)	Hemorrhagic brainstem CMs can disrupt and displace perilesional white matter tracts with the latter occurring in unpredictable directions. Observed anisotropy decreases in the perilesional segments are consistent with neural injury following hemorrhagic insults.
Kovalikaya et al.	2011	14	DTI; b = 800; Dir = 32	Deterministic (in PRIDE, Philips)	Although it has low specificity before surgery, DTT is a potentially useful technique in evaluating the effects of brainstem lesions and surgical resection on the relevant corticospinal tracts with high negative predictive value and higher specificity after surgery.
Januszeski et al.	2016	16	DTI; b = 800; Dir = 33	Deterministic (in FuncTool, GE)	Compared with the standard MR imaging, DTI provided improved visualization of cavernous malformation involvement in eloquent fiber tracts of the brainstem. This additional information might help in selecting a more appropriate surgical trajectory in selected lesions.

pts: total number of patients; generalized deterministic fiber tracking algorithm.

Table 6
Review of the literature in surgically validated tractographic localization of the facial nerve, in large vestibular schwannoma surgery.

Authors	Year	# pts	DTI		Results	
			Acquisition	Tracing method	# pts possible tractography	# pts accurate tractography
GerGanov et al.	2011	22	b = 1000; Dir = 12	Deterministic (FACT, in iPlan v.2.6, BrainLab)	22 (100%)	20 (91%)
Song et al.	2016	15	b = 1000; Dir = 30	Deterministic (second-order Runge-Kutta, in 3D Slicer)	14 (93%)	13 (93%)
Taoka et al.	2006	8	b = 1000; Dir = 6	Deterministic (in dTV v.II)	7 (88%)	5 (71%)
Wei et al.	2015	23	b = N/A; Dir = 30	Deterministic (FACT, in iPlan v.3.03, BrainLab)	21 (91%)	21 (100%)
Zhang et al.	2013	8	b = 1000; Dir = N/A	NR	7 (88%)	7 (100%)
Total		76			71 (93%)	66 (87%)

pts: total number of patients, NR: not reported.

major applications of WMT in skull base surgery is the preoperative identification of the facial nerve (FN) position, in patients harboring large vestibular schwannomas. We reviewed the existing literature comparing tractography predicted FN position with intraoperative findings (Table 6) (Gerganov et al., 2011; Song et al., 2016; Taoka et al., 2006; Wei et al., 2015; Zhang et al., 2013). FN tractography reconstruction was possible in 93% of the cases (71/76). The predicted course of the FN around the vestibular schwannoma was accurate in 93% (66/71) of the patients in whom tractography was possible. Overall, tractography helped identify the FN position in 87% (66/76) of the cases (Table 6). Identification of other cranial nerves was also possible in some of these reports. Such results are encouraging; however, further prospective studies will be necessary to prove the real impact of such information on the surgical outcome.

4.4. Technical considerations

We note that as discussed in the supratentorial section, complex WMT methods such as HDFT (Abhinav et al., 2015), UKF tractography (Chen et al., 2015; Chen et al., 2016b), and constrained spherical deconvolution tractography (Lim et al., 2015), in combination with high or multiple b-value acquisitions, are progressively pushing the boundaries of identifiable structures, detecting smaller and more complex structures in the infratentorial compartment (Meola et al., 2016; Milardi et al., 2016; Wenz et al., 2016). However, particularly when addressing skull base, frontopolar and brainstem structures for WMT, susceptibility artifacts and distortion related to the echo-planar imaging (EPI) diffusion MRI acquisition are of high importance (Treiber et al., 2016). Recent studies have addressed this challenge at the acquisition level using readout-segmented (RS) EPI, which was shown to significantly reduce distortions at the expense of increased acquisition time (Ginat et al., 2014; Iima et al., 2012; Koyasu et al., 2014).

5. Conclusions

Incorporating tractographic techniques into the modern operative room, in conjunction with other new anatomical and functional imaging, navigation, and electrophysiological tools, is progressively emerging as an integral part of the surgical treatment of multiple neurosurgical pathologies. The high variability of methods and techniques for white matter tractography limits the interpretation of some of the current results. Progressive improvements of scanning and tractography methods are helping to overcome these current limitations. Future standardized and prospective studies will help assess the full impact of this tool in neurosurgical planning.

Acknowledgements

We gratefully acknowledge the funding provided by the following National Institutes of Health (NIH) grants: R25:114526, U01:CA199459, P41:EB015898, P41:EB015902.

References

Abdullah, K.G., Lubelski, D., Nucifora, P.G., Brem, S., 2013. Use of diffusion tensor imaging in glioma resection. Neurosurg. Focus. 34, E1.
Abhinav, K., Yeh, F.C., Mansouri, A., Zadeh, G., Fernandez-Miranda, J.C., 2015. High-definition fiber tractography for the evaluation of perilesional white matter tracts in high-grade glioma surgery. Neuro-Oncology 17, 1199–1209.
Abla, A.A., Lekovic, G.P., Turner, J.D., de Oliveira, J.G., Porter, R., Spetzler, R.F., 2011. Advances in the treatment and outcome of brainstem cavernous malformation surgery: a single-center case series of 300 surgically treated patients. Neurosurgery 68, 403–414 (discussion 414-405).
Akai, H., Mori, H., Aoki, S., Masutani, Y., Kawahara, N., Shibahara, J., Ohtomo, K., 2005. Diffusion tensor tractography of gliomatosis cerebri: fiber tracking through the tumor. J. Comput. Assist. Tomogr. 29, 127–129.
Alexander, A.L., Lee, J.E., Lazar, M., Field, A.S., 2007. Diffusion tensor imaging of the brain. Neurotherapeutics 4, 316–329.
Alkadhi, H., Kollias, S.S., Crelier, G.R., Golay, X., Hepp-Reymond, M.C., Valavanis, A., 2000. Plasticity of the human motor cortex in patients with arteriovenous malformations: a functional MR imaging study. AJNR Am. J. Neuroradiol. 21, 1423–1433.
Anastasopoulos, C., Reisert, M., Kiselev, V.G., Nguyen-Thanh, T., Schulze-Bonhage, A., Zentner, J., Mader, I., 2014. Local and global fiber tractography in patients with epilepsy. AJNR Am. J. Neuroradiol. 35, 291–296.
Assaf, Y., Pasternak, O., 2008. Diffusion tensor imaging (DTI)-based white matter mapping in brain research: a review. J. Mol. Neurosci. 34, 51–61.
van Baarsen, K.M., Kleinnijenhuis, M., Jbabdi, S., Sotiropoulos, S.N., Grotenhuis, J.A., van Cappellen van Walsum, A.M., 2016. A probabilistic atlas of the cerebellar white matter. NeuroImage 124, 724–732.
Barbosa, B.J., Dimostheni, A., Teixeira, M.J., Tatagiba, M., Lepski, G., 2016. Insular gliomas and the role of intraoperative assistive technologies: results from a volumetry-based retrospective cohort. Clin. Neurol. Neurosurg. 149, 104–110.
Barkhoudarian, G., Klochkov, T., Sedrak, M., Frew, A., Gorgulho, A., Behnke, E., De Salles, A., 2010. A role of diffusion tensor imaging in movement disorder surgery. Acta Neurochir. 152, 2089–2095.
Basser, P.J., Mattiello, J., LeBihan, D., 1994. MR diffusion tensor spectroscopy and imaging. Biophys. J. 66, 259–267.
Basser, P.J., Pajevic, S., Pierpaoli, C., Duda, J., Aldroubi, A., 2000. In vivo fiber tractography using DT-MRI data. Magn. Reson. Med. 44, 625–632.
Behrens, T.E., Berg, H.J., Jbabdi, S., Rushworth, M.F., Woolrich, M.W., 2007. Probabilistic diffusion tractography with multiple fibre orientations: what can we gain? NeuroImage 34, 144–155.
Bello, L., Gambini, A., Castellano, A., Carrabba, G., Acerbi, F., Fava, E., Giussani, C., Cadioli, M., Blasi, V., Casarotti, A., Papagno, C., Gupta, A.K., Gaini, S., Scotti, G., Falini, A., 2008. Motor and language DTI Fiber Tracking combined with intraoperative subcortical mapping for surgical removal of gliomas. NeuroImage 39, 369–382.
Berman, J., 2009. Diffusion MR tractography as a tool for surgical planning. Magn. Reson. Imaging Clin. N. Am. 17, 205–214.
Bi, W.L., Chiocca, E.A., 2014. From localization to pathways: the continuing evolution of diffusion tensor imaging. World Neurosurg 82, e47–e48.
Burgel, U., Madler, B., Honey, C.R., Thron, A., Gilsbach, J., Coenen, V.A., 2009. Fiber tracking with distinct software tools results in a clear diversity in anatomical fiber tract portrayal. Cen. Eur. Neurosurg. 70, 27–35.
Calabrese, E., 2016. Diffusion tractography in deep brain stimulation surgery: a review.

Front. Neuroanat. 10, 45.
Campbell, J.S., Pike, G.B., 2014. Potential and limitations of diffusion MRI tractography for the study of language. Brain Lang. 131, 65–73.
Carlson, H.L., Laliberte, C., Brooks, B.L., Hodge, J., Kirton, A., Bello-Espinosa, L., Hader, W., Sherman, E.M., 2014. Reliability and variability of diffusion tensor imaging (DTI) tractography in pediatric epilepsy. Epilepsy Behav. 37, 116–122.
Castellano, A., Bello, L., Michelozzi, C., Gallucci, M., Fava, E., Iadanza, A., Riva, M., Casaceli, G., Falini, A., 2012. Role of diffusion tensor magnetic resonance tractography in predicting the extent of resection in glioma surgery. Neuro-Oncology 14, 192–202.
Catani, M., Thiebaut de Schotten, M., 2008. A diffusion tensor imaging tractography atlas for virtual in vivo dissections. Cortex 44, 1105–1132.
Cavalcanti, D.D., Preul, M.C., Kalani, M.Y., Spetzler, R.F., 2016. Microsurgical anatomy of safe entry zones to the brainstem. J. Neurosurg. 124, 1359–1376.
Caverzasi, E., Hervey-Jumper, S.L., Jordan, K.M., Lobach, I.V., Li, J., Panara, V., Racine, C.A., Sankaranarayanan, V., Amirbekian, B., Papinutto, N., Berger, M.S., Henry, R.G., 2016. Identifying preoperative language tracts and predicting postoperative functional recovery using HARDI q-ball fiber tractography in patients with gliomas. J. Neurosurg. 125, 33–45.
Chamberland, M., Whittingstall, K., Fortin, D., Mathieu, D., Descoteaux, M., 2014. Real-time multi-peak tractography for instantaneous connectivity display. Front. Neuroinform. 8, 59.
Chamberland, M., Bernier, M., Fortin, D., Whittingstall, K., Descoteaux, M., 2015. 3D interactive tractography-informed resting-state fMRI connectivity. Front. Neurosci. 9, 275.
Chamberland, M., Scherrer, B., Prabhu, S.P., Madsen, J., Fortin, D., Whittingstall, K., Descoteaux, M., Warfield, S.K., 2017. Active delineation of Meyer's loop using oriented priors through MAGNEtic Tractography (MAGNET). Hum. Brain Mapp. 38, 509–527.
Chang, E.F., Raygor, K.P., Berger, M.S., 2015. Contemporary model of language organization: an overview for neurosurgeons. J. Neurosurg. 122, 250–261.
Charras, P., Herbet, G., Deverdun, J., de Champfleur, N.M., Duffau, H., Bartolomeo, P., Bonnetblanc, F., 2015. Functional reorganization of the attentional networks in low-grade glioma patients: a longitudinal study. Cortex 63, 27–41.
Chen, X., Weigel, D., Ganslandt, O., Buchfelder, M., Nimsky, C., 2009. Prediction of visual field deficits by diffusion tensor imaging in temporal lobe epilepsy surgery. NeuroImage 45, 286–297.
Chen, D.Q., Quan, J., Guha, A., Tymianski, M., Mikulis, D., Hodaie, M., 2011. Three-dimensional in vivo modeling of vestibular schwannomas and surrounding cranial nerves with diffusion imaging tractography. Neurosurgery 68, 1077–1083.
Chen, Z., Tie, Y., Olubiyi, O., Rigolo, L., Mehrtash, A., Norton, I., Pasternak, O., Rathi, Y., Golby, A.J., O'Donnell, L.J., 2015. Reconstruction of the arcuate fasciculus for surgical planning in the setting of peritumoral edema using two-tensor unscented Kalman filter tractography. Neuroimage Clin 7, 815–822.
Chen, Z., Tie, Y., Olubiyi, O., Zhang, F., Mehrtash, A., Rigolo, L., Kahali, P., Norton, I., Pasternak, O., Rathi, Y., Golby, A.J., O'Donnell, L.J., 2016a. Corticospinal tract modeling for neurosurgical planning by tracking through regions of peritumoral edema and crossing fibers using two-tensor unscented Kalman filter tractography. Int. J. Comput. Assist. Radiol. Surg. 11, 1475–1486.
Chen, Z., Tie, Y., Olubiyi, O., Zhang, F., Mehrtash, A., Rigolo, L., Kahali, P., Norton, I., Pasternak, O., Rathi, Y., Golby, A.J., O'Donnell, L.J., 2016b. Corticospinal Tract Modeling for Neurosurgical Planning by Tracking Through Regions of Peritumoral Edema and Crossing Fibers Using Two-Tensor Unscented Kalman Filter Tractography. (Int J Comput Assist Radiol Surg).
Chung, H.W., Chou, M.C., Chen, C.Y., 2011. Principles and limitations of computational algorithms in clinical diffusion tensor MR tractography. AJNR Am. J. Neuroradiol. 32, 3–13.
Ciccarelli, O., Toosy, A.T., Parker, G.J., Wheeler-Kingshott, C.A., Barker, G.J., Miller, D.H., Thompson, A.J., 2003. Diffusion tractography based group mapping of major white-matter pathways in the human brain. NeuroImage 19, 1545–1555.
Coenen, V.A., Krings, T., Mayfrank, L., Polin, R.S., Reinges, M.H., Thron, A., Gilsbach, J.M., 2001. Three-dimensional visualization of the pyramidal tract in a neuronavigation system during brain tumor surgery: first experiences and technical note. Neurosurgery 49, 86–92 (discussion 92-83).
Coenen, V.A., Allert, N., Madler, B., 2011. A role of diffusion tensor imaging fiber tracking in deep brain stimulation surgery: DBS of the dentato-rubro-thalamic tract (DRT) for the treatment of therapy-refractory tremor. Acta Neurochir. 153, 1579–1585 (discussion 1585).
Colon-Perez, L.M., Triplett, W., Bohsali, A., Corti, M., Nguyen, P.T., Patten, C., Mareci, T.H., Price, C.C., 2016. A majority rule approach for region-of-interest-guided streamline fiber tractography. Brain Imaging Behav. 10, 1137–1147.
Daducci, A., Dal Palu, A., Descoteaux, M., Thiran, J.P., 2016. Microstructure informed tractography: pitfalls and open challenges. Front. Neurosci. 10, 247.
Daga, P., Winston, G., Modat, M., White, M., Mancini, L., Cardoso, M.J., Symms, M., Stretton, J., McEvoy, A.W., Thornton, J., Micallef, C., Yousry, T., Hawkes, D.J., Duncan, J.S., Ourselin, S., 2012. Accurate localization of optic radiation during neurosurgery in an interventional MRI suite. IEEE Trans. Med. Imaging 31, 882–891.
D'Andrea, G., Familiari, P., Di Lauro, A., Angelini, A., Sessa, G., 2016. Safe resection of gliomas of the dominant angular gyrus availing of preoperative FMRI and intraoperative DTI: preliminary series and surgical technique. World Neurosurg 87, 627–639.
Daszkiewicz, P., Maryniak, A., Roszkowski, M., Barszcz, S., 2009. Long-term functional outcome of surgical treatment of juvenile pilocytic astrocytoma of the cerebellum in children. Childs Nerv. Syst. 25, 855–860.
Descoteaux, M., Deriche, R., Knosche, T.R., Anwander, A., 2009. Deterministic and probabilistic tractography based on complex fibre orientation distributions. IEEE Trans. Med. Imaging 28, 269–286.
Diehl, B., Tkach, J., Piao, Z., Ruggieri, P., LaPresto, E., Liu, P., Fisher, E., Bingaman, W., Najm, I., 2010. Diffusion tensor imaging in patients with focal epilepsy due to cortical dysplasia in the temporo-occipital region: electro-clinico-pathological correlations. Epilepsy Res. 90, 178–187.
Dolati, P., Golby, A., Eichberg, D., Abolfotoh, M., Dunn, I.F., Mukundan, S., Hulou, M.M., Al-Mefty, O., 2015. Pre-operative image-based segmentation of the cranial nerves and blood vessels in microvascular decompression: can we prevent unnecessary explorations? Clin. Neurol. Neurosurg. 139, 159–165.
Duffau, H., 2005. Lessons from brain mapping in surgery for low-grade glioma: insights into associations between tumour and brain plasticity. Lancet Neurol. 4, 476–486.
Duffau, H., 2014. Diffusion tensor imaging is a research and educational tool, but not yet a clinical tool. World Neurosurg 82, e43–e45.
Duffau, H., 2015. Stimulation mapping of white matter tracts to study brain functional connectivity. Nat. Rev. Neurol. 11, 255–265.
Ellis, M.J., Rutka, J.T., Kulkarni, A.V., Dirks, P.B., Widjaja, E., 2012. Corticospinal tract mapping in children with ruptured arteriovenous malformations using functionally guided diffusion-tensor imaging. J. Neurosurg. Pediatr. 9, 505–510.
Essayed, W.I., Singh, H., Lapadula, G., Almodovar-Mercado, G.J., Anand, V.K., Schwartz, T.H., 2017. Endoscopic endonasal approach to the ventral brainstem: anatomical feasibility and surgical limitations. J. Neurosurg. 1–8.
Fan, X., Roberts, D.W., Schaewe, T.J., Ji, S., Holton, L.H., Simon, D.A., Paulsen, K.D., 2016. Intraoperative image updating for brain shift following dural opening. J. Neurosurg. 1–10.
Faraji, A.H., Abhinav, K., Jarbo, K., Yeh, F.C., Shin, S.S., Pathak, S., Hirsch, B.E., Schneider, W., Fernandez-Miranda, J.C., Friedlander, R.M., 2015. Longitudinal evaluation of corticospinal tract in patients with resected brainstem cavernous malformations using high-definition fiber tractography and diffusion connectometry analysis: preliminary experience. J. Neurosurg. 123, 1133–1144.
Farquharson, S., Tournier, J.D., Calamante, F., Fabinyi, G., Schneider-Kolsky, M., Jackson, G.D., Connelly, A., 2013. White matter fiber tractography: why we need to move beyond DTI. J. Neurosurg. 118, 1367–1377.
Farshidfar, Z., Faeghi, F., Mohseni, M., Seddighi, A., Kharrazi, H.H., Abdolmohammadi, J., 2014. Diffusion tensor tractography in the presurgical assessment of cerebral gliomas. Neuroradiol. J. 27, 75.
Fernandes-Cabral, D.T., Zenonos, G.A., Hamilton, R.L., Panesar, S.S., Fernandez-Miranda, J.C., 2016. High-definition fiber tractography in the evaluation and surgical planning of Lhermitte-Duclos disease: a case report. World Neurosurg 92 (587.e589–587.e513).
Fernandez-Miranda, J.C., Pathak, S., Engh, J., Jarbo, K., Verstynen, T., Yeh, F.C., Wang, Y., Mintz, A., Boada, F., Schneider, W., Friedlander, R., 2012. High-definition fiber tractography of the human brain: neuroanatomical validation and neurosurgical applications. Neurosurgery 71, 430–453.
Flores, B.C., Whittemore, A.R., Samson, D.S., Barnett, S.L., 2015. The utility of preoperative diffusion tensor imaging in the surgical management of brainstem cavernous malformations. J. Neurosurg. 122, 653–662.
van Geemen, K., Herbet, G., Moritz-Gasser, S., Duffau, H., 2014. Limited plastic potential of the left ventral premotor cortex in speech articulation: evidence from intraoperative awake mapping in glioma patients. Hum. Brain Mapp. 35, 1587–1596.
Gerard, I.J., Collins, D.L., 2015. An analysis of tracking error in image-guided neurosurgery. Int. J. Comput. Assist. Radiol. Surg. 10, 1579–1588.
Gerganov, V.M., Giordano, M., Samii, M., Samii, A., 2011. Diffusion tensor imaging-based fiber tracking for prediction of the position of the facial nerve in relation to large vestibular schwannomas. J. Neurosurg. 115, 1087–1093.
Ginat, D.T., Mangla, R., Yeaney, G., Ekholm, S., 2014. Diffusion-weighted imaging of skull lesions. J Neurol Surg B Skull Base 75, 204–213.
Girard, G., Whittingstall, K., Deriche, R., Descoteaux, M., 2014. Towards quantitative connectivity analysis: reducing tractography biases. NeuroImage 98, 266–278.
Goebell, E., Paustenbach, S., Vaeterlein, O., Ding, X.Q., Heese, O., Fiehler, J., Kucinski, T., Hagel, C., Westphal, M., Zeumer, H., 2006. Low-grade and anaplastic gliomas: differences in architecture evaluated with diffusion-tensor MR imaging. Radiology 239, 217–222.
Golby, A.J., Kindlmann, G., Norton, I., Yarmarkovich, A., Pieper, S., Kikinis, R., 2011. Interactive diffusion tensor tractography visualization for neurosurgical planning. Neurosurgery 68, 496–505.
Gradinaru, V., Mogri, M., Thompson, K.R., Henderson, J.M., Deisseroth, K., 2009. Optical deconstruction of parkinsonian neural circuitry. Science 324, 354–359.
Hagmann, P., Jonasson, L., Maeder, P., Thiran, J.P., Wedeen, V.J., Meuli, R., 2006. Understanding diffusion MR imaging techniques: from scalar diffusion-weighted imaging to diffusion tensor imaging and beyond. Radiographics 26 (Suppl. 1), S205–S223.
Henderson, J.M., 2012. "Connectomic surgery": diffusion tensor imaging (DTI) tractography as a targeting modality for surgical modulation of neural networks. Front. Integr. Neurosci. 6, 15.
Hodaie, M., Quan, J., Chen, D.Q., 2010. In vivo visualization of cranial nerve pathways in humans using diffusion-based tractography. Neurosurgery 66, 788–795 (discussion 795-786).
Holodny, A.I., Ollenschleger, M.D., Liu, W.C., Schulder, M., Kalnin, A.J., 2001a. Identification of the corticospinal tracts achieved using blood-oxygen-level-dependent and diffusion functional MR imaging in patients with brain tumors. AJNR Am. J. Neuroradiol. 22, 83–88.
Holodny, A.I., Schwartz, T.H., Ollenschleger, M., Liu, W.C., Schulder, M., 2001b. Tumor involvement of the corticospinal tract: diffusion magnetic resonance tractography with intraoperative correlation. J. Neurosurg. 95, 1082.
Huang, H., Zhang, J., van Zijl, P.C., Mori, S., 2004. Analysis of noise effects on DTI-based tractography using the brute-force and multi-ROI approach. Magn. Reson. Med. 52,

559–565.
Hunsche, S., Sauner, D., Runge, M.J., Lenartz, D., El Majdoub, F., Treuer, H., Sturm, V., Maarouf, M., 2013. Tractography-guided stimulation of somatosensory fibers for thalamic pain relief. Stereotact. Funct. Neurosurg. 91, 328–334.
Iima, M., Yamamoto, A., Brion, V., Okada, T., Kanagaki, M., Togashi, K., Le Bihan, D., 2012. Reduced-distortion diffusion MRI of the craniovertebral junction. AJNR Am. J. Neuroradiol. 33, 1321–1325.
Irfanoglu, M.O., Modi, P., Nayak, A., Hutchinson, E.B., Sarlls, J., Pierpaoli, C., 2015. DR-BUDDI (Diffeomorphic Registration for Blip-Up blip-Down Diffusion Imaging) method for correcting echo planar imaging distortions. NeuroImage 106, 284–299.
Itoh, D., Aoki, S., Maruyama, K., Masutani, Y., Mori, H., Masumoto, T., Abe, O., Hayashi, N., Okubo, T., Ohtomo, K., 2006. Corticospinal tracts by diffusion tensor tractography in patients with arteriovenous malformations. J. Comput. Assist. Tomogr. 30, 618–623.
Jang, S.H., Kim, S.H., Chang, M.C., 2016. Injury of the arcuate fasciculus in the non-dominant hemisphere by subfalcine herniation in patients with intracerebral hemorrhage: two case reports and literature review. J. Korean Neurosurg. Soc. 59, 306–309.
Januszewski, J., Albert, L., Black, K., Dehdashti, A.R., 2016. The Usefulness of Diffusion Tensor Imaging and Tractography in Surgery of Brainstem Cavernous Malformations. (World Neurosurg).
Javadi, S.A., Nabavi, A., Giordano, M., Faghihzadeh, E., Samii, A., 2017. Evaluation of diffusion tensor imaging-based tractography of the corticospinal tract: a correlative study with intraoperative magnetic resonance imaging and direct electrical subcortical stimulation. Neurosurgery 80, 287–299.
Jellison, B.J., Field, A.S., Medow, J., Lazar, M., Salamat, M.S., Alexander, A.L., 2004. Diffusion tensor imaging of cerebral white matter: a pictorial review of physics, fiber tract anatomy, and tumor imaging patterns. AJNR Am. J. Neuroradiol. 25, 356–369.
Jeong, J.W., Asano, E., Juhasz, C., Chugani, H.T., 2015. Localization of specific language pathways using diffusion-weighted imaging tractography for presurgical planning of children with intractable epilepsy. Epilepsia 56, 49–57.
Jeurissen, B., Leemans, A., Tournier, J.D., Jones, D.K., Sijbers, J., 2013. Investigating the prevalence of complex fiber configurations in white matter tissue with diffusion magnetic resonance imaging. Hum. Brain Mapp. 34, 2747–2766.
Jiao, Y., Lin, F., Wu, J., Li, H., Wang, L., Jin, Z., Wang, S., Cao, Y., 2016. Lesion-to-Eloquent Fibre Distance is a Crucial Risk Factor for Pre-Surgical Evaluation of Arteriovenous Malformations in Temporo-Occipital Junctions. (World Neurosurg).
Johansen-Berg, H., Gutman, D.A., Behrens, T.E., Matthews, P.M., Rushworth, M.F., Katz, E., Lozano, A.M., Mayberg, H.S., 2008. Anatomical connectivity of the subgenual cingulate region targeted with deep brain stimulation for treatment-resistant depression. Cereb. Cortex 18, 1374–1383.
Jones, D.K., 2004. The effect of gradient sampling schemes on measures derived from diffusion tensor MRI: a Monte Carlo study. Magn. Reson. Med. 51, 807–815.
Jones, D.K., Cercignani, M., 2010. Twenty-five pitfalls in the analysis of diffusion MRI data. NMR Biomed. 23, 803–820.
Jones, D.K., Knosche, T.R., Turner, R., 2013. White matter integrity, fiber count, and other fallacies: the do's and don'ts of diffusion MRI. NeuroImage 73, 239–254.
Kammen, A., Law, M., Tjan, B.S., Toga, A.W., Shi, Y., 2016. Automated retinofugal visual pathway reconstruction with multi-shell HARDI and FOD-based analysis. NeuroImage 125, 767–779.
Kekhia, H., Rigolo, L., Norton, I., Golby, A.J., 2011. Special surgical considerations for functional brain mapping. Neurosurg. Clin. N. Am. 22 (111–132), vii.
Kikuta, K., Takagi, Y., Nozaki, K., Hashimoto, N., 2008. Introduction to tractography-guided navigation: using 3-tesla magnetic resonance tractography in surgery for cerebral arteriovenous malformations. Acta Neurochir. Suppl. 103, 11–14.
Koga, T., Maruyama, K., Kamada, K., Ota, T., Shin, M., Itoh, D., Kunii, N., Ino, K., Terahara, A., Aoki, S., Masutani, Y., Saito, N., 2012. Outcomes of diffusion tensor tractography-integrated stereotactic radiosurgery. Int. J. Radiat. Oncol. Biol. Phys. 82, 799–802.
Kombos, T., Süss, O., 2009. Neurophysiological basis of direct cortical stimulation and applied neuroanatomy of the motor cortex: a review. Neurosurg. Focus. 27, E3.
Kovanlikaya, I., Firat, Z., Kovanlikaya, A., Ulug, A.M., Cihangiroglu, M.M., John, M., Bingol, C.A., Ture, U., 2011. Assessment of the corticospinal tract alterations before and after resection of brainstem lesions using Diffusion Tensor Imaging (DTI) and tractography at 3 T. Eur. J. Radiol. 77, 383–391.
Koyasu, S., Iima, M., Umeoka, S., Morisawa, N., Porter, D.A., Ito, J., Le Bihan, D., Togashi, K., 2014. The clinical utility of reduced-distortion readout-segmented echo-planar imaging in the head and neck region: initial experience. Eur. Radiol. 24, 3088–3096.
Kuhnt, D., Bauer, M.H., Becker, A., Merhof, D., Zolal, A., Richter, M., Grummich, P., Ganslandt, O., Buchfelder, M., Nimsky, C., 2012. Intraoperative visualization of fiber tracking based reconstruction of language pathways in glioma surgery. Neurosurgery 70, 911–919 (discussion 919-920).
Kumar, P., Yadav, A.K., Misra, S., Kumar, A., Chakravarty, K., Prasad, K., 2016. Prediction of Upper Extremity Motor Recovery After Subacute Intracerebral Hemorrhage Through Diffusion Tensor Imaging: A Systematic Review and Meta-Analysis. (Neuroradiology).
Labib, M.A., Shah, M., Kassam, A.B., Young, R., Zucker, L., Maioriello, A., Britz, G., Agbi, C., Day, J.D., Gallia, G., Kerr, R., Pradilla, G., Rovin, R., Kulwin, C., Bailes, J., 2016. The Safety and Feasibility of Image-Guided BrainPath-Mediated Transsulcul Hematoma Evacuation: A Multicenter Study. (Neurosurgery).
Lawes, I.N., Barrick, T.R., Murugam, V., Spierings, N., Evans, D.R., Song, M., Clark, C.A., 2008. Atlas-based segmentation of white matter tracts of the human brain using diffusion tensor tractography and comparison with classical dissection. NeuroImage 39, 62–79.
Lemaire, J.J., Golby, A., Wells 3rd, W.M., Pujol, S., Tie, Y., Rigolo, L., Yarmarkovich, A., Pieper, S., Westin, C.F., Jolesz, F., Kikinis, R., 2013. Extended Broca's area in the functional connectome of language in adults: combined cortical and subcortical single-subject analysis using fMRI and DTI tractography. Brain Topogr. 26, 428–441.
Lilja, Y., Ljungberg, M., Starck, G., Malmgren, K., Rydenhag, B., Nilsson, D.T., 2014. Visualizing Meyer's loop: a comparison of deterministic and probabilistic tractography. Epilepsy Res. 108, 481–490.
Lim, J.C., Phal, P.M., Desmond, P.M., Nichols, A.D., Kokkinos, C., Danesh-Meyer, H.V., Kaye, A.H., Moffat, B.A., 2015. Probabilistic MRI tractography of the optic radiation using constrained spherical deconvolution: a feasibility study. PLoS One 10, e0118948.
Lujan, J.L., Chaturvedi, A., Malone, D.A., Rezai, A.R., Machado, A.G., McIntyre, C.C., 2012. Axonal pathways linked to therapeutic and nontherapeutic outcomes during psychiatric deep brain stimulation. Hum. Brain Mapp. 33, 958–968.
Maesawa, S., Fujii, M., Nakahara, N., Watanabe, T., Wakabayashi, T., Yoshida, J., 2010. Intraoperative tractography and motor evoked potential (MEP) monitoring in surgery for gliomas around the corticospinal tract. World Neurosurg. 74, 153–161.
Maier-Hein, K., Neher, P., Houde, J.-C., Cote, M.-A., Garyfallidis, E., Zhong, J., Chamberland, M., Yeh, F.-C., Lin, Y.C., Ji, Q., Reddick, W.E., Glass, J.O., Chen, D.Q., Feng, Y., Gao, C., Wu, Y., Ma, J., Renjie, H., Li, Q., Westin, C.-F., Deslauriers-Gauthier, S., Gonzalez, J.O.O., Paquette, M., St-Jean, S., Girard, G., Rheault, F., Sidhu, J., Tax, C.M.W., Guo, F., Mesri, H.Y., David, S., Froeling, M., Heemskerk, A.M., Leemans, A., Bore, A., Pinsard, B., Bedetti, C., Desrosiers, M., Brambati, S., Doyon, J., Sarica, A., Vasta, R., Cerasa, A., Quattrone, A., Yeatman, J., Khan, A.R., Hodges, W., Alexander, S., Romascano, D., Barakovic, M., Auria, A., Esteban, O., Lemkaddem, A., Thiran, J.-P., Cetingul, H.E., Odry, B.L., Mailhe, B., Nadar, M., Pizzagalli, F., Prasad, G., Villalon-Reina, J., Galvis, J., Thompson, P., Requejo, F., Laguna, P., Lacerda, L., Barrett, R., Dell'Acqua, F., Catani, M., Petit, L., Caruyer, E., Daducci, A., Dyrby, T., Holland-Letz, T., Hilgetag, C., Stieltjes, B., Descoteaux, M., 2016. Tractography-Based Connectomes are Dominated by False-Positive Connections. bioRxiv.
Malcolm, J.G., Shenton, M.E., Rathi, Y., 2010. Filtered multitensor tractography. IEEE Trans. Med. Imaging 29, 1664–1675.
Mangin, J.F., Fillard, P., Cointepas, Y., Le Bihan, D., Frouin, V., Poupon, C., 2013. Toward global tractography. NeuroImage 80, 290–296.
Martinez-Heras, E., Varriano, F., Prckovska, V., Laredo, C., Andorra, M., Martinez-Lapiscina, E.H., Calvo, A., Lampert, E., Villoslada, P., Saiz, A., Prats-Galino, A., Llufriu, S., 2015. Improved framework for tractography reconstruction of the optic radiation. PLoS One 10, e0137064.
McDonald, C.R., Ahmadi, M.E., Hagler, D.J., Tecoma, E.S., Iragui, V.J., Gharapetian, L., Dale, A.M., Halgren, E., 2008. Diffusion tensor imaging correlates of memory and language impairments in temporal lobe epilepsy. Neurology 71, 1869–1876.
McGirt, M.J., Chaichana, K.L., Gathinji, M., Attenello, F.J., Than, K., Olivi, A., Weingart, J.D., Brem, H., Quinones-Hinojosa, A.R., 2009. Independent association of extent of resection with survival in patients with malignant brain astrocytoma. J. Neurosurg. 110, 156–162.
McIntyre, C.C., Savasta, M., Kerkerian-Le Goff, L., Vitek, J.L., 2004. Uncovering the mechanism(s) of action of deep brain stimulation: activation, inhibition, or both. Clin. Neurophysiol. 115, 1239–1248.
McNab, J.A., Voets, N.L., Jenkinson, N., Squier, W., Miller, K.L., Goodwin, G.M., Aziz, T.Z., 2009. Reduced limbic connections may contraindicate subgenual cingulate deep brain stimulation for intractable depression. J. Neurosurg. 111, 780–784.
Meola, A., Yeh, F.C., Fellows-Mayle, W., Weed, J., Fernandez-Miranda, J.C., 2016. Human Connectome-Based Tractographic Atlas of the Brainstem Connections and Surgical Approaches. (Neurosurgery).
Milardi, D., Arrigo, A., Anastasi, G., Cacciola, A., Marino, S., Mormina, E., Calamuneri, A., Bruschetta, D., Cutroneo, G., Trimarchi, F., Quartarone, A., 2016. Extensive direct subcortical cerebellum-basal ganglia connections in human brain as revealed by constrained spherical deconvolution tractography. Front. Neuroanat. 10, 29.
Mormina, E., Longo, M., Arrigo, A., Alafaci, C., Tomasello, F., Calamuneri, A., Marino, S., Gaeta, M., Vinci, S.L., Granata, F., 2015. MRI tractography of corticospinal tract and arcuate fasciculus in high-grade gliomas performed by constrained spherical deconvolution: qualitative and quantitative analysis. AJNR Am. J. Neuroradiol. 36, 1853–1858.
Neher, P.F., Götz, M., Norajitra, T., Weber, C., Maier-Hein, K.H., 2015. A machine learning based approach to fiber tractography using classifier voting. In: Navab, N., Hornegger, J., Wells, W.M., Frangi, A.F. (Eds.), Medical Image Computing and Computer-Assisted Intervention – MICCAI 2015: 18th International Conference, Munich, Germany, October 5–9, 2015, Proceedings, Part I. Springer International Publishing, Cham, pp. 45–52.
Nilsson, D., Starck, G., Ljungberg, M., Ribbelin, S., Jonsson, L., Malmgren, K., Rydenhag, B., 2007. Intersubject variability in the anterior extent of the optic radiation assessed by tractography. Epilepsy Res. 77, 11–16.
Nimsky, C., 2014. Fiber tracking–we should move beyond diffusion tensor imaging. World Neurosurg 82, 35–36.
Nimsky, C., Ganslandt, O., Hastreiter, P., Wang, R., Benner, T., Sorensen, A.G., Fahlbusch, R., 2005. Intraoperative diffusion-tensor MR imaging: shifting of white matter tracts during neurosurgical procedures–initial experience. Radiology 234, 218–225.
Nimsky, C., Ganslandt, O., Merhof, D., Sorensen, A.G., Fahlbusch, R., 2006. Intraoperative visualization of the pyramidal tract by diffusion-tensor-imaging-based fiber tracking. NeuroImage 30, 1219–1229.
Nimsky, C., Bauer, M., Carl, B., 2016a. Merits and limits of tractography techniques for the uninitiated. In: Schramm, J. (Ed.), Advances and Technical Standards in Neurosurgery: Volume 43. Springer International Publishing, Cham, pp. 37–60.
Nimsky, C., Bauer, M., Carl, B., 2016b. Merits and limits of tractography techniques for the uninitiated. Adv. Tech. Stand. Neurosurg. 37–60.
Ning, L., Laun, F., Gur, Y., DiBella, E.V., Deslauriers-Gauthier, S., Megherbi, T., Ghosh, A., Zucchelli, M., Menegaz, G., Fick, R., St-Jean, S., Paquette, M., Aranda, R., Descoteaux, M., Deriche, R., O'Donnell, L., Rathi, Y., 2015. Sparse reconstruction

challenge for diffusion MRI: validation on a physical phantom to determine which acquisition scheme and analysis method to use? Med. Image Anal. 26, 316–331.
Niu, C., Liu, X., Yang, Y., Zhang, K., Min, Z., Wang, M., Li, W., Guo, L., Lin, P., Zhang, M., 2016. Assessing region of interest schemes for the corticospinal tract in patients with brain tumors. Medicine (Baltimore) 95, e3189.
Nowell, M., Vos, S.B., Sidhu, M., Wilcoxen, K., Sargsyan, N., Ourselin, S., Duncan, J.S., 2016. Meyer's loop asymmetry and language lateralisation in epilepsy. J. Neurol. Neurosurg. Psychiatry 87, 836–842.
O'Donnell, L.J., Westin, C.F., 2011. An introduction to diffusion tensor image analysis. Neurosurg. Clin. N. Am. 22 (185–196), viii.
O'Donnell, L.J., Rigolo, L., Norton, I., Wells 3rd, W.M., Westin, C.F., Golby, A.J., 2012. fMRI-DTI modeling via landmark distance atlases for prediction and detection of fiber tracts. NeuroImage 60, 456–470.
O'Donnell, L.J., Golby, A.J., Westin, C.F., 2013. Fiber clustering versus the parcellation-based connectome. NeuroImage 80, 283–289.
O'Donnell, L.J., Suter, Y., Rigolo, L., Kahali, P., Zhang, F., Norton, I., Albi, A., Olubiyi, O., Meola, A., Essayed, W.I., Unadkat, P., Ciris, P.A., Wells 3rd, W.M., Rathi, Y., Westin, C.F., Golby, A.J., 2017. Automated white matter fiber tract identification in patients with brain tumors. Neuroimage Clin 13, 138–153.
Okada, T., Miki, Y., Kikuta, K., Mikuni, N., Urayama, S., Fushimi, Y., Yamamoto, A., Mori, N., Fukuyama, H., Hashimoto, N., Togashi, K., 2007. Diffusion tensor fiber tractography for arteriovenous malformations: quantitative analyses to evaluate the corticospinal tract and optic radiation. AJNR Am. J. Neuroradiol. 28, 1107–1113.
Ostry, S., Belsan, T., Otahal, J., Benes, V., Netuka, D., 2013. Is intraoperative diffusion tensor imaging at 3.0 T comparable to subcortical corticospinal tract mapping? Neurosurgery 73, 797–807 (discussion 806-797).
Pantelis, E., Papadakis, N., Verigos, K., Stathochristopoulou, I., Antypas, C., Lekas, L., Tzouras, A., Georgiou, E., Salvaras, N., 2010. Integration of functional MRI and white matter tractography in stereotactic radiosurgery clinical practice. Int. J. Radiat. Oncol. Biol. Phys. 78, 257–267.
Pasternak, O., Sochen, N., Gur, Y., Intrator, N., Assaf, Y., 2009. Free water elimination and mapping from diffusion MRI. Magn. Reson. Med. 62, 717–730.
Piper, R.J., Yoong, M.M., Kandasamy, J., Chin, R.F., 2014. Application of diffusion tensor imaging and tractography of the optic radiation in anterior temporal lobe resection for epilepsy: a systematic review. Clin. Neurol. Neurosurg. 124, 59–65.
Pouratian, N., Zheng, Z., Bari, A.A., Behnke, E., Elias, W.J., Desalles, A.A., 2011. Multi-institutional evaluation of deep brain stimulation targeting using probabilistic connectivity-based thalamic segmentation. J. Neurosurg. 115, 995–1004.
Prabhu, S.S., Gasco, J., Tummala, S., Weinberg, J.S., Rao, G., 2011. Intraoperative magnetic resonance imaging-guided tractography with integrated monopolar subcortical functional mapping for resection of brain tumors. Clinical article. J. Neurosurg. 114, 719–726.
Prada, F., Del Bene, M., Mattei, L., Casali, C., Filippini, A., Legnani, F., Mangraviti, A., Saladino, A., Perin, A., Richetta, C., Vetrano, I., Moiraghi, A., Saini, M., DiMeco, F., 2014. Fusion imaging for intra-operative ultrasound-based navigation in neurosurgery. J. Ultrasound 17, 243–251.
Pujol, S., Wells, W., Pierpaoli, C., Brun, C., Gee, J., Cheng, G., Vemuri, B., Commowick, O., Prima, S., Stamm, A., Goubran, M., Khan, A., Peters, T., Neher, P., Maier-Hein, K.H., Shi, Y., Tristan-Vega, A., Veni, G., Whitaker, R., Styner, M., Westin, C.F., Gouttard, S., Norton, I., Chauvin, L., Mamata, H., Gerig, G., Nabavi, A., Golby, A., Kikinis, R., 2015. The DTI challenge: toward standardized evaluation of diffusion tensor imaging tractography for neurosurgery. J. Neuroimaging 25, 875–882.
Qazi, A.A., Radmanesh, A., O'Donnell, L., Kindlmann, G., Peled, S., Whalen, S., Westin, C.F., Golby, A.J., 2009. Resolving crossings in the corticospinal tract by two-tensor streamline tractography: method and clinical assessment using fMRI. NeuroImage 47 (Suppl. 2), T98–106.
Radmanesh, A., Zamani, A.A., Whalen, S., Tie, Y., Suarez, R.O., Golby, A.J., 2015. Comparison of seeding methods for visualization of the corticospinal tracts using single tensor tractography. Clin. Neurol. Neurosurg. 129, 44–49.
Raffelt, D., Tournier, J.D., Rose, S., Ridgway, G.R., Henderson, R., Crozier, S., Salvado, O., Connelly, A., 2012. Apparent Fibre Density: a novel measure for the analysis of diffusion-weighted magnetic resonance images. NeuroImage 59, 3976–3994.
Ritsma, B., Kassam, A., Dowlatshahi, D., Nguyen, T., Stotts, G., 2014. Minimally invasive subcortical parafascicular transsulcal access for clot evacuation (Mi SPACE) for intracerebral hemorrhage. Case Rep Neurol Med 2014, 102307.
Robertson, P.L., Muraszko, K.M., Holmes, E.J., Sposto, R., Packer, R.J., Gajjar, A., Dias, M.S., Allen, J.C., 2006. Incidence and severity of postoperative cerebellar mutism syndrome in children with medulloblastoma: a prospective study by the Children's Oncology Group. J. Neurosurg. 105, 444–451.
Romano, A., D'Andrea, G., Minniti, G., Mastronardi, L., Ferrante, L., Fantozzi, L.M., Bozzao, A., 2009. Pre-surgical planning and MR-tractography utility in brain tumour resection. Eur. Radiol. 19, 2798–2808.
Rosenstock, T., Grittner, U., Acker, G., Schwarzer, V., Kulchytska, N., Vajkoczy, P., Picht, T., 2017. Risk stratification in motor area-related glioma surgery based on navigated transcranial magnetic stimulation data. J. Neurosurg. 126, 1227–1237 (April).
Sanai, N., Polley, M.Y., McDermott, M.W., Parsa, A.T., Berger, M.S., 2011. An extent of resection threshold for newly diagnosed glioblastomas. J. Neurosurg. 115, 3–8.
Scantlebury, N., Gaetz, W., Widjaja, E., Rutka, J., Bouffet, E., Rockel, C., Mabbott, D., 2014. Functional reorganization of the corticospinal tract in a pediatric patient with an arteriovenous malformation. Neuroreport 25, 55–59.
Schlaepfer, T.E., Bewernick, B.H., Kayser, S., Madler, B., Coenen, V.A., 2013. Rapid effects of deep brain stimulation for treatment-resistant major depression. Biol. Psychiatry 73, 1204–1212.
Schlosser, M.J., McCarthy, G., Fulbright, R.K., Gore, J.C., Awad, I.A., 1997. Cerebral vascular malformations adjacent to sensorimotor and visual cortex. Functional magnetic resonance imaging studies before and after therapeutic intervention. Stroke 28, 1130–1137.
Schonberg, T., Pianka, P., Hendler, T., Pasternak, O., Assaf, Y., 2006. Characterization of displaced white matter by brain tumors using combined DTI and fMRI. NeuroImage 30, 1100–1111.
Smith, R.E., Tournier, J.D., Calamante, F., Connelly, A., 2012. Anatomically-constrained tractography: improved diffusion MRI streamlines tractography through effective use of anatomical information. NeuroImage 62, 1924–1938.
Smith, R.E., Tournier, J.D., Calamante, F., Connelly, A., 2013. SIFT: spherical-deconvolution informed filtering of tractograms. NeuroImage 67, 298–312.
Song, F., Hou, Y., Sun, G., Chen, X., Xu, B., Huang, J.H., Zhang, J., 2016. In vivo visualization of the facial nerve in patients with acoustic neuroma using diffusion tensor imaging-based fiber tracking. J. Neurosurg. 125, 787–794.
Spena, G., Panciani, P.P., Fontanella, M.M., 2015. Resection of supratentorial gliomas: the need to merge microsurgical technical cornerstones with modern functional mapping concepts. An overview. Neurosurg. Rev. 38, 59–70 (discussion 70).
Sun, H., Lunn, K.E., Farid, H., Wu, Z., Roberts, D.W., Hartov, A., Paulsen, K.D., 2005. Stereopsis-guided brain shift compensation. IEEE Trans. Med. Imaging 24, 1039–1052.
Szelényi, Andrea, Bello, Lorenzo, Duffau, Hugues, Fava, Enrica, Feigl, Guenther C., Galanda, Miroslav, Neuloh, Georg, Signorelli, Francesco, Sala, Francesco, 2010. Intraoperative electrical stimulation in awake craniotomy: methodological aspects of current practice. Neurosurg. Focus. 28, E7.
Szelenyi, A., Bello, L., Duffau, H., Fava, E., Feigl, G.C., Galanda, M., Neuloh, G., Signorelli, F., Sala, F., 2010. Intraoperative electrical stimulation in awake craniotomy: methodological aspects of current practice. Neurosurg. Focus. 28, E7.
Szmuda, M., Szmuda, T., Springer, J., Rogowska, M., Sabisz, A., Dubaniewicz, M., Mazurkiewicz-Beldzinska, M., 2016. Diffusion tensor tractography imaging in pediatric epilepsy - a systematic review. Neurol. Neurochir. Pol. 50, 1–6.
Talos, I.-F., O'Donnell, L., Westin, C.-F., Warfield, S.K., Wells, W., Yoo, S.-S., Panych, L.P., Golby, A., Mamata, H., Maier, S.S., Ratiu, P., Guttmann, C.R.G., Black, P.M., Jolesz, F.A., Kikinis, R., 2003. Diffusion tensor and functional MRI fusion with anatomical MRI for image-guided neurosurgery. In: Ellis, R.E., Peters, T.M. (Eds.), Medical Image Computing and Computer-Assisted Intervention - MICCAI 2003: 6th International Conference, Montréal, Canada, November 15–18, 2003. Proceedings. Springer Berlin Heidelberg, Berlin, Heidelberg, pp. 407–415.
Taoka, T., Hirabayashi, H., Nakagawa, H., Sakamoto, M., Myochin, K., Hirohashi, S., Iwasaki, S., Sakaki, T., Kichikawa, K., 2006. Displacement of the facial nerve course by vestibular schwannoma: preoperative visualization using diffusion tensor tractography. J. Magn. Reson. Imaging 24, 1005–1010.
Taoka, T., Sakamoto, M., Nakagawa, H., Nakase, H., Iwasaki, S., Takayama, K., Taoka, K., Hoshida, T., Sakaki, T., Kichikawa, K., 2008. Diffusion tensor tractography of the Meyer loop in cases of temporal lobe resection for temporal lobe epilepsy: correlation between postsurgical visual field defect and anterior limit of Meyer loop on tractography. AJNR Am. J. Neuroradiol. 29, 1329–1334.
Torres, C.V., Manzanares, R., Sola, R.G., 2014. Integrating diffusion tensor imaging-based tractography into deep brain stimulation surgery: a review of the literature. Stereotact. Funct. Neurosurg. 92, 282–290.
Tournier, J.D., Mori, S., Leemans, A., 2011. Diffusion tensor imaging and beyond. Magn. Reson. Med. 65, 1532–1556.
Tournier, J.D., Calamante, F., Connelly, A., 2012. MRtrix: diffusion tractography in crossing fiber regions. Int. J. Imaging Syst. Technol. 22, 53–66.
Treiber, J.M., White, N.S., Steed, T.C., Bartsch, H., Holland, D., Farid, N., McDonald, C.R., Carter, B.S., Dale, A.M., Chen, C.C., 2016. Characterization and correction of geometric distortions in 814 diffusion weighted images. PLoS One 11, e0152472.
Tuch, D.S., 2004. Q-ball imaging. Magn. Reson. Med. 52, 1358–1372.
Tuch, D.S., Reese, T.G., Wiegell, M.R., Makris, N., Belliveau, J.W., Wedeen, V.J., 2002. High angular resolution diffusion imaging reveals intravoxel white matter fiber heterogeneity. Magn. Reson. Med. 48, 577–582.
Tunc, B., Ingalhalikar, M., Parker, D., Lecoeur, J., Singh, N., Wolf, R.L., Macyszyn, L., Brem, S., Verma, R., 2015. Individualized Map of White Matter Pathways: Connectivity-Based Paradigm for Neurosurgical Planning. (Neurosurgery).
Van Essen, D.C., Smith, S.M., Barch, D.M., Behrens, T.E., Yacoub, E., Ugurbil, K., 2013. The WU-Minn human connectome project: an overview. NeuroImage 80, 62–79.
Vanegas-Arroyave, N., Lauro, P.M., Huang, L., Hallett, M., Horovitz, S.G., Zaghloul, K.A., Lungu, C., 2016. Tractography patterns of subthalamic nucleus deep brain stimulation. Brain 139, 1200–1210.
Vates, G.E., Lawton, M.T., Wilson, C.B., McDermott, M.W., Halbach, V.V., Roberts, T.P., Rowley, H.A., 2002. Magnetic source imaging demonstrates altered cortical distribution of function in patients with arteriovenous malformations. Neurosurgery 51, 614–623 (discussion 623-617).
Vos, S.B., Haakma, W., Versnel, H., Froeling, M., Speleman, L., Dik, P., Viergever, M.A., Leemans, A., Grolman, W., 2015. Diffusion tensor imaging of the auditory nerve in patients with long-term single-sided deafness. Hear. Res. 323, 1–8.
Wagner, M.W., Bell, W.R., Kern, J., Bosemani, T., Mhlanga, J., Carson, K.A., Cohen, K.J., Raabe, E.H., Rodriguez, F., Huisman, T.A., Poretti, A., 2016. Diffusion tensor imaging suggests extrapontine extension of pediatric diffuse intrinsic pontine gliomas. Eur. J. Radiol. 85, 700–706.
Wakana, S., Jiang, H., Nagae-Poetscher, L.M., van Zijl, P.C., Mori, S., 2004. Fiber tract-based atlas of human white matter anatomy. Radiology 230, 77–87.
Wakana, S., Caprihan, A., Panzenboeck, M.M., Fallon, J.H., Perry, M., Gollub, R.L., Hua, K., Zhang, J., Jiang, H., Dubey, P., Blitz, A., van Zijl, P., Mori, S., 2007. Reproducibility of quantitative tractography methods applied to cerebral white matter. NeuroImage 36, 630–644.
Wassermann, D., Makris, N., Rathi, Y., Shenton, M., Kikinis, R., Kubicki, M., Westin, C.F., 2016. The white matter query language: a novel approach for describing human white matter anatomy. Brain Struct. Funct. 221, 4705–4721.

Wedeen, V.J., Wang, R.P., Schmahmann, J.D., Benner, T., Tseng, W.Y., Dai, G., Pandya, D.N., Hagmann, P., D'Arceuil, H., de Crespigny, A.J., 2008. Diffusion spectrum magnetic resonance imaging (DSI) tractography of crossing fibers. NeuroImage 41, 1267–1277.

Wei, P.H., Qi, Z.G., Chen, G., Hu, P., Li, M.C., Liang, J.T., Guo, H.C., Ling, F., Bao, Y.H., 2015. Identification of cranial nerves near large vestibular schwannomas using superselective diffusion tensor tractography: experience with 23 cases. Acta Neurochir. 157, 1239–1249.

Weiss Lucas, C., Tursunova, I., Neuschmelting, V., Nettekoven, C., Oros-Peusquens, A.M., Stoffels, G., Faymonville, A.M., Jon, S.N., Langen, K.J., Lockau, H., Goldbrunner, R., Grefkes, C., 2017. Functional MRI vs. navigated TMS to optimize M1 seed volume delineation for DTI tractography. A prospective study in patients with brain tumours adjacent to the corticospinal tract. Neuroimage Clin 13, 297–309.

Weiss, C., Tursunova, I., Neuschmelting, V., Lockau, H., Nettekoven, C., Oros-Peusquens, A.M., Stoffels, G., Rehme, A.K., Faymonville, A.M., Shah, N.J., Langen, K.J., Goldbrunner, R., Grefkes, C., 2015. Improved nTMS- and DTI-derived CST tractography through anatomical ROI seeding on anterior pontine level compared to internal capsule. Neuroimage Clin 7, 424–437.

Wenz, H., Al-Zghloul, M., Hart, E., Kurth, S., Groden, C., Forster, A., 2016. Track-Density Images of the Human Brainstem for Anatomical Localization of Fibre Tracts and Nerve Nuclei in Vivo: Initial Experience with 3T-MRI. (World Neurosurg).

Whelan, C.D., Alhusaini, S., O'Hanlon, E., Cheung, M., Iyer, P.M., Meaney, J.F., Fagan, A.J., Boyle, G., Delanty, N., Doherty, C.P., Cavalleri, G.L., 2015. White matter alterations in patients with MRI-negative temporal lobe epilepsy and their asymptomatic siblings. Epilepsia 56, 1551–1561.

Winston, G.P., Yogarajah, M., Symms, M.R., McEvoy, A.W., Micallef, C., Duncan, J.S., 2011. Diffusion tensor imaging tractography to visualize the relationship of the optic radiation to epileptogenic lesions prior to neurosurgery. Epilepsia 52, 1430–1438.

Winston, G.P., Daga, P., Stretton, J., Modat, M., Symms, M.R., McEvoy, A.W., Ourselin, S., Duncan, J.S., 2012. Optic radiation tractography and vision in anterior temporal lobe resection. Ann. Neurol. 71, 334–341.

Winston, G.P., Daga, P., White, M.J., Micallef, C., Miserocchi, A., Mancini, L., Modat, M., Stretton, J., Sidhu, M.K., Symms, M.R., Lythgoe, D.J., Thornton, J., Yousry, T.A., Ourselin, S., Duncan, J.S., McEvoy, A.W., 2014. Preventing visual field deficits from neurosurgery. Neurology 83, 604–611.

Wu, J.S., Zhou, L.F., Tang, W.J., Mao, Y., Hu, J., Song, Y.Y., Hong, X.N., Du, G.H., 2007. Clinical evaluation and follow-up outcome of diffusion tensor imaging-based functional neuronavigation: a prospective, controlled study in patients with gliomas involving pyramidal tracts. Neurosurgery 61, 935–948 (discussion 948-939).

Wu, W., Rigolo, L., O'Donnell, L.J., Norton, I., Shriver, S., Golby, A.J., 2012. Visual pathway study using in vivo diffusion tensor imaging tractography to complement classic anatomy. Neurosurgery 70, 145–156 (discussion 156).

Yagmurlu, K., Middlebrooks, E.H., Tanriover, N., Rhoton Jr., A.L., 2016. Fiber tracts of the dorsal language stream in the human brain. J. Neurosurg. 124, 1396–1405.

Yamamoto, T., Yamada, K., Nishimura, T., Kinoshita, S., 2005. Tractography to depict three layers of visual field trajectories to the calcarine gyri. Am J. Ophthalmol. 140, 781–785.

Yamamoto, A., Miki, Y., Urayama, S., Fushimi, Y., Okada, T., Hanakawa, T., Fukuyama, H., Togashi, K., 2007. Diffusion tensor fiber tractography of the optic radiation: analysis with 6-, 12-, 40-, and 81-directional motion-probing gradients, a preliminary study. AJNR Am. J. Neuroradiol. 28, 92–96.

Yasargil, M.G., Ture, U., Yasargil, D.C., 2004. Impact of temporal lobe surgery. J. Neurosurg. 101, 725–738.

Yogarajah, M., Focke, N.K., Bonelli, S., Cercignani, M., Acheson, J., Parker, G.J., Alexander, D.C., McEvoy, A.W., Symms, M.R., Koepp, M.J., Duncan, J.S., 2009. Defining Meyer's loop-temporal lobe resections, visual field deficits and diffusion tensor tractography. Brain 132, 1656–1668.

Yogarajah, M., Focke, N.K., Bonelli, S.B., Thompson, P., Vollmar, C., McEvoy, A.W., Alexander, D.C., Symms, M.R., Koepp, M.J., Duncan, J.S., 2010. The structural plasticity of white matter networks following anterior temporal lobe resection. Brain 133, 2348–2364.

Yoshino, M., Kin, T., Ito, A., Saito, T., Nakagawa, D., Kamada, K., Mori, H., Kunimatsu, A., Nakatomi, H., Oyama, H., Saito, N., 2015. Diffusion tensor tractography of normal facial and vestibulocochlear nerves. Int. J. Comput. Assist. Radiol. Surg. 10, 383–392.

Yoshino, M., Abhinav, K., Yeh, F.C., Panesar, S., Fernandes, D., Pathak, S., Gardner, P.A., Fernandez-Miranda, J.C., 2016. Visualization of cranial nerves using high-definition fiber tractography. Neurosurgery 79, 146–165.

Zhang, W., Olivi, A., Hertig, S.J., van Zijl, P., Mori, S., 2008. Automated fiber tracking of human brain white matter using diffusion tensor imaging. NeuroImage 42, 771–777.

Zhang, Y., Chen, Y., Zou, Y., Zhang, W., Zhang, R., Liu, X., Lv, Z., Yang, K., Hu, X., Xiao, C., Liu, W., Liu, H., 2013. Facial nerve preservation with preoperative identification and intraoperative monitoring in large vestibular schwannoma surgery. Acta Neurochir. 155, 1857–1862.