



Functional and structural differences in the hippocampus associated with memory deficits in adult survivors of acute lymphoblastic leukemia

Citation

Monje, Michelle, Moriah E. Thomason, Laura Rigolo, Yalin Wang, Deborah P. Waber, Stephen E. Sallan, and Alexandra J. Golby. 2013. Functional and Structural Differences in the Hippocampus Associated with Memory Deficits in Adult Survivors of Acute Lymphoblastic Leukemia. *Pediatric Blood & Cancer* 60(2): 293–300. doi:10.1002/pbc.24263

Published Version

doi:10.1002/pbc.24263

Permanent link

<http://nrs.harvard.edu/urn-3:HUL.InstRepos:34172036>

Terms of Use

This article was downloaded from Harvard University's DASH repository, and is made available under the terms and conditions applicable to Other Posted Material, as set forth at <http://nrs.harvard.edu/urn-3:HUL.InstRepos:dash.current.terms-of-use#LAA>

Share Your Story

The Harvard community has made this article openly available.
Please share how this access benefits you. [Submit a story](#).

[Accessibility](#)



Published in final edited form as:

Pediatr Blood Cancer. 2013 February ; 60(2): 293–300. doi:10.1002/pbc.24263.

Functional and Structural Differences in the Hippocampus Associated with Memory Deficits in Adult Survivors of Acute Lymphoblastic Leukemia

Michelle Monje, MD, PhD^{*,1}, Moriah E. Thomason, PhD^{2,3,*}, Laura Rigolo, B.S.⁴, Yalin Wang, PhD⁵, Deborah P. Waber, PhD⁷, Stephen E. Sallan, MD⁶, and Alexandra J. Golby, MD⁴

²Merrill Palmer Skillman Institute for Child and Family Development, Wayne State University, Detroit, MI

³Department of Pediatrics, Wayne State University, Detroit, MI

⁴Department of Neurosurgery and Department of Radiology, Brigham and Women's Hospital, Harvard Medical School, Boston, MA

⁵School of Computing, Informatics, and Decision Systems engineering, Arizona State University, Arizona

⁶Department of Pediatric Oncology, Dana Farber Cancer Institute, Boston, MA

⁷Department of Psychiatry, Children's Hospital Boston, Boston, MA

Abstract

Background—Radiation and chemotherapy targeted to the central nervous system can cause cognitive impairment, including impaired memory. These memory impairments may be referable to damage to hippocampal structures resulting from central nervous system (CNS) treatment.

Procedure—In the present study, we explored episodic memory and its neuroimaging correlates in 10 adult survivors of childhood acute lymphoblastic leukemia (ALL) treated with cranial radiation therapy and both systemic and intrathecal chemotherapy and 10 controls matched for age and sex, using a subsequent memory paradigm after episodic encoding of visual scenes.

Results—We report behavioral, structural and functional changes in the brains of the adult survivors. They demonstrated poorer recognition memory, hippocampal atrophy and altered blood oxygenation level-dependent (BOLD) signal in the hippocampus. Whole brain statistical map analysis revealed increased BOLD signal/activation in several brain regions during unsuccessful encoding in ALL survivors, potentially reflecting ineffective neural recruitment. Individual differences in memory performance in ALL participants were related to magnitude of BOLD response in regions associated with successful encoding.

Conclusions—Taken together, these findings describe long term neuroimaging correlates of childhood exposure to CNS-targeted cancer therapies, suggesting enduring damage to episodic memory systems.

Corresponding author: Michelle Monje, MD, PhD, Lorry I. Lokey Stem Cell Building, 265 Campus Drive, G3077, Stanford, CA 94305-5461, (650) 736-0885 (Ph), mmonje@stanford.edu.

*these authors contributed equally to this work

¹Present address: Department of Neurology, Stanford University, Stanford, CA

Conflict of Interest Statement: The authors have no conflicts of interest to report.

Keywords

ALL; memory; late effects of cancer therapy; hippocampus; fMRI

Introduction

Cancer therapy targeted to the central nervous system results in cognitive deficits in children [1, 2] [3] [4] and adults [5] [6]. Although general decline in IQ is a frequent sequela, survivors can also experience more specific deficits in attention, executive function, speed of information processing [7] and memory [3] [8] [4]. Because of the central role memory plays in daily function and academic or occupational success, memory dysfunction is a particularly debilitating symptom.

Memory deficits after cranial irradiation and chemotherapy are complex, and include deficits in visual [4], [7], verbal [8] [3] and spatial memory [8]. Memory is broadly divided in two major categories, implicit or procedural memory (e.g. how to ride a bicycle) and explicit or declarative memory. Declarative memory is further subdivided into memory for facts (semantic memory) and memory for events (episodic memory). Declarative memory function is itself a complex system, and involves encoding of new information as well as the organization, attention to and retrieval of that information. The hippocampi, located in the medial temporal lobes (MTL), work in concert with distributed cortical structures to orchestrate declarative memory function. Some reports of hippocampal injury in children suggest that episodic memory function is particularly dependent on hippocampal integrity [9]. In brief, the hippocampus is central to encoding new declarative memories [10] [11], while cortical memory systems, highly dependent on the integrity of subcortical white matter connections and including important frontal lobe areas, subserve working memory (the conscious manipulation of information on short time scales necessary for reasoning and learning). Both memory encoding and working memory are affected in children treated for CNS cancer [12].

The incidence and severity of cognitive dysfunction varies amongst populations of cancer patients. Exposure to cranial radiation therapy, radiation dose [13] [14], female sex [15] [16] and age at time of treatment [17] are important variables that contribute to the severity of the cognitive deficits. Younger children and older adults experience more devastating cognitive sequelae from radiation. In adults, the severity of cognitive dysfunction also depends on the radiation dose delivered to the medial temporal lobes [18]. Temporal lobe radiation dose is similarly believed to be important in the cognitive outcome of children. Accordingly, improved conformal radiotherapy techniques seek to limit the dose of radiation to the medial temporal lobes incurred during posterior fossa radiation [19].

Recent work in both animal models and in post-mortem human subjects has helped to clarify that the etiology of radiation-induced memory dysfunction does include damage to the process of neurogenesis (making new neurons) in the hippocampus [20] [21] [22]. Neurogenesis is believed to be important to normal hippocampal function [23]. Cancer treatment-induced inhibition of hippocampal neurogenesis may contribute significantly to dysfunction of the hippocampus and the broader neural network involved in episodic memory function. Although the cellular basis for cancer treatment-induced memory dysfunction has become more clear, the imaging correlates remain to be defined.

In the present study, we sought to elucidate the neural correlates of episodic memory dysfunction in adult survivors of childhood cancer who received therapy directed at the central nervous system. Cognitive deficits are well-documented in children treated for brain tumors and children treated for acute lymphoblastic leukemia (ALL). ALL has a propensity

to spread to the CNS and thus treatment includes prophylactic CNS therapy. The latter is associated with frequent and well-documented long-term cognitive sequelae [1, 24–29]. Historically, CNS treatment included whole brain radiation and intrathecal chemotherapy; however, because of the long-term cognitive sequelae of cranial radiation, current CNS treatments omit radiation for a large majority of children with ALL and use both intrathecal and systemic chemotherapy only. Today, adult survivors of childhood ALL who are in their late 20's to early 40's are typically recipients of cranial radiation. In many ways, they represent an ideal population in which to study the effects of CNS radiation and chemotherapy on long-term episodic memory function. Unlike brain tumor survivors, this population typically does not have focal brain lesions from tumor or surgery, which could confound studies of memory function.

One of the prevailing methods for characterizing the neural foundations of episodic encoding in humans is event-related functional magnetic resonance imaging (fMRI) during a subsequent memory paradigm [30] [31]. In the subsequent memory paradigm, neural responses are acquired during event processing (e.g., visual scene presentations), and then memory is probed by asking participants to classify events as seen or not seen, and then comparing neural responses during presentations that are remembered or not remembered. Subsequent memory event-related fMRI is ideally suited for relating encoding-stage neural activity with the mnemonic fate of an event. This method has revealed that the neural architecture of episodic encoding in humans includes not only the MTL, but also critical contributions from dorsal and ventral regions in lateral prefrontal cortex (PFC) [32], and posterior regions of the lateral parietal cortex [33]. This method has also been useful for identifying regions of the brain in which activity is contrary to encoding success (regions where greater activity corresponds to forgetting), such as inferior parietal cortex, the posterior cingulate cortex, and medial parietal cortex [34].

Here we examine the neural basis of encoding events in adult survivors of childhood ALL. We examined integrated aspects of brain structure, brain function and behavioral ability to illuminate systems-level neurobiological differences that underscore central cognitive deficits observed in adults previously treated with cranial radiation and chemotherapy. We hypothesize that adult survivors of ALL will show impaired episodic memory ability, reduced hippocampal volume, and altered functional neural system engagement during encoding that may underlie the memory deficits such patients experience.

Methods

Participants

Ten adult survivors of childhood ALL who received cranial radiation and intrathecal methotrexate (as well as two years of systemic chemotherapy) and 10 age-matched control (CTL) participants participated in this study. Participants were recruited from Dana Farber Cancer Institute (DFCI) database and through website postings. All participants: were 1) between the ages of 22 and 40 years; 2) treated for ALL at DFCI in the 1980s or were healthy volunteers; and 3) had no physical limitations that prohibited them from undergoing an MRI examination.

The ALL participants (Supplemental Table I) had received cranial radiation (18–38 Gy) on DFCI treatment protocols 81-01, 85-01 or 87-01 [35]; none of the control participants reported a history of brain injury or radiation therapy. Informed consent was obtained from all participants, who were paid \$25 per hour for their participation in the study. All aspects of this study complied with the ethical standards for treatment of human participants from the American Psychiatric Association.

All participants completed a structural and functional MRI session, after which they received a “surprise” recall test outside of the scanner as part of the research protocol. Please refer to Supplemental Methods for additional methodological details.

Results

Participant demographics

Demographic characteristics and performance variables of the ALL and control participants are presented in Supplemental Table II. The two groups of participants did not differ significantly in age, $t(18) = 0.11$, or gender composition, $\chi^2 = 0$, $ps > 0.9$.

Behavioral measures

Independent sample t-tests of test recognition memory variables identified significant areas of difference between ALL and control participants. ALL participants had lower overall recognition memory accuracy, $t(18) = 2.23$, $p = 0.039$, and higher false alarm rates, $t(18) = 2.63$, $p = 0.017$. The groups did not differ with respect to hit rates, $t(18) = 0.99$, $p > 0.3$, but there was a trend toward ALL patients having lower d' scores, $t(18) = 1.94$, $p = .068$, than control participants. Means and standard deviation values for recognition memory variables are summarized in Supplemental Table II.

Multivariate analyses for accuracy and latency scores obtained while performing judgment tasks inside the scanner were run separately. These revealed that accuracy was not significantly different during the encoding/scan runs between ALL and control groups, $p > 0.1$. However, the ALL group was significantly faster at making judgments across the two trial types, $F(1,18) = 5.8$, $p < 0.05$.

Extent of positive subsequent memory effects across groups

We examined areas of increased neural response to scenes later remembered contrasted against those forgotten, and found that no components of the subsequent memory network were positively associated with item recall memory (across both groups) at $p < 0.001$. At a threshold of $p < 0.005$, cluster minimum extent = 10, however, we observed significant correlations in four areas: 185 voxels in the left fusiform gyrus (FG; BA37/20: $-36, -55, -12$, z score = 3.51), 13 voxels in the right hippocampal formation (BA27: $28, -35, -2$, z = 2.76), and two clusters of 61 and 11 voxels in the middle (BA19: $-36, -77, 9$, z score = 2.72) and inferior ($-34, -70, -5$, z score = 2.98) occipital cortices, respectively. A statistical map summarizing these results is presented in Figure 2. Coordinates are reported based on the convention specified by the Talairach and Tournoux Atlas [36]

Extent of negative subsequent memory effects across groups

Regions negatively correlated with subsequent memory (i.e. more active for items later forgotten) included orbital and middle frontal, cingulate, precuneus and insula regions, as well as ventral parietal regions previously observed in subsequent forgetting contrasts (reviewed in [33]), including areas of the supramarginal gyrus (SMG) and temporoparietal junction (TPJ) (Figure 2 and Supplemental Table III).

Subsequent memory differences between groups

Significant group differences were observed in precuneus (BA7; $-2, -54-58$), claustrum ($-34, 2, 6$), postcentral gyrus (BA3; $-46, -22, 42$), inferior parietal lobe (BA40; $-60, -42, 26$), precentral gyrus (BA4; $26, -28, 56$), and MFG (BA6; $30, 8, 48$) regions; $p < 0.001$, cluster minimum extent (k min) = 10 voxels. Region of interest analysis in cluster peaks comprised of the 9 maximally significant voxels revealed that group differences resulted from strong

positive signal modulation during encoding of items that were later forgotten in patients only. The differences between groups in these peak areas of difference are plotted in Figure 3, and the picture that emerges is that patients have high positive signal modulation in these areas for items later forgotten, and concomitant reduction in positive signal in these areas relative to control participants during trials that are later remembered. Therefore, these are regions that are not positively correlated with remembering in either group, and only in patients are they more active for items later forgotten.

Novelty effects between groups

In contrast to the comparison between groups for subsequently remembered vs forgotten trials, we did not observe noteworthy differences between groups in neural activation for novel versus repeatedly-presented stimuli. Whereas the subsequent memory contrast revealed group differences across 23 clusters with extent minimum > 25 voxels (Supplemental Table III), the repeat vs novel comparison only yielded 1 cluster with extent greater than 25 voxels at $p < 0.001$. That cluster was comprised of 26 voxels in the culmen of the anterior cerebellum with a peak at $-18, -46 -23$ (TAL). The between group effect observed in that area was that ALL participants had more activation in this region during novel image presentation than during repeat, and in comparison, the CTL group did not activate this area differently between these stimulus encoding trial types.

Effect of recall and discriminability (d') on encoding related activation

In our patient group (ALL), we examined the relationship of both recall (% accuracy) and discriminability (d'), to neural subsequent memory effects. In neural regions that were positively related to subsequent memory (Supplemental Table III, remembered > forgotten) there was a significant positive relationship between BOLD magnitude during trials later remembered and % accuracy, $r(10) = 0.79$, $p = 0.006$, and between BOLD magnitude during trials later remembered and d' $r(10) = 0.74$, $p = 0.01$. Therefore, in patients, greater item recall and discriminability were associated with more response in these regions during encoding of items later remembered.

Differences between groups in memory-related hippocampal effects

Between group memory-related BOLD effects were observed in bilateral hippocampi, with peaks observed at MNI 30, $-16, -14$ and $-30, -20, -6$; both $F > 12$, $p < 0.05$ FWE corrected. Follow up ROI analysis using beta images to assess these group difference hippocampal peaks revealed that BOLD activity did not differ between groups within hippocampal regions for trials that were later remembered; however, groups differed significantly in hippocampal regions for trials later forgotten. The pattern that was observed between groups was a tendency for ALL participants to show higher levels of activity in hippocampal regions, compared to the CTR comparison group during trials that would later be forgotten (Figure 4).

Difference between groups in hippocampal structure

Although samples sizes were small, significantly reduced volume was detected in ALL participants, mainly on the right side. The permutation-based overall significance of the atrophy maps, corrected for multiple comparisons, were $p=0.04$ for the right hippocampus and $p=0.10$ for the left hippocampus, respectively. Figure 5A provides a visual representation of where the significant group effects were localized for each of the hippocampi. Figure 5B is a plot of the cumulative distribution function of the p-values, where observed values for the contrast of ALL patients versus controls is plotted against the expected p-values, under the null hypothesis of no atrophy in the patient group. For null distributions, the cumulative distribution of p-values is expected to fall approximately along

the line (represented by the dotted line); large deviations from that curve are associated with significant signal, and greater effect sizes represented by larger deviations (the theory of false discovery rates gives formulae for thresholds that control false positives at a known rate). As such, we conclude that our work successfully detected atrophic areas specific to the ALL group.

Discussion

The present study demonstrates structural, functional and behavioral differences in adult survivors of childhood ALL compared to age and sex-matched controls. The ALL survivors exhibited poor recognition memory performance when viewing visual scenes, as well as high false alarm rates, compared to the control group (Supplemental Table II). Whole brain statistical analysis revealed increased BOLD signal/activation in several brain regions during unsuccessful encoding in the ALL participants (Figure 2, 3). Such activation of diffuse networks during unsuccessful cognitive tasks has been described in disease states, and may indicate ineffective recruitment of compensatory mechanisms. [37, 38] [39] Our findings complement those of Robinson et al., who describe increased BOLD activation in dorsolateral and ventrolateral prefrontal cortex and in the dorsal and anterior cingulate cortex during a working memory task in pediatric ALL survivors 4– 12 years after therapy [40]. Notably, our results indicate hippocampal dysfunction during episodic memory encoding 20 – 30 years after therapy. This distributed pattern of ineffective activation may create “noise” that interferes with the signals required for successful episodic memory encoding.

The hippocampus is central to episodic memory encoding[41],[42] and is exquisitely vulnerable to chemotherapy and radiotherapy [20] [21, 22, 43]. In contrast to control participants who had greater hippocampal response during effective encoding trials relative to unsuccessful encoding trials, ALL participants demonstrated the reverse effect; ALL participants had increased signal in hippocampal regions for unsuccessfully encoded memories (Figure 4). This is consistent with findings of increased hippocampal activation in subjects with mild cognitive impairment (MCI) [37, 38] and supports the idea of compensatory activation in faltering neural systems. BOLD patterns may evolve over time or depend on the severity of hippocampal dysfunction. We know from the dementia literature that increased medial temporal lobe BOLD signal in MCI becomes decreased BOLD signal during encoding of novel visual information when the severity of disease progresses to Alzheimer’s Disease [38] [44]. This reduction in MTL activation during the encoding of novel visual scenes has also been shown to correlate with the severity of dementia as measured by mini-mental status exam (MMSE) scores [44]. Future work may reveal a similar pattern in survivors of central nervous system cancer therapy with more severe cognitive deficits.

Cancer therapies targeted to the CNS, including cranial radiation and systemic and intrathecal chemotherapy, result in a high rate of neurocognitive sequelae. Late-occurring neurocognitive deficits include memory encoding and learning, executive functions such as working memory, attention, information processing speed and visuospatial skill [45] [46, 47]. These deficits localize neuroanatomically primarily in the hippocampus in the medial temporal lobes and the frontal lobes. The proposed cellular basis for this constellation of neurocognitive symptoms involves radiation and chemotherapy-induced damage to susceptible neural precursor cell populations, specifically hippocampal neural stem/precursor cells that contribute to ongoing hippocampal neurogenesis and oligodendrocyte precursor cells that contribute to establishment and maintenance of white matter myelination [20] [21] [22] [48]. Oligodendrocyte precursor cell function is especially important in the frontal lobes, where myelination is not complete until the third decade of life [49]. A post-

mortem analysis following treatment for CNS malignancies, including primary brain tumors and leukemia, demonstrated that hippocampal neurogenesis was nearly absent in both children and adults [22]. As new neurons fail to be added to the dentate gyrus of the hippocampus from the time of radiation exposure onwards, a subtle decrease in hippocampal volume would be expected. As anticipated, structural analysis of the hippocampi in adult survivors of childhood leukemia reveals significant hippocampal atrophy, particularly affecting the right hippocampus (Figure 5). The reason for this laterality is unknown. The finding of hippocampal atrophy in adult survivors of childhood ALL is consistent with hippocampal atrophy found in long-term survivors of medulloblastoma (treated with radiation therapy)[50].

ALL survivors, including those treated on the same protocols as the subjects studied here, exhibit memory dysfunction that depends, in part, on cranial radiation exposure [15]. Although more recent ALL protocols have eliminated or minimized the dose of cranial radiation, this study examined subjects treated in the 1980s with 18–28 Gy radiotherapy and chemotherapy in order to better understand the cognitive sequelae of individuals currently grappling with the late effects of older treatment regimens for ALL, as well as to probe neuroimaging correlates of episodic memory dysfunction that follows CNS-targeted therapy in general. The results from this study lend insight to episodic memory dysfunction in populations of patients who receive similar therapy, such as children with medulloblastoma and several other types of brain tumors. Taken together, these findings provide a functional and structural basis for some of the cognitive symptoms experienced by survivors of childhood leukemia.

Supplementary Material

Refer to Web version on PubMed Central for supplementary material.

Acknowledgments

The authors gratefully acknowledge the support of the Hagerty Foundation (M.M.), the National Institute of Mental Health (MH081583, M.E.T.) and a NARSAD Young Investigator Award (MET.) The authors thank Rebecca F. Johnson for her assistance with hippocampal volume tracing.

References

1. Meadows AT, et al. Declines in IQ scores and cognitive dysfunctions in children with acute lymphocytic leukaemia treated with cranial irradiation. *Lancet*. Nov 7.1981 2:1015–8. [PubMed: 6118478]
2. Copeland DR, et al. Neuropsychological sequelae of childhood cancer in long-term survivors. *Pediatrics*. Apr.1985 75:745–53. [PubMed: 3838584]
3. Packer RJ, et al. A prospective study of cognitive function in children receiving whole-brain radiotherapy and chemotherapy: 2-year results. *J Neurosurg*. May.1989 70:707–13. [PubMed: 2709111]
4. Spiegler BJ, et al. Change in neurocognitive functioning after treatment with cranial radiation in childhood. *J Clin Oncol*. Feb 15.2004 22:706–13. [PubMed: 14966095]
5. Crossen JR, et al. Neurobehavioral sequelae of cranial irradiation in adults: a review of radiation-induced encephalopathy. *J Clin Oncol*. Mar.1994 12:627–42. [PubMed: 8120563]
6. Surma-aho O, et al. Adverse long-term effects of brain radiotherapy in adult low-grade glioma patients. *Neurology*. May 22.2001 56:1285–90. [PubMed: 11376174]
7. Mabbott DJ, et al. Longitudinal evaluation of neurocognitive function after treatment for central nervous system germ cell tumors in childhood. *Cancer*. May 11.2011
8. Copeland DR, et al. Neurocognitive development of children after a cerebellar tumor in infancy: A longitudinal study. *J Clin Oncol*. Nov.1999 17:3476–86. [PubMed: 10550145]

9. Vargha-Khadem F, et al. Differential effects of early hippocampal pathology on episodic and semantic memory. *Science*. Jul 18.1997 277:376–80. [PubMed: 9219696]
10. Fernandez G, et al. Successful verbal encoding into episodic memory engages the posterior hippocampus: a parametrically analyzed functional magnetic resonance imaging study. *J Neurosci*. Mar 1.1998 18:1841–7. [PubMed: 9465008]
11. Stark CE, Squire LR. Simple and associative recognition memory in the hippocampal region. *Learn Mem*. Jul-Aug;2001 8:190–7. [PubMed: 11533222]
12. Nagel BJ, et al. Early patterns of verbal memory impairment in children treated for medulloblastoma. *Neuropsychology*. Jan.2006 20:105–12. [PubMed: 16460226]
13. Packer RJ, et al. Treatment of children with medulloblastomas with reduced-dose craniospinal radiation therapy and adjuvant chemotherapy: A Children’s Cancer Group Study. *J Clin Oncol*. Jul.1999 17:2127–36. [PubMed: 10561268]
14. Grill J, et al. Long-term intellectual outcome in children with posterior fossa tumors according to radiation doses and volumes. *Int J Radiat Oncol Biol Phys*. Aug 1.1999 45:137–45. [PubMed: 10477017]
15. Waber DP, et al. The relationship of sex and treatment modality to neuropsychologic outcome in childhood acute lymphoblastic leukemia. *J Clin Oncol*. May.1992 10:810–7. [PubMed: 1569453]
16. Palmer SL, et al. Predicting intellectual outcome among children treated with 35–40 Gy craniospinal irradiation for medulloblastoma. *Neuropsychology*. Oct.2003 17:548–55. [PubMed: 14599268]
17. Mulhern RK, et al. Late neurocognitive sequelae in survivors of brain tumours in childhood. *Lancet Oncol*. Jul.2004 5:399–408. [PubMed: 15231246]
18. Abayomi OK. Pathogenesis of cognitive decline following therapeutic irradiation for head and neck tumors. *Acta Oncol*. 2002; 41:346–51. [PubMed: 12234025]
19. Merchant TE, et al. Modeling radiation dosimetry to predict cognitive outcomes in pediatric patients with CNS embryonal tumors including medulloblastoma. *Int J Radiat Oncol Biol Phys*. May 1.2006 65:210–21. [PubMed: 16472938]
20. Monje ML, et al. Irradiation induces neural precursor-cell dysfunction. *Nat Med*. Sep.2002 8:955–62. [PubMed: 12161748]
21. Monje ML, et al. Inflammatory blockade restores adult hippocampal neurogenesis. *Science*. Dec 5.2003 302:1760–5. [PubMed: 14615545]
22. Monje ML, et al. Impaired human hippocampal neurogenesis after treatment for central nervous system malignancies. *Ann Neurol*. Nov.2007 62:515–20. [PubMed: 17786983]
23. Zhao C, et al. Mechanisms and functional implications of adult neurogenesis. *Cell*. Feb 22.2008 132:645–60. [PubMed: 18295581]
24. Inati A, et al. Efficacy and morbidity of central nervous system “prophylaxis” in childhood acute lymphoblastic leukemia: eight years’ experience with cranial irradiation and intrathecal methotrexate. *Blood*. Feb.1983 61:297–303. [PubMed: 6571787]
25. Bleyer WA, Poplack DG. Prophylaxis and treatment of leukemia in the central nervous system and other sanctuaries. *Semin Oncol*. Jun.1985 12:131–48. [PubMed: 3892694]
26. Waber DP, et al. Late effects of central nervous system treatment of acute lymphoblastic leukemia in childhood are sex-dependent. *Dev Med Child Neurol*. Mar.1990 32:238–48. [PubMed: 2311827]
27. Moore IM, et al. Cognitive function in children with leukemia. Effect of radiation dose and time since irradiation. *Cancer*. Nov 1.1991 68:1913–7. [PubMed: 1913542]
28. Raymond-Speden E, et al. Intellectual, neuropsychological, and academic functioning in long-term survivors of leukemia. *J Pediatr Psychol*. Mar.2000 25:59–68. [PubMed: 10820944]
29. Moleski M. Neuropsychological, neuroanatomical, and neurophysiological consequences of CNS chemotherapy for acute lymphoblastic leukemia. *Arch Clin Neuropsychol*. Oct.2000 15:603–30. [PubMed: 14590198]
30. Brewer JB, et al. Making memories: brain activity that predicts how well visual experience will be remembered. *Science*. Aug 21.1998 281:1185–7. [PubMed: 9712581]

31. Paller KA, Wagner AD. Observing the transformation of experience into memory. *Trends Cogn Sci.* Feb 1.2002 6:93–102. [PubMed: 15866193]
32. Wagner AD, et al. Building memories: remembering and forgetting of verbal experiences as predicted by brain activity. *Science.* Aug 21.1998 281:1188–91. [PubMed: 9712582]
33. Uncapher MR, Wagner AD. Posterior parietal cortex and episodic encoding: insights from fMRI subsequent memory effects and dual-attention theory. *Neurobiol Learn Mem.* Feb.2009 91:139–54. [PubMed: 19028591]
34. Otten LJ, Rugg MD. Task-dependency of the neural correlates of episodic encoding as measured by fMRI. *Cereb Cortex.* Dec.2001 11:1150–60. [PubMed: 11709486]
35. Silverman LB, et al. Results of Dana-Farber Cancer Institute Consortium protocols for children with newly diagnosed acute lymphoblastic leukemia (1981–1995). *Leukemia.* Dec.2000 14:2247–56. [PubMed: 11187916]
36. Tournoux, JTaP. Co-Planar Stereotactic Atlas of the Human Brain. 1987.
37. Dickerson BC, et al. Medial temporal lobe function and structure in mild cognitive impairment. *Ann Neurol.* Jul.2004 56:27–35. [PubMed: 15236399]
38. Dickerson BC, et al. Increased hippocampal activation in mild cognitive impairment compared to normal aging and AD. *Neurology.* Aug 9.2005 65:404–11. [PubMed: 16087905]
39. Lu LH, et al. Effects of prenatal methamphetamine exposure on verbal memory revealed with functional magnetic resonance imaging. *J Dev Behav Pediatr.* Jun.2009 30:185–92. [PubMed: 19525715]
40. Robinson KE, et al. Working memory in survivors of childhood acute lymphocytic leukemia: functional neuroimaging analyses. *Pediatr Blood Cancer.* Apr.2010 54:585–90. [PubMed: 19953649]
41. Scoville WB, Milner B. Loss of recent memory after bilateral hippocampal lesions. *J Neurol Neurosurg Psychiatry.* Feb.1957 20:11–21. [PubMed: 13406589]
42. Squire LR, Zola-Morgan S. The medial temporal lobe memory system. *Science.* Sep 20.1991 253:1380–6. [PubMed: 1896849]
43. Seigers R, et al. Long-lasting suppression of hippocampal cell proliferation and impaired cognitive performance by methotrexate in the rat. *Behav Brain Res.* Jan 25.2008 186:168–75. [PubMed: 17854921]
44. Golby A, et al. Memory encoding in Alzheimer's disease: an fMRI study of explicit and implicit memory. *Brain.* Apr.2005 128:773–87. [PubMed: 15705615]
45. Monje M. Cranial radiation therapy and damage to hippocampal neurogenesis. *Dev Disabil Res Rev.* 2008; 14:238–42. [PubMed: 18924155]
46. Dietrich J, et al. Clinical patterns and biological correlates of cognitive dysfunction associated with cancer therapy. *Oncologist.* Dec.2008 13:1285–95. [PubMed: 19019972]
47. Campbell LK, et al. A meta-analysis of the neurocognitive sequelae of treatment for childhood acute lymphocytic leukemia. *Pediatr Blood Cancer.* Jul.2007 49:65–73. [PubMed: 16628558]
48. Dietrich J, et al. CNS progenitor cells and oligodendrocytes are targets of chemotherapeutic agents in vitro and in vivo. *J Biol.* 2006; 5:22. [PubMed: 17125495]
49. Yakovlev, PI. The myelogenetic cycles of regional maturation of the brain. In: Minkowski, A., editor. *Regional Development of the Brain in Early Life.* Oxford: Blackwell Scientific Publications; 1967. p. 3-70.
50. Nagel BJ, et al. Abnormal hippocampal development in children with medulloblastoma treated with risk-adapted irradiation. *AJNR Am J Neuroradiol.* Oct.2004 25:1575–82. [PubMed: 15502141]

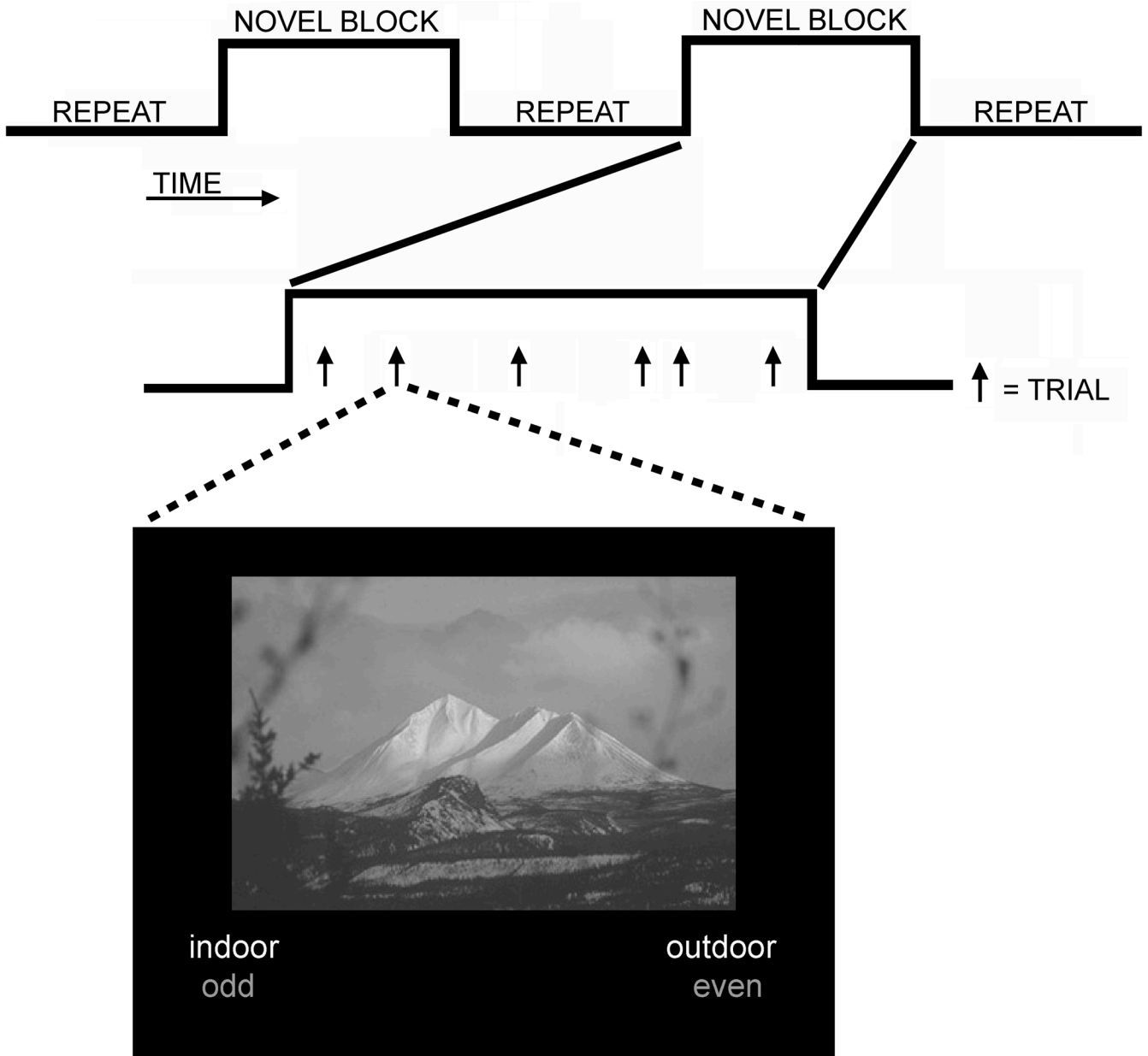


Figure 1. Schematic of the mixed event-related/blocked design
 Six blocks of repeated scenes were interspersed with 6 blocks of novel scenes within each of three encoding tasks runs. Within task blocks individual scene trials (arrows) are presented with different intervals between them, during which participants performed digit judgments.

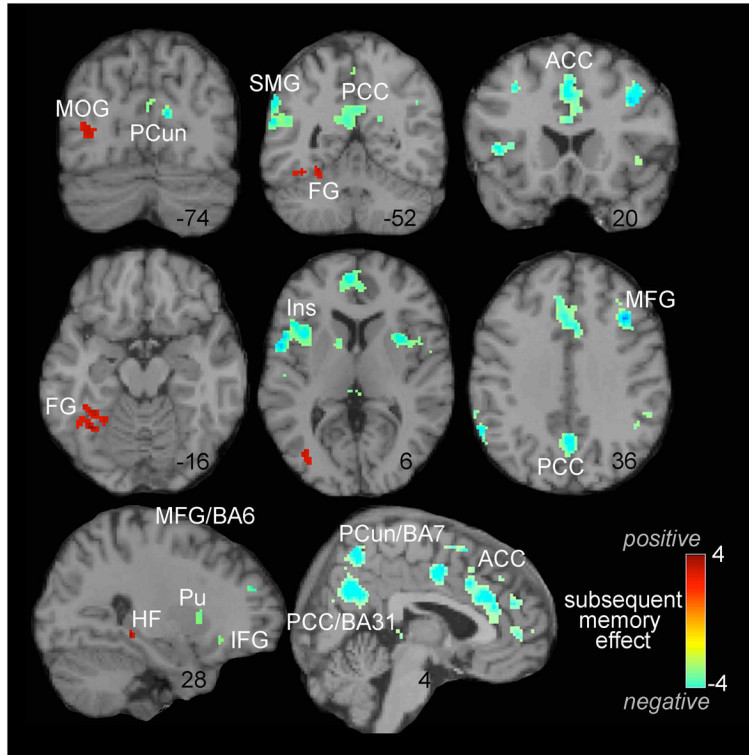


Figure 2. Subsequent memory effects on neural encoding BOLD response across groups
 Positive values (red) reflect regions that were more active during the encoding of pictures that were subsequently remembered than during the encoding of pictures that were subsequently forgotten, whereas negative values (teal) reflect the reverse (more active for items later forgotten). Color scale reflects t-statistic; images are thresholded at $p < 0.005$, cluster minimum extent = 10 voxels. Abbreviations: MOG, middle occipital gyrus; PCun, precuneus; SMG, supramarginal gyrus; PCC, posterior cingulate gyrus; FG, fusiform gyrus; ACC, anterior cingulate gyrus; Ins, insula; MFG, middle frontal gyrus; HC, hippocampal formation; Pu, putamen; IFG, inferior frontal gyrus; BA, brodmann's area.

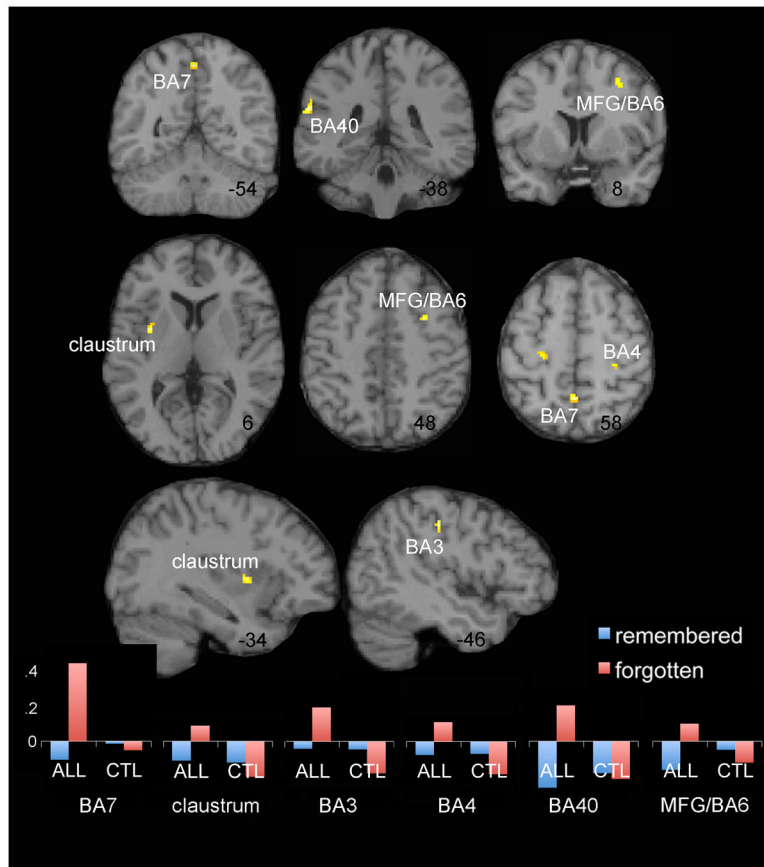


Figure 3. Group differences in subsequent memory encoding effects

Areas of significant group main effect while modeling performance (d') as nuisance covariate are shown as yellow clusters projected on a T1 anatomical reference image. Region of interest analysis was performed on resulting peaks, and the mean contributing beta-weights for each of the remembered and forgotten trials across scans are plotted as bar graphs. Graph values reflect BOLD signal change. Patients (ALL; shown on the left of each area bar graph) and control participants (CTL; right side of each bar graph) do not appear to differ greatly in these areas for encoding of trials later remembered (blue bars); however, the difference between groups across regions appears to result from neural response differences in these regions during the encoding of items that were later forgotten (red bars). ALL participants appear to activate these areas more during encoding, but this activity is not aiding performance because they are not effectively encoding. Neural differences are shown for $p < 0.001$, cluster minimum extent = 10 voxels. Abbreviations: MFG, middle frontal gyrus; BA, brodmann's area.

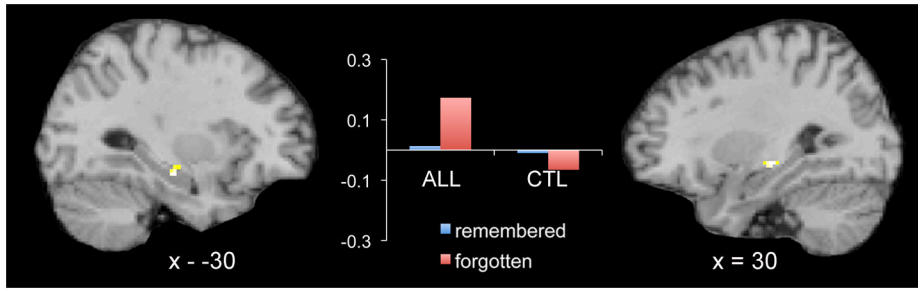


Figure 4. Group differences in memory-related hippocampal effects

Areas of significant group main effect in anatomically defined hippocampal volume of interest analysis are shown as yellow clusters projected on a T1 anatomical reference image. Region of interest analysis was performed on voxels within bilateral hippocampi that demonstrated a significant main effect of group for subsequent memory effects (remember vs. forgotten) at $p < 0.01$, cluster minimum extent = 5. Group means within the hippocampal clusters are plotted for each of the remembered and forgotten trials across scans in the center bar graph. Graph values reflect BOLD signal change. Patients (ALL; shown on the left of each area bar graph) and control participants (CTL; right side of each bar graph) do not appear to differ greatly in these areas for encoding of trials later remembered (blue bars); however, the difference between groups across regions appears to result from neural response differences in these regions during the encoding of items that were later forgotten (red bars).

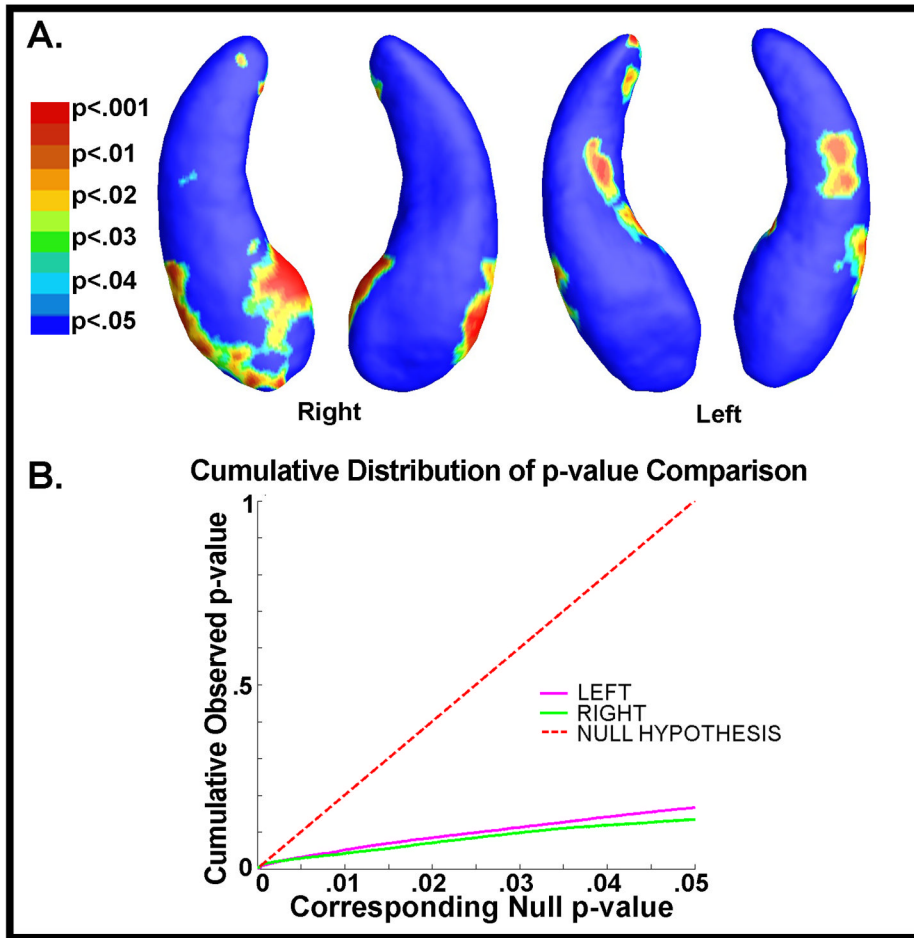


Figure 5. Structural changes in the hippocampus

(A) Statistical p-map shape difference between ALL group (N=10) and normal control group (N=10) on hippocampal surfaces. The non-blue color regions have probabilities less than or equal to 0.05. (B) The cumulative distribution of p-values versus the corresponding cumulative p-value that would be expected from a null distribution that there is not greater atrophy in the ALL group and control group. In False Discovery Rate (FDR) methods, any cumulative distribution plot that rises steeply is a sign of a significant signal being detected, with curves that rise faster denoting higher effect sizes. The steep rise of the cumulative plot relative to p-values that would be expected by chance can be used to illustrate the confidence level of the overall statistical test.

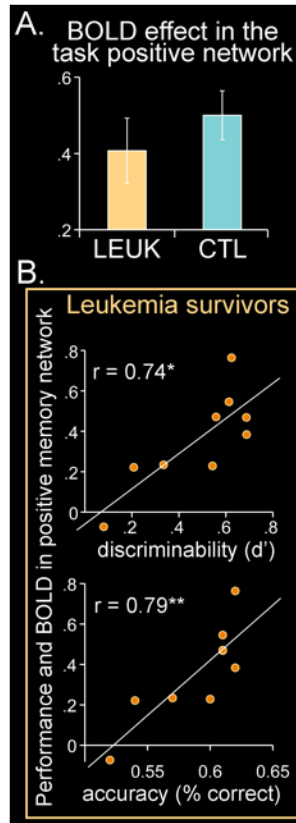


Figure 6. Magnitude of encoding related activation in the positive memory network and association with behavior

We examined average BOLD effect magnitude in the positive memory network (regions that across all participants were associated with later remembered trials), and associated BOLD with performance at the individual subject level. Panel A shows groups did not differ in BOLD percent (%) signal change, $t(20) = 0.87$, $p = 0.4$. However, within the ALL participants, there was a significant positive association between BOLD % signal change in these areas during encoding and performance (Panel B). BOLD percent (%) signal change is plotted on all vertical chart axes. Positive memory network includes areas listed in Supplemental Table III for remembered > forgotten.