



# DIGITAL ACCESS TO SCHOLARSHIP AT HARVARD

## Invasive follicular variant of papillary thyroid cancer harboring the NRAS mutation Q61K and presenting with bone metastasis—A case report

The Harvard community has made this article openly available.  
[Please share](#) how this access benefits you. Your story matters.

Citation	Mehrzad, Raman, Michiya Nishino, Carmelo Nucera, Dora Dias-Santagata, James V. Hennessey, and Per-Olof Hasselgren. 2017. "Invasive follicular variant of papillary thyroid cancer harboring the NRAS mutation Q61K and presenting with bone metastasis—A case report." <i>International Journal of Surgery Case Reports</i> 38 (1): 180-184. doi:10.1016/j.ijscr.2017.06.067. <a href="http://dx.doi.org/10.1016/j.ijscr.2017.06.067">http://dx.doi.org/10.1016/j.ijscr.2017.06.067</a> .
Published Version	<a href="https://doi.org/10.1016/j.ijscr.2017.06.067">doi:10.1016/j.ijscr.2017.06.067</a>
Accessed	July 19, 2018 10:46:55 AM EDT
Citable Link	<a href="http://nrs.harvard.edu/urn-3:HUL.InstRepos:34375169">http://nrs.harvard.edu/urn-3:HUL.InstRepos:34375169</a>
Terms of Use	This article was downloaded from Harvard University's DASH repository, and is made available under the terms and conditions applicable to Other Posted Material, as set forth at <a href="http://nrs.harvard.edu/urn-3:HUL.InstRepos:dash.current.terms-of-use#LAA">http://nrs.harvard.edu/urn-3:HUL.InstRepos:dash.current.terms-of-use#LAA</a>

*(Article begins on next page)*



Contents lists available at ScienceDirect

## International Journal of Surgery Case Reports

journal homepage: [www.casereports.com](http://www.casereports.com)

# Invasive follicular variant of papillary thyroid cancer harboring the NRAS mutation Q61K and presenting with bone metastasis—A case report

Raman Mehrzad<sup>a</sup>, Michiya Nishino<sup>b</sup>, Carmelo Nucera<sup>b</sup>, Dora Dias-Santagata<sup>c</sup>, James V. Hennessey<sup>d</sup>, Per-Olof Hasselgren<sup>a,\*</sup>

<sup>a</sup> Department of Surgery, Beth Israel Deaconess Medical Center, Harvard Medical School, Boston, MA, United States

<sup>b</sup> Department of Pathology, Beth Israel Deaconess Medical Center, Harvard Medical School, Boston, MA, United States

<sup>c</sup> Department of Pathology, Massachusetts General Hospital, Harvard Medical School, Boston, MA, United States

<sup>d</sup> Department of Medicine, Beth Israel Deaconess Medical Center, Harvard Medical School, Boston, MA, United States

## ARTICLE INFO

## Article history:

Received 19 February 2017

Received in revised form 16 June 2017

Accepted 17 June 2017

Available online 20 July 2017

## Keywords:

Follicular variant of papillary thyroid cancer

Invasive

NIFTP

Metastases

NRAS mutation

Case report

## ABSTRACT

**INTRODUCTION:** The follicular variant of papillary thyroid cancer (FVPTC) can be noninvasive or invasive. The invasive form of FVPTC commonly harbors *BRAF* mutations whereas *RAS* mutations are more often associated with noninvasive FVPTC and a favorable clinical outcome.

**CASE REPORT:** A 47-year-old man presented with a metastasis to his right iliac bone as the initial manifestation of a 1.6 cm invasive FVPTC. After total thyroidectomy, the patient underwent additional treatment, including thyroid hormone suppressive treatment to non-detectable TSH levels, repeated courses of radioiodine treatment, external beam radiation, and treatment with the tyrosine kinase inhibitor sorafenib. Despite these therapeutic efforts, the disease progressed with growth of the iliac mass and additional metastatic spread to cervical and lumbar vertebrae causing increasing pain and disability. The patient succumbed to the disease four years after presentation. Retrospective next-generation sequencing of the primary tumor using a pan-cancer targeted mutation and gene fusion panel revealed *NRAS* Q61K mutation and no other oncogenic alterations.

**DISCUSSION:** The study challenges the concept that thyroid neoplasms with isolated *RAS* mutations are often associated with favorable clinical behavior and may be candidates for conservative management. **CONCLUSION:** An isolated *RAS* mutation in invasive FVPTC may be associated with an aggressive clinical behavior.

© 2017 The Author(s). Published by Elsevier Ltd on behalf of IJS Publishing Group Ltd. This is an open access article under the CC BY-NC-ND license (<http://creativecommons.org/licenses/by-nc-nd/4.0/>).

## 1. Introduction

The follicular variant of papillary thyroid cancer (FVPTC) is characterized by nuclear features consistent with classical PTC (cPTC) but having follicular rather than papillary architecture [1]. Recent reports suggest that the incidence of FVPTC is on the rise, accounting for up to half of all PTCs in some patient series [2,3].

FVPTC consists of different subgroups with varying pathological and clinical features [4,5]. Although the classification of distinct types of FVPTC has varied, in recent studies [3–7], FVPTC was subdivided into noninvasive tumors (encapsulated and/or well-circumscribed tumors without tumor capsule or lymphovascular invasion) versus invasive tumors (encapsulated tumors with

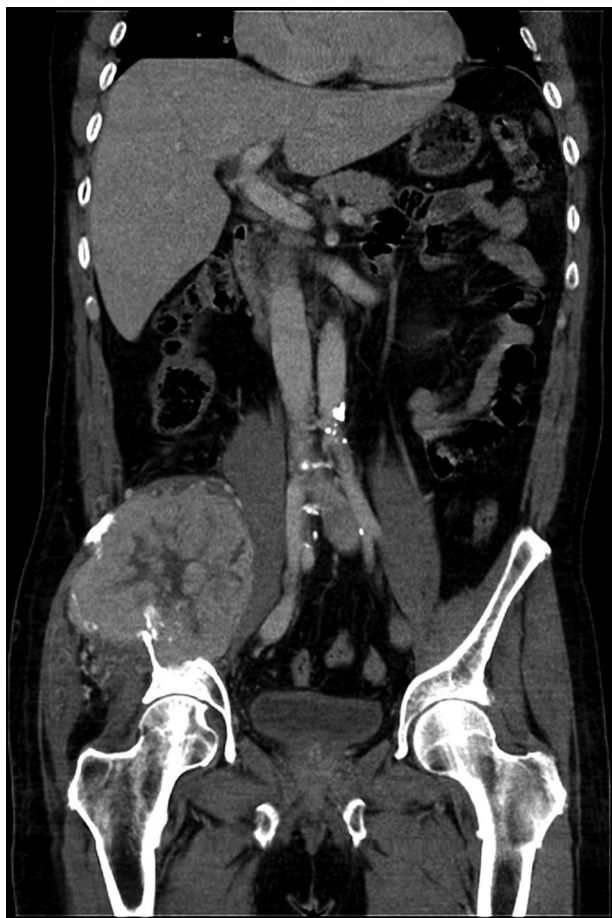tumor capsule or lymphovascular invasion or tumors not being well-circumscribed but showing infiltration into adjacent thyroid tissue).

There is increasing evidence that noninvasive FVPTC has a favorable clinical behavior and may not behave like a cancer but may be an indolent tumor with very low risk of adverse outcome requiring less aggressive treatment than has commonly been recommended [3–8]. The noninvasive FVPTC, therefore, is presently undergoing reclassification from cancer to a low-risk tumor with benign clinical characteristics and was recently proposed to be labeled “non-invasive follicular thyroid neoplasm with papillary-like nuclear features” (NIFTP) [8]. In contrast to the indolent clinical behavior of NIFTP, invasive FVPTCs can be associated with both regional and distant metastases, recurrent disease, and even death [9–11].

Among follicular thyroid neoplasms with papillary-like nuclear features, mutations in the *RAS* oncogene have been associated with encapsulated/well-circumscribed tumors (including NIFTP) whereas invasive FVPTC has more commonly been associated with *BRAF* mutations [8,12]. Studies suggest, however, that there is not

\* Corresponding author at: Department of Surgery, Section of Endocrine Surgery, Beth Israel Deaconess Medical Center, 330 Brookline Avenue ST919, Boston, MA 02215, United States.

E-mail address: [phasselg@bidmc.harvard.edu](mailto:phasselg@bidmc.harvard.edu) (P.-O. Hasselgren).



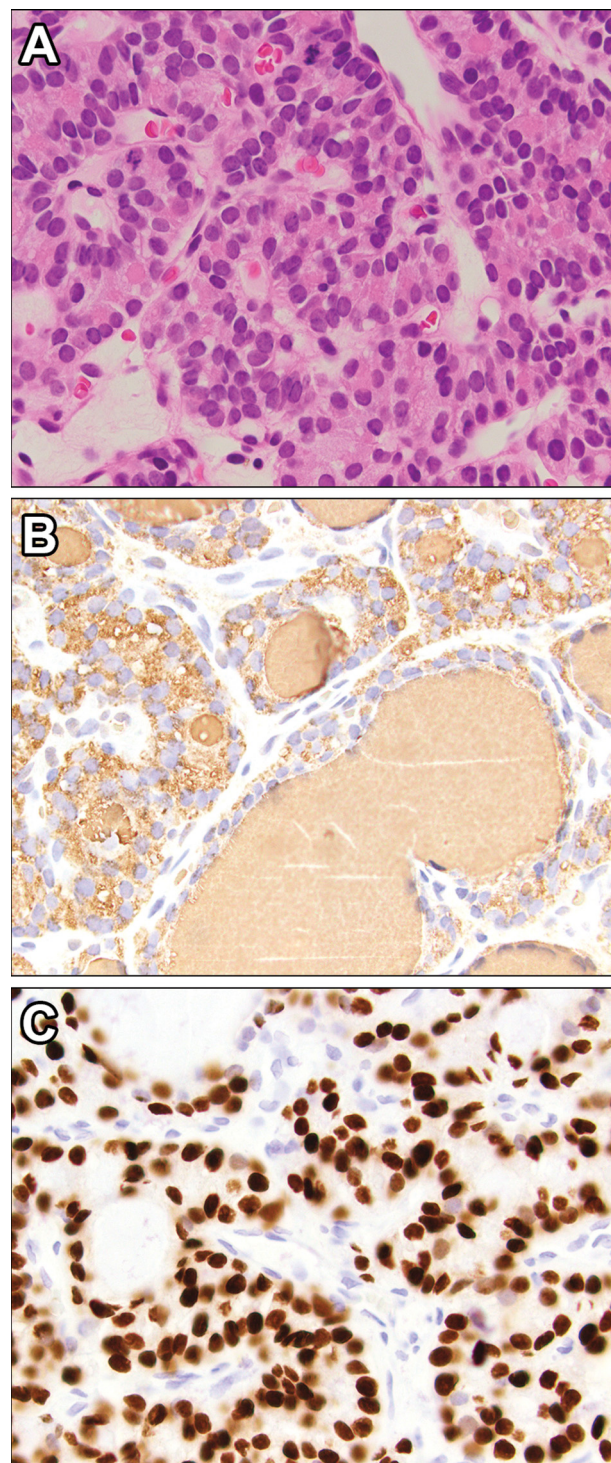
**Fig. 1.** Abdominal/pelvic CT obtained when the patient presented to the ER with right hip pain.

an absolute correlation between gene mutations and the clinical behavior of thyroid neoplasms [13–15].

We report a patient who presented with a bone metastasis as the first manifestation of an invasive FVPTC and who developed additional bone metastases during the course of treatment and ultimately died from his disease. Subsequent molecular analysis revealed that the patient's primary thyroid tumor harbored an isolated *NRAS* Q61K mutation with no co-existing mutations detected by a broad, clinically utilized next-generation sequencing oncogene/gene fusion panel. The report is important because it suggests that follicular-patterned neoplasms that harbor an apparently isolated *RAS* mutation may demonstrate an aggressive clinical course. Our study, therefore, challenges recent views that thyroid tumors with apparently isolated *RAS* mutations may be candidates for conservative management [14,15]. The report adds information to the existing literature and provides an important learning point significant for the management of patients with invasive FVPTC.

## 2. Case report

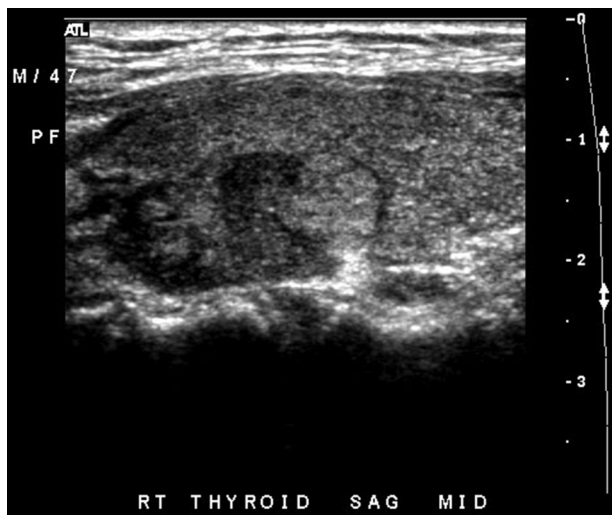A 47-year-old man with no family history of thyroid cancer and who was previously healthy was seen in the emergency room because of progressive right hip and groin pain for approximately one year. Abdominal and pelvic CT revealed a 13 cm hypervascular mass arising from the right iliac bone with extensive bone destruction and involvement of the right psoas, iliopsoas, and gluteal muscles (Fig. 1). A subsequent core biopsy of the mass showed evidence of metastatic thyroid cancer with histopathology revealing follicular architecture and some nuclear features consistent with



**Fig. 2.** Core biopsy of right iliac lesion. (A) Follicular cells with ovoid nuclei, chromatin pallor, and mild nuclear contour irregularity (hematoxylin & eosin, 400× magnification). Tumor cells are positive for thyroglobulin (B) and TTF-1 (C) by immunohistochemistry (400× magnification).

PTC (Fig. 2). Further metastatic workup, including chest CT and brain MRI, revealed no evidence of additional metastases. A thyroid ultrasound showed a 2 cm nodule with internal calcifications in the right thyroid lobe (Fig. 3). The patient underwent a total thyroidectomy to facilitate radioiodine treatment as part of the management of the iliac metastasis. At the time of the thyroidectomy, no central compartment lymphadenopathy was appreciated by inspection or palpation. Histopathological examination of the thyroid gland





**Fig. 3.** Thyroid ultrasound demonstrating a  $1.4 \times 1.5 \times 2$  cm heterogenous nodule with internal calcifications in the right thyroid lobe.

showed a 1.6 cm infiltrative FVPTC with focal extrathyroidal extension and vascular invasion (Fig. 4). There were no regional lymph node metastases. Despite aggressive treatment that included suppressive thyroid hormone treatment to non-detectable TSH levels, repeated courses of radioiodine treatment, external beam radiation of the iliac bone metastasis, and treatment with the kinase inhibitor sorafenib, the disease progressed with growth of the iliac/pelvic mass and additional metastatic spread to cervical and lumbar vertebrae causing worsening pain and disability. Four years after his presentation, the patient, now terminally ill, returned to his homeland to spend time with his family. It should be noted that the patient described here was among a group of 179 patients with FVPTC that we reported recently [3]. Although the patient was mentioned in that report, detailed descriptions of histopathological and imaging findings and gene sequencing were not included in our previous study.

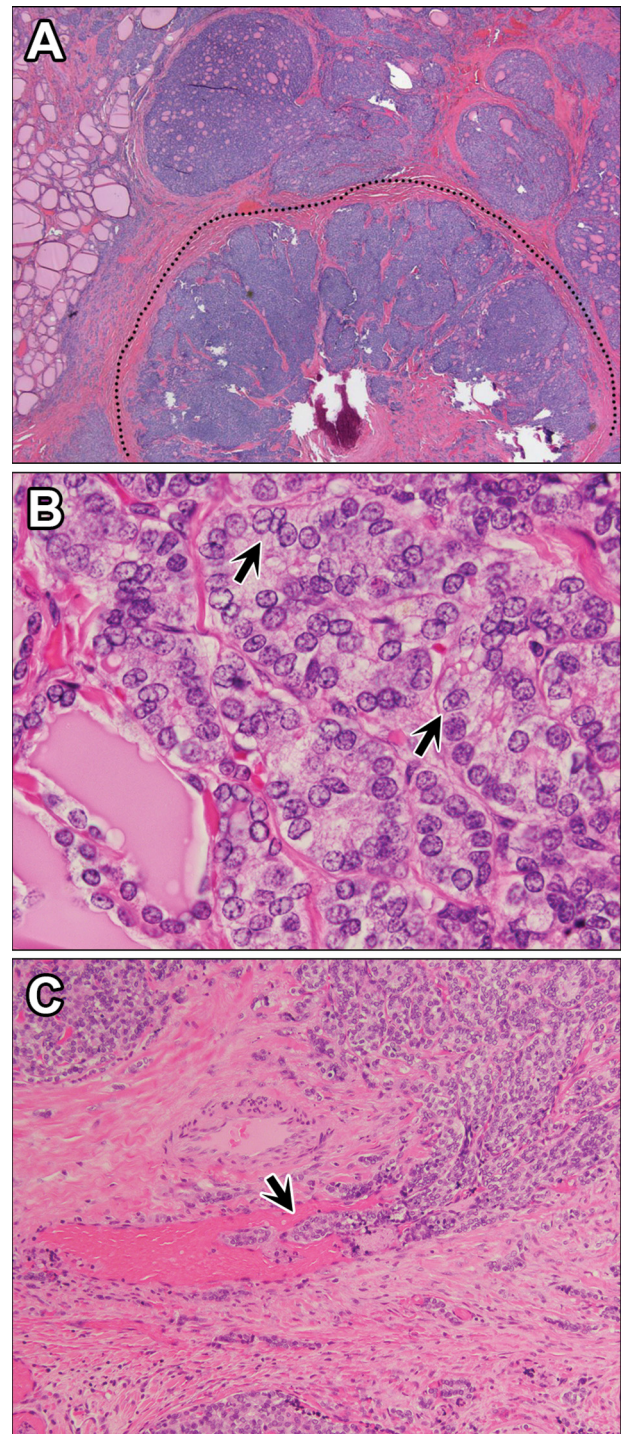
The case report adheres to the Surgical Case Report (SCARE) guidelines [16].

### 3. Targeted next-generation sequencing (NGS)

Analysis of oncogenic alterations was performed retrospectively from the patient's archival formalin-fixed paraffin-embedded thyroidectomy specimen using targeted next-generation sequencing (NGS) technology as described recently [17]. The NGS mutation panel assayed for hotspot mutations in 91 genes (including *BRAF*, *NRAS*, *HRAS*, *KRAS*, *TERT*, *P53*) and the gene fusion panel targeted rearrangements involving 52 genes, including *RET* and *PPARG*. Results from the molecular analysis revealed that the patient's thyroid tumor harbored an *NRAS* Q61K mutation. Details regarding the NGS methodology and the list of targeted genes are provided in the Supplement.

### 4. Discussion

In earlier reports, tumors diagnosed as FVPTC were commonly described and managed as one entity. More recently, the importance of subdividing these tumors into noninvasive and invasive neoplasms has become clear [4,5]. In particular, the recognition that NIFTP may be sufficiently treated by lobectomy alone without requirement for subsequent radioiodine treatment has important clinical implications [8]. In contrast, invasive FVPTC should be recognized as malignant with potential for distant metastases



**Fig. 4.** Total thyroidectomy. (A) Thyroid tumor partially surrounded by fibrous capsule (dotted line), with infiltrative growth into the surrounding thyroid parenchyma (20× magnification). (B) Tumor cells show follicular architecture and nuclear atypia characteristic of papillary thyroid carcinoma, including nuclear crowding, mild nuclear contour irregularity, nuclear grooves (arrows), and chromatin pallor (400× magnification). (C) Tumor shows vascular invasion (arrow; 100× magnification). Hematoxylin & eosin.

and even death from disease [9–11]. Invasive FVPTCs should be managed by total thyroidectomy and, if indicated, postoperative radioiodine treatment. Therefore, if a hemithyroidectomy is performed as initial procedure, no further surgery may be needed if pathology is consistent with NIFTP, whereas a completion thy-

roidectomy should be performed if pathology reveals invasive FVPTC.

The majority of thyroid cancers harbor single gene mutations, most commonly genes in the *BRAF* or *RAS* signaling pathways [18,19]. The relationship between *RAS* mutations and the clinical behavior in thyroid tumors are controversial. Recent reports suggest that thyroid nodules with *RAS* mutations tend to be benign or indolent and that thyroid cancers harboring isolated *RAS* mutations are commonly associated with an excellent prognosis [14,15].

In contrast, other studies have suggested that *RAS* mutations are markers for aggressive behavior in thyroid cancers [13,20]. Data from NGS analysis of poorly differentiated and anaplastic thyroid cancers provide a possible explanation for the disparate biological behavior reported for *RAS*-mutated tumors. Thus, *RAS* mutations may represent an early step in tumorigenesis with the accumulation of subsequent genetic changes promoting cancer progression and biologically aggressive phenotypes. In particular, broad genotyping studies have identified coexistence of *RAS* mutations with mutations of the *TERT* promoter and/or *EIF1AX* as possible signatures of aggressive tumor behavior [20].

Most previous reports of aggressive invasive FVPTCs with distant metastases [9–11] predate the widespread use of NGS technology why their molecular composition is unclear. Our report represents an unusual example of an aggressive invasive FVPTC harboring an isolated *RAS* mutation, contradicting recent reports in which an isolated *RAS* mutation was considered indicative of a low-risk tumor [14,15].

A limitation of our report is that the molecular analysis does not rule out that genes, other than *RAS*, may have been mutated in the patient's tumor and could have escaped detection by the NGS cancer panel used here. While mutations in *TERT* promoter, *TP53*, and other genes were not identified in our case, the NGS panel did not test for mutations in *EIF1AX* or other molecular changes that may provide prognostic information, such as microRNA expression profiles and somatic copy number alterations. The ability to rule out co-existing mutations are directly related to the breadth and relevance of the molecular alterations that are included in a test panel. Because most general NGS cancer panels target the most frequently altered oncogenes and tumor suppressors, less common molecular changes may have escaped detection. As NGS tests, particularly those tailored for thyroid cancer, strive towards a more comprehensive panel of molecular alterations, prognostication of *RAS*-mutated thyroid cancers would be expected to improve in the future.

## 5. Conclusions

Our report provides novel information about invasive FVPTC and suggests that apparently isolated *RAS* mutations can be found in invasive FVPTC and may be associated with aggressive clinical behavior. The observations provide an important learning point and have implications with regards to surgical approach, adjuvant treatment, and patient prognosis.

## Conflicts of interest

None of the authors has any conflict of interest to declare.

## Funding

CN was supported by grants from the National Cancer Institute/National Institutes of Health (1R21CA165039-01A1 and 1R01CA181183-01A1), the American Thyroid Association (ATA), the ThyCa: Thyroid Cancer Survivors Association Inc. for Thyroid

Cancer Research, the Guido Berlucchi “Young Investigator” research award 2013 (Brescia, Italy), and the BIDMC/CAO, Boston, MA.

## Ethical approval

N/A (All images are completely anonymised, the individual cannot be identified by any of the images or through any part of the text).

## Consent

N/A (All images are completely anonymised, the individual cannot be identified by any of the images or through any part of the text).

## Author contribution

Study concept and design: Raman Mehrzad, Per-Olof Hasselgren.

Data collection: Michiya Nishino, Carmelo Nuccera, Dora Dias-Santagata.

Interpretation of data: Raman Mehrzad, Michiya Nishino, Carmelo Nucera, Dora Dias-Santagata, James V. Hennessey, Per-Olof Hasselgren.

Initial drafting of paper: Raman Mehrzad, Per-Olof Hasselgren.

## Registration of research studies

N/A.

## Guarantor

Per-Olof Hasselgren.

## Appendix A. Supplementary data

Supplementary data associated with this article can be found, in the online version, at <http://dx.doi.org/10.1016/j.ijscr.2017.06.067>.

## References

- [1] J. Liu, B. Singh, G. Tallini, D.L. Carlson, N. Katabi, A. Shaha, R.M. Tuttle, R.A. Ghossein, Follicular variant of papillary thyroid carcinoma: a clinicopathologic study of a problematic entity, *Cancer* 107 (2006) 1255–1264.
- [2] S. Ertek, N.C. Yilmaz, A.F. Cicero, O. Vuruplamaz, A.S. Demiroz, G. Erdogan, Increasing diagnosis of thyroid papillary carcinoma follicular variant in south-east Anatolian region: comparison of characteristics of classical papillary and follicular variant of thyroid cancers, *Endocr. Pathol.* 23 (2012) 157–160.
- [3] R. Mehrzad, M. Nishino, J. Connolly, H. Wang, P. Mowschenson, P.O. Hasselgren, The relationship between follicular variant of papillary thyroid cancer and follicular adenomas, *Surgery* 159 (2016) 1396–1406.
- [4] M. Vivero, S. Kraft, J.A. Barletta, Risk stratification of follicular variant of papillary thyroid carcinoma, *Thyroid* 23 (2013) 273–279.
- [5] I. Ganly, L. Wang, R.M. Tuttle, N. Katabi, G.A. Ceballos, H.R. Harach, R. Ghossein, Invasion rather than nuclear features correlates with outcome in encapsulated follicular tumors: further evidence for the reclassification of the encapsulated papillary thyroid carcinoma follicular variant, *Hum. Pathol.* 46 (2015) 657–664.
- [6] K.C. Strickland, B.E. Howitt, E. Marqusee, E.K. Alexandre, E.S. Cibas, J.F. Krane, J.A. Barletta, The impact of noninvasive follicular variant of papillary thyroid carcinoma on rates of malignancy for fine-needle aspiration diagnostic categories, *Thyroid* 25 (2015) 987–992.
- [7] W.C. Faquin, L.Q. Wong, A.H. Afrogheh, S.Z. Ali, J.A. Bishop, M. Bonqiovanni, M.P. Pusztaszeri, C.J. VandenBussche, J. Gourmaud, L.J. Vaickus, Z.W. Baloch, Impact of reclassifying noninvasive follicular variant of papillary thyroid carcinoma on the risk of malignancy in the Bethesda system for reporting thyroid cytopathology, *Cancer Cytopathol.* 124 (2016) 181–187.
- [8] Y.E. Nikiforov, R.R. Seethala, G. Tallini, Z.W. Baloch, F. Basolo, L.D. Thompson, J.A. Barletta, B.M. Wenig, A. Al Ghuzlan, K. Kakudo, T.J. Giordano, V.A. Alves, E. Khanafshar, S.L. Asa, A.K. El-Naggar, W.E. Gooding, S.P. Hodak, R.V. Lloyd, G. Maytal, O. Mete, M.N. Nikiforova, V. Nosé, M. Papotti, D.N. Poller, P.M. Sadow, A.S. Tischler, R.M. Tuttle, K.B. Wall, V.A. LiVolsi, G.W. Randolph, R.A. Ghossein,

- Nomenclature revision for encapsulated follicular variant of papillary thyroid carcinoma. A paradigm shift to reduce overtreatment of indolent tumors, *JAMA Oncol.* 2 (2016) 1023–1029.
- [9] Z.W. Baloch, V.A. LiVolsi, Encapsulated follicular variant of papillary thyroid carcinoma with bone metastases, *Mod. Pathol.* 13 (2000) 861–865.
  - [10] S. Widder, K. Guggisberg, M. Khalil, J.L. Pasieka, A pathologic re-review of follicular thyroid neoplasms: the impact of changing the threshold for the diagnosis of the follicular variant of papillary thyroid carcinoma, *Surgery* 144 (2008) 80–85.
  - [11] J. Jedrzkiewicz, B.L. Witt, FNA diagnosis of a metastatic papillary thyroid carcinoma arising from a previously unknown follicular variant of papillary thyroid microcarcinoma, *Diagn. Cytopathol.* 42 (2014) 711–715.
  - [12] M. Rivera, J. Ricarte-Filho, J. Knauf, A. Shaha, M. Tuttle, J.A. Fagin, R.A. Gossesin, Molecular genotyping of papillary thyroid carcinoma follicular variant according to its histological subtypes (encapsulated vs infiltrative) reveals distinct BRAF and RAS mutation patterns, *Mod. Pathol.* 23 (2010) 1191–1200.
  - [13] M. Fukahori, A. Yoshida, H. Hayashi, M. Yoshihara, S. Matsukuma, Y. Sakuma, S. Koizume, N. Okamoto, T. Kondo, M. Masuda, Y. Miyagi, The associations between RAS mutations and clinical characteristics in follicular thyroid tumors: new insights from a single center and a large patient cohort, *Thyroid* 22 (2012) 683–689.
  - [14] M. Medici, N. Kwong, T.E. Angell, E. Marqusee, M.I. Kim, M.C. Frates, C.B. Benson, E.S. Cibas, J.A. Barletta, J.F. Krane, D.T. Ruan, N.L. Cho, A.A. Gawande, F.D. Moore Jr, E.K. Alexander, The variable phenotype and low-risk nature of RAS-positive thyroid nodules, *BMC Med.* 13 (2015) 184–193.
  - [15] M. Xing, Clinical utility of RAS mutations in thyroid cancer: a blurred picture now emerging clearer, *BMC Med.* 14 (2016) 12–16.
  - [16] R.A. Agha, A.J. Fowler, A. Saeta, I. Barai, S. Rajmohan, D.P. Orgill, for the SCARE Group, The SCARE statement: consensus-based surgical case report guidelines, *Int. J. Surg.* 34 (2016) 180–186.
  - [17] Z. Zheng, M. Liebers, B. Zhelyazkova, Y. Cao, D. Panditi, K.D. Lynch, J. Chen, H.E. Robinson, H.S. Shim, J. Chmielecki, W. Pao, J.A. Engelman, A.J. Iafrate, L.P. Le, Anchored multiplex PCR for targeted next-generation sequencing, *Nat. Med.* 20 (2014) 1479–1484.
  - [18] Y.E. Nikiforov, N.P. Otori, S.P. Hodak, S.E. Carty, S.O. LeBeau, R.L. Ferris, L. Yip, R.R. Seethala, M.E. Tublin, M.T. Stang, C. Coyne, J.T. Johnson, A.F. Stewart, M.N. Nikiforova, Impact of mutational testing on the diagnosis and management of patients with cytologically indeterminate thyroid nodules: a prospective analysis of 1056 FNA samples, *J. Clin. Endocrinol. Metab.* 96 (2011) 3390–3397.
  - [19] The cancer genome atlas research network integrated genomic characterization of papillary thyroid carcinoma, *Cell* 159 (2014) 676–690.
  - [20] G. Garcia-Rostan, H. Zhao, R.L. Camp, M. Pollan, A. Herrero, J. Pardo, R. Wu, M.L. Carcangiu, J. Costa, G. Tallini, RAS mutations are associated with aggressive tumor phenotypes and poor prognosis in thyroid cancer, *J. Clin. Oncol.* 21 (2003) 3226–3235.

#### Open Access

This article is published Open Access at [sciencedirect.com](https://www.sciencedirect.com). It is distributed under the [IJSCR Supplemental terms and conditions](#), which permits unrestricted non commercial use, distribution, and reproduction in any medium, provided the original authors and source are credited.