



Iris abscess a rare presentation of intravenous drug abuse associated Candida endophthalmitis

Citation

Pierce, Jonathan, Nisha Warriar, Christina Antonopoulos, Nicole Siegel, and Deeba Husain. 2016. "Iris abscess a rare presentation of intravenous drug abuse associated Candida endophthalmitis." *American Journal of Ophthalmology Case Reports* 4 (1): 27-29. doi:10.1016/j.ajoc.2016.07.003. <http://dx.doi.org/10.1016/j.ajoc.2016.07.003>.

Published Version

doi:10.1016/j.ajoc.2016.07.003

Permanent link

<http://nrs.harvard.edu/urn-3:HUL.InstRepos:35981973>

Terms of Use

This article was downloaded from Harvard University's DASH repository, and is made available under the terms and conditions applicable to Other Posted Material, as set forth at <http://nrs.harvard.edu/urn-3:HUL.InstRepos:dash.current.terms-of-use#LAA>

Share Your Story

The Harvard community has made this article openly available.
Please share how this access benefits you. [Submit a story](#).

[Accessibility](#)



Case report

Iris abscess a rare presentation of intravenous drug abuse associated *Candida* endophthalmitisJonathan Pierce^{a, c}, Nisha Warriar^b, Christina Antonopoulos^b, Nicole Siegel^b,
Deeba Husain^{c, *}^a The George Washington University School of Medicine and Health Sciences, Washington, DC, USA^b Department of Ophthalmology, Boston University School of Medicine, Boston, MA, USA^c Department of Ophthalmology, Massachusetts Eye and Ear Infirmary, Harvard Medical School, Boston, MA, USA

ARTICLE INFO

Article history:

Received 28 March 2016

Received in revised form

26 June 2016

Accepted 14 July 2016

Available online 18 July 2016

Keywords:

Infectious endophthalmitis

Iris abscess

Intravenous drug abuse

Candida albicans

ABSTRACT

Purpose: To describe an unusual case of intravenous drug abuse associated endogenous endophthalmitis presenting with an iris abscess.**Observations:** A 30-year old female with history of intravenous drug use presented with a two-week history of redness and blurry vision in the right eye. An initial diagnosis of anterior uveitis was made. However, she worsened on topical steroids and mydriatics. She was found to have a hypopyon and an iris abscess. She received broad spectrum antibiotic and antifungal treatment with voriconazole, this led to significant clinical improvement. She was discharged on oral fluconazole and lost to follow up. The patient was noncompliant with the antifungal treatment. The hypopyon and iris abscess recurred, and she required a vitrectomy with iridectomy, along with intravitreal and systemic antifungal treatment. The vitreous cultures and surgical specimen of iris issue were positive for *Candida albicans*, and she received voriconazole. This led to resolution of the condition with a final visual acuity of 20/20 at six month follow up.**Conclusions and importance:** An iris abscess is a rare clinical presentation of intravenous drug use-associated endogenous endophthalmitis and as a result may present a diagnostic challenge as it requires a high level of clinical suspicion and a detailed social history to elicit the drug abuse. Early diagnosis and aggressive therapy is the key to better visual outcomes in these patients.© 2016 The Authors. Published by Elsevier Inc. This is an open access article under the CC BY-NC-ND license (<http://creativecommons.org/licenses/by-nc-nd/4.0/>).

1. Introduction

Endophthalmitis is a rare but severe intraocular infection with the risk of poor visual outcome. Endogenous endophthalmitis comprises just 2–8% of all cases of endophthalmitis.^{1,2} This condition most often arises secondary to systemic infection, although few cases have recently been reported in immunocompetent individuals as well.^{3–5} Intravenous drug use (IVDU) has remained a major public health concern in urban settings for many decades.^{6–8} Recently, a large review by Jackson et al. found IVDU to be the second most common predisposing factor for development of endogenous endophthalmitis.⁹ Here, we highlight a rare case of

intravenous drug abuse associated endogenous endophthalmitis presenting as an iris abscess in an otherwise healthy young female patient.

1.1. Case report

A 30-year-old Caucasian female with no previous ocular history presented to a general ophthalmologist with gradually increasing redness and blurry vision in her right eye for 2–3 weeks accompanied by progressively worsening throbbing eye pain and occasional headaches. On initial exam, visual acuity was 20/70 OD, 20/20 OS. Intraocular pressure in the right eye was 10 mmHg. The conjunctiva of the right eye was injected. On slit-lamp exam, cornea keratic precipitates were present and 3+ cells were noted in the anterior chamber. The view of the iris was hazy, but the lens was clear. Anterior vitreous cells were also present. The examination of

* Corresponding author. Institution Harvard Medical School, Mass Eye and Ear Infirmary, 12th floor, 243 Charles Street, Boston, MA 02114, USA.

E-mail address: Deeba_husain@meei.harvard.edu (D. Husain).

the left eye was within normal limits. A diagnosis of anterior uveitis was made and the patient was started on 1% prednisolone forte every 1–2 hours and cyclopentolate 1% three times a day.

The patient returned three days later with significantly worsening pain and was urgently referred to a retina specialist for evaluation. She was found to have a visual acuity of 20/200 OD and an intraocular pressure of 6 mmHg. At this time, the cornea was edematous with numerous keratic precipitates, and a 1.5 mm hypopyon was detected. Detailed and persistent review of systems revealed that she had an axillary abscess one year prior. She was homeless and had a history of Hepatitis C seropositivity. She endorsed IVDU, with her last use being a few months ago, thus elevating the concern for a possible infectious etiology. Anterior chamber and vitreous tap were performed with intravitreal injections of ceftazidime (2.25mg/0.1ml), vancomycin (1mg/0.1ml), and voriconazole (100µg/0.1ml). She was admitted to the hospital, started on IV vancomycin, cefepime, and voriconazole, and blood cultures were obtained. All cultures from this admission were negative for both bacteria and fungal species.

Over the next 48 hours, while still hospitalized, she improved symptomatically. Her hypopyon resolved, and her visual acuity returned to 20/30 OD by day 4. Only trace cells remained in the anterior chamber and vitreous on examination of the right eye. All cultures remained negative. Prior to discharge, she was switched to fluconazole due to patient's lack of insurance coverage and concerns for compliance issues. Given her apparent response to the treatment while she was an inpatient, she was discharged on oral fluconazole.

The patient was lost to follow up and returned two weeks later with blurry vision and brow ache. She informed us that she was noncompliant with her oral fluconazole. On examination, her visual acuity was 20/50 OD. There was recurrence of the hypopyon along with a nodular elevation in the iris with fibrin in the anterior chamber, as well as anterior capsular and subcapsular lens opacities (Fig. 1). Posterior segment exam remained unremarkable. She was readmitted and restarted on systemic voriconazole, cefepime, and vancomycin. She underwent a diagnostic and therapeutic pars plana vitrectomy with lensectomy and iridectomy. Vitreous cultures were positive for *Candida albicans*, sensitive to both fluconazole and voriconazole. A final diagnosis of chronic granulomatous inflammation involving the iris stroma and surface with fungus present was established by histopathology (budding yeast) (Figs. 2 and 3). She was discharged on oral voriconazole for 4 weeks, with prednisolone forte and atropine drops. Her vision returned to 20/20 with a +12D contact lens on six month follow up (Fig 4).

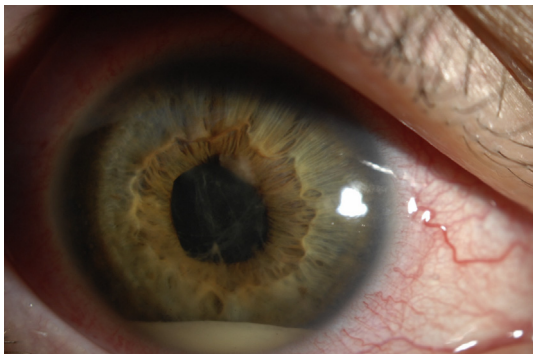


Fig. 1. Slit lamp photograph of patient's right eye at follow up visit showing a hypopyon with fibrin in the anterior chamber, a yellowish superonasal elevation and a mass at the pupillary border.

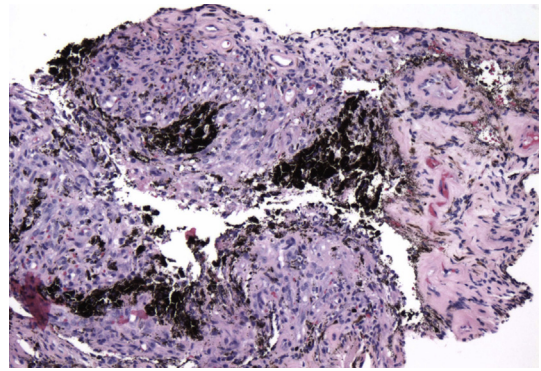


Fig. 2. Iris stroma with chronic granulomatous inflammation composed of histiocytes and giant cells.

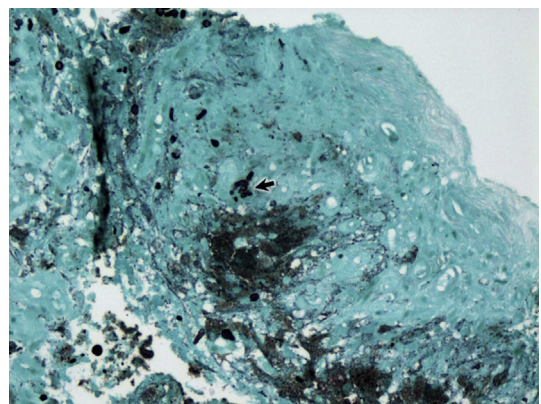


Fig. 3. Fungal spore with budding yeast (arrowhead) consistent with *Candida* species.

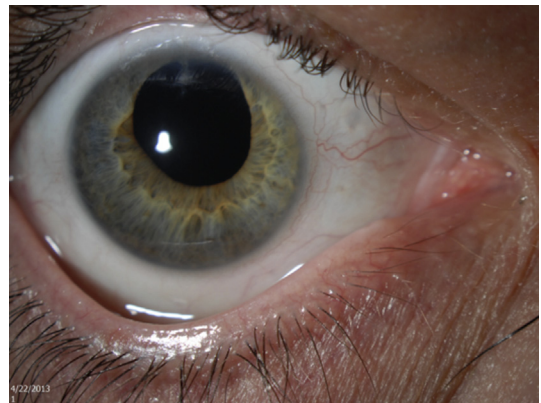


Fig. 4. Slit lamp photograph of patient's right eye at six month follow up.

2. Discussion

Endogenous endophthalmitis is a rare intraocular infection with potentially poor visual prognosis that is responsible for a relatively small fraction of all cases of endophthalmitis. These infections can arise from both bacterial and fungal organisms, most commonly *Staphylococcus*, *Klebsiella*, *Aspergillus* or *Candida albicans*.⁵ Intravenous drug abuse is now being recognized as an emerging cause of endogenous endophthalmitis in larger cities and tertiary centers. This disease is often misdiagnosed in this population as it is particularly difficult to identify for a number of reasons. These

patients are typically young and otherwise healthy. Many of these patients are not forthcoming about their history of illicit drug use and may have poor compliance with follow up appointments. Additionally, there is potential for latency between inoculation of the pathogen from IVDU and the clinical presentation of signs and symptoms.¹⁰ Therefore, a high level of suspicion and the ability to get the history of drug abuse is very important for diagnosis.

Given the relative rarity of this condition, the specific treatment guidelines for endogenous endophthalmitis are varied given the relative paucity of large case series. The typical clinical presentation of this disease is chorioretinitis with symptoms including decreased vision, eye pain, eye redness, photophobia, floaters, and eyelid swelling.⁵ Clinical signs such as hypopyon, subconjunctival hemorrhage, conjunctival injection, iritis/retinitis, corneal edema, anterior chamber cells, and reduced or absent red reflex may also be present. An iris abscess is rare, making this particular case a diagnostic challenge. Only a few cases have been reported in the literature, notably one secondary to endocarditis caused by *Staphylococcus aureus*,³ and one after a routine dental cleaning caused by *Strep intermedius*.¹¹ To our knowledge, only one other case of an iris abscess associated with IVDU has been reported.⁴ However, the suspected history of IVDU was never confirmed by the patient in this case.

In addition to highlighting a unique clinical presentation of this condition, this case may also serve as an example of how the choice of antifungal therapy may affect clinical outcome. When this patient initially presented, she was placed on voriconazole and her condition improved significantly as an inpatient. However, due to financial circumstances, at time of discharge she was switched to fluconazole – a less expensive alternative to newer generation triazole agents with less favorable ocular penetrance.¹² The recurrence of disease and worsening of abscess most likely happened due to noncompliance with the use of antifungal and possibly use of fluconazole which has lesser intraocular penetration. One could argue that if she had been discharged on voriconazole initially and been compliant with treatment, perhaps the reoccurrence and surgical intervention could have been avoided.

3. Conclusions

The growing number of cases of intravenous drug abuse associated endogenous endophthalmitis represents a change in the demographics of patients with this disease. The atypical presentation in this population contributes to the degree of difficulty of

correctly diagnosing this disease in these patients. A high level of suspicion and the ability to get the history of drug abuse is important for diagnosis. Early diagnosis and aggressive therapy is the key to better visual outcomes in these patients. The common presentation of endogenous endophthalmitis is chorioretinitis; an iris abscess is rare, making this particular case a true diagnostic challenge.

4. Patient consent

The patient provided oral consent for the publication of this case.

References

1. Smith SR, Kroll AJ, Lou PL, Ryan EA. Endogenous bacterial and fungal endophthalmitis. *Int Ophthalmol Clin*. 2007;47:173–183. <http://dx.doi.org/10.1097/IIO.0b013e31803778f7>.
2. Sadiq MA, Hassan M, Agarwal A, et al. Endogenous endophthalmitis: diagnosis, management, and prognosis. *J Ophthalmic Inflamm Infect*. 2015;5:32. <http://dx.doi.org/10.1186/s12348-015-0063-y>.
3. Ramonas K, Frielich B. Iris abscess as an unusual presentation of endogenous endophthalmitis in a patient with bacterial endocarditis. *Am J Ophthalmol*. 2003;135:228–229. [http://dx.doi.org/10.1016/S0002-9394\(02\)01935-9](http://dx.doi.org/10.1016/S0002-9394(02)01935-9).
4. Braich P, Chang J, Albini T, Scheffer A. Irido-lenticular abscess as the initial sign of *Candida albicans* endogenous endophthalmitis. *Ophthalmic Surg Lasers Imaging Retina*. 2011. <http://dx.doi.org/10.3928/15428877-20111201-01>.
5. Vaziri K, Schwartz SG, Kishor K, Flynn HW. Endophthalmitis: state of the art. *Clin Ophthalmol*. 2015;9:95–108. <http://dx.doi.org/10.2147/OPHT.S76406>.
6. Center for Behavioral Health Statistics and Quality. *Behavioral health trends in the United States: Results from the 2014 National survey on drug use and health (HHS Publication No. SMA 15–4927, NSDUH Series H-50)*; 2015 (accessed 21.03.16) <http://www.samhsa.gov/data/sites/default/files/NSDUH-FRR1-2014/NSDUH-FRR1-2014.pdf>.
7. Page K, Morris MD, Hahn JA, Maher L, Prins M. Injection drug use and hepatitis C virus infection in young adult injectors: using evidence to inform comprehensive prevention. *Clin Infect Dis*. 2013;57:S32–S38. <http://dx.doi.org/10.1093/cid/cit300>.
8. Tempalski B, Pouget ER, Cleland CM, et al. Trends in the population prevalence of people who inject drugs in US metropolitan areas 1992–2007. *PLoS ONE*. 2013;8:e64789. <http://dx.doi.org/10.1371/journal.pone.0064789>.
9. Jackson TL, Paraskevopoulos T, Georgalas I. Systematic review of 342 cases of endogenous bacterial endophthalmitis. *Surv Ophthalmol*. 2014. doi: 10.1016/j.survophthal.2014.06.002.
10. Patel S, Rescigno R, Zarbin M, Langer P, Bhagat N. Endogenous endophthalmitis associated with intravenous drug abuse. *Retina*. 2014;34:1460–1465. <http://dx.doi.org/10.1097/IAE.0000000000000084>.
11. Mali JO, Falk NS, Mali YP, Mencias L. Endogenous endophthalmitis with iris abscess after routine dental cleaning. *JAMA Ophthalmol*. 2015 May;133:616–617. <http://dx.doi.org/10.1001/jamaophthalmol.2015.12>.
12. Hariprasad S, Mieler W, Lin T, Sponcel W, Graybill J. Voriconazole in the treatment of fungal eye infections: a review of current literature. *Br J Ophthalmol*. 2008;92:871–878. <http://dx.doi.org/10.1136/bjo.2007.136515>.