



Predictive Imaging Features and Longitudinal Follow-Up of Intracranial Meningiomas in Patients With Neurofibromatosis 2

Citation

Chipidza, Fallon E. 2016. Predictive Imaging Features and Longitudinal Follow-Up of Intracranial Meningiomas in Patients With Neurofibromatosis 2. Doctoral dissertation, Harvard Medical School.

Permanent link

<http://nrs.harvard.edu/urn-3:HUL.InstRepos:40620260>

Terms of Use

This article was downloaded from Harvard University's DASH repository, and is made available under the terms and conditions applicable to Other Posted Material, as set forth at <http://nrs.harvard.edu/urn-3:HUL.InstRepos:dash.current.terms-of-use#LAA>

Share Your Story

The Harvard community has made this article openly available.
Please share how this access benefits you. [Submit a story](#).

[Accessibility](#)

Scholarly Report submitted in partial fulfillment of the MD Degree at Harvard Medical School

Date: 1 March 2016

Student Name: Fallon Chipidza, BA

Scholarly Report Title: Predictive Imaging Features and Longitudinal Follow-up of Intracranial Meningiomas in Patients with Neurofibromatosis 2

Mentor Name(s) and Affiliations: Helen A. Shih, MD, MS, MPH, Department of Radiation Oncology, Massachusetts General Hospital

Abstract:

TITLE: Predictive Imaging Features and Longitudinal Follow-up of Intracranial Meningiomas in Patients with Neurofibromatosis 2

Fallon E. Chipidza, Mykol Larvie, Scott R. Plotkin, and Helen A. Shih.

Purpose: Patients with the Neurofibromatosis Type 2 (NF2) develop three major types of tumors: vestibular schwannomas (VS), meningiomas and ependymomas. The natural history of VSs has been well characterized, but that of meningiomas (which occur in multiple frequencies) is not well understood. Our study aims to understand the natural history of intracranial meningiomas by analyzing their radiologic features on CT and MR images as well as their pathologic features from those meningiomas that were resected.

Methods: Between 1988 and 2015, 34 patients with a documented NF2 diagnosis were followed at MGH . Twenty-eight of these patients harbored at least 1 intracranial meningioma and the corresponding tumor data was obtained from T1 axial sequences on surveillance scans.

Results: On average, women tend to have a higher meningioma burden and earlier age of diagnosis than men. However, men tend to have larger tumors with a much faster growth rate as measured by both linear and volumetric dimensions. De novo tumors also tend to exhibit a more aggressive growth pattern than pre-existing ones. There was not an association between ADC and tumor growth rate.

Conclusions: Our results suggest that larger tumors, particular in men, as well as de novo tumors may warrant closer surveillance or early surgical intervention.

Table of Contents:

Glossary of Abbreviations.....4
Introduction.....5
Significance.....6
Student Role.....8
Methods.....9
Results.....11
Discussion.....17
Acknowledgements.....18
References.....19

Glossary of Abbreviations:

- NF2: Neurofibromatosis Type II
- CT: Computerized Tomography (imaging)
- MR: Magnetic Resonance (Imaging)
- MRN: Medical Record Number
- 3D: Three Dimensional (Imaging)
- MGH: Massachusetts General Hospital
- VS: Vestibular Schwannoma
- IAC: Internal Auditory Canal
- GD: Gadolinium
- ADC: Apparent Diffusion Coefficient
- DWI: Diffusion Weighted Imaging
- WHO: World Health Organization

Section 1:

INTRODUCTION:

Neurofibromatosis Type II (NF2) is a rare autosomal dominant disease with 100% penetrance by age 60 and variable expressivity (1). The disease arises from loss of heterozygosity mutations in the tumor suppressor gene, neurofibromin (merlin) which is located on human chromosome 22 (2, 3). In up to 50% of cases, the disease can also arise sporadically from de novo mutations (4). There is marked heterogeneity within the NF2 population. As can be predicted, the more severe cases tend to be early onset with more pronounced peripheral disease while the milder cases have a later onset (1). In a genetic study of NF2 patients in the United Kingdom, Evans et al. (1) showed that maternally inherited NF2 tends to be more severe and has an earlier onset (~18 years) than paternally inherited disease (mean age of onset = 24 yrs, $p=0.026$). These findings were also confirmed in a similar, but larger study (20).

A defining hallmark of NF2 is the development of bilateral vestibular schwannomas, but patients also develop ependymomas and meningiomas, with meningiomas being the second most common tumors after the vestibular schwannomas (4). In the case of schwannomas, since they usually occupy the vestibular branch rather than the acoustic branch of cranial nerve eight, the term vestibular schwannoma is preferred over acoustic neuroma. About 50% of the NF2 patients harbor meningiomas, and these meningiomas tend to occur in multiple frequencies (5, 6). Despite being generally slow growing and mostly asymptomatic in sporadic cases, meningiomas in NF2 display higher proliferative potential and aggressive growth (7). While differences in meningioma quantities may be explained by somatic mosaicism (6), the differences in growth potential and behavior are likely due to the idiosyncratic natural histories of these tumors. Specifically, the presence of meningiomas in an NF2 patient signals disease severity and the differing proliferative potentials of each meningioma warrant an understanding of the balance between risk of treatment and natural history of the disease (6).

It is known that in NF2 patients with multiple meningiomas, some tumors will grow aggressively while others will remain indolent throughout the lifetime of the patient. Currently, we are unable to predict which meningiomas will exhibit rapid growth and which will remain stable. Our present analysis attempts to address this knowledge gap by retrospectively analyzing the magnetic resonance (MR) and computerized tomography (CT) images of thirty-four NF2 patients who have been followed at the MGH Cancer Center. We identify radiologic features that can be used

to predict meningioma growth patterns over time to understand the distribution of the features in meningiomas displaying differing growth potentials.

There are no known effective medical therapies for treatment of meningiomas. In sporadic meningiomas, surgical resection with or without radiation therapy is the mainstay of treatment as it is usually curative as monotherapy (21). While it minimizes the risk of recurrence (22), complete surgical resection is not always possible. Additional factors complicating treatment decision include patient age, performance status, tumor size, growth pattern history, peritumoral edema and symptoms (22). For NF2-related meningiomas, treatment varies from institution to institution due to lack of robust data and lack of standardized practices. Because of concerns of treatment associated morbidity, many NF2 patients receive routine surveillance. Tumors are usually resected or debulked after they produce mass effect, exhibit aggressive growth or the patient develops complex neurologic symptomatology. Our study quantifies these growth rates and correlates them to baseline patient clinical and imaging characteristics in effort to provide useful clinical guidance in the management of this challenging patient population.

SIGNIFICANCE:

The goal of this project is to identify, in NF2-related meningiomas, imaging features and/or clinical patient characteristics that can be reliably prognostic in outcomes, and thus establish guidelines for timing of early intervention or closer surveillance in potentially-aggressive tumors. While sporadic meningiomas in the general population can typically be managed with surgery and or radiation therapy, meningiomas in NF2 are much more challenging. The challenge arises from the knowledge that NF2 meningiomas occur in multiple frequencies. For instance, one of the patients in our database has nineteen unique meningiomas. It would not be feasible to treat every single one of these with surgery and radiation. In addition, there typically other and multiple intracranial tumors which will need to be considered when weighing interventions of surgery and radiation therapy. Developing a robust imaging methodology through which we are able to prognosticate growth pattern i.e. tumor aggressiveness, would help determine meningiomas requiring close surveillance or early intervention.

Furthermore, among all NF2 patients, those harboring multiple meningiomas carry a 2.5 fold increased risk of mortality compared to those with one or no meningioma (9). Because meningiomas in NF2 patients and those in the general population appear to have different

natural histories, clinical presentations, and response to therapy, data on how to manage intracranial meningiomas in NF2 patients is scant. This conundrum is further complicated by the evidence that different meningiomas in a single NF2 patient behave differently. As a result, institutional guidelines differ on when intervention is indicated and when watchful waiting is appropriate. NF2 patients with meningiomas usually have yearly surveillance scans and per the MGH institutional guidelines, tumors are resected when patients develop symptoms or when aggressive growth is detected on imaging.

There are few population based studies of NF2 patients with even fewer large studies that have been done in developed countries. Few studies have analyzed the natural history of and followed image changes of meningiomas in NF2 patients over time (10, 11). These studies have, nonetheless, several limitations including short follow-up (11), small number of patients (11), fewer image characteristics and no correlation between pathological data and the observed image features (10,11). Our current study builds upon some of this prior work and goes beyond them by providing longer term follow up data.

Section 2:

STUDENT ROLE:

Data Collection: Following IRB approval and identifying eligible NF2 patients treated at MGH, the student reviewed all CT and MR images obtained on each patient and created a new database capturing various radiologic or pathologic attributes. The student used PACS archiving software to physically review and measure all features listed in Tables 1 and 2 below. The student obtained pathology data by reviewing all the pathology reports of tumors that were resected. Finally, where 3D imaging was available, the student used MIM contouring software to outline the tumors to obtain their volumes.

Table 1: List of MRI variables collected

Tumor Information (for each patient)	Location Information (yes/no)- for each individual tumor	Radiologic Features (yes/no)- for each individual tumor
1. Total number of tumors.	1. Lobe involved.	1. Heterogeneous enhancement
2. Scan date	2. Along convexity?	2. Degree of enhancement
3. Image Slice Size	3. Along Falx/Tentorium?	3. T2 intensity relative to gray matter
	4. In basal cistern?	4. Indistinct tumor/brain interface
	5. In sphenoid wings?	5. Positive capsular enhancement
	6. In posterior fossa?	6. Growth Pattern
	7. In Ventricle?	7. Mean ADC
		8. Calcification
		9. Cystic component
		10. Necrosis
		11. Bone involvement
		12. Reactive Hyperostosis
		13. Surrounding edema

Table 2: List of histopathologic features collected

1. WHO Grade: - Grade I - Grade II - Grade III	7. Grade I Sub-type: -meningoepithelial -transitional -psammomatous -angioblastic -fibroblastic
2. Increased Cellularity (y/n)	8. Atypical Features (y/n)
3. Architectural Sheeting (y/n)	9. Ki67 value (%)
4. Prominent Nucleoli (y/n)	10. MIB-1 >3% (y/n)
5. High N/C ratio (y/n)	11. MIB-1/Ki67
6. Necrosis (y/n)	12. mitosis/HPF

Statistical Analyses: The student used JMP statistical software and R statistical software to analyze results obtained from the patient charts.

Report Draft: The student produced this scholarly report in its entirety.

Section 3:

METHODS:

Patients:

A total of 34 patients were identified with a documented NF2 diagnosis who were followed at MGH Cancer Center between 1988 and 2015. Diagnosis of NF2 was made by Manchester Criteria. History of surgery (for schwannoma, meningioma, or ependymoma) was not used as exclusion criteria. In the final analysis, only 28 patients harboring at least 1 image-proven meningioma were included. The majority of these patients had multiple comorbidities including vision deficit, hearing loss, paralysis, seizures, or cognitive dysfunction.

Tumors:

Spinal tumors were excluded as well as most enhancing IAC lesions that were interpreted as VS by the neuroradiologist. A few IAC tumors with more classical meningioma appearance as defined by shape, slight difference in enhancement pattern, and ultimately identified as meningioma by the neuroradiologist were included. Each tumor was assigned a unique numerical identifier, which was maintained in subsequent scans. Meningioma Quantification was calculated by including total number of tumors at the end of the patient's follow-up period, i.e. including de novo masses.

Imaging:

T1 axial post GD images were used to identify and count the total number of tumors. If the data was available, each tumor was correctly identified using axial, coronal, and sagittal slices. Only intracranial meningiomas greater than 4mm were included. Scans within less than one year of each other were not included, except in a few cases of very obvious rapid growth. Capsular enhancement was considered positive if greater than 50% of the tumor's circumference was enhancing on a post-contrast imaging. If >50% of the tumor is intensely enhancing, then that tumor was marked as strongly enhancing.

Growth:

In order to account for human error, tumors whose diameters were within 2mm of the successive scan and had no corresponding volume measurements were considered to be "stable". Maximum tumor diameter was measured in the axial plane with dural tail being excluded from these calculations. Growth pattern was described as "plaque" for tumors whose base was wider than the height. Invasion of sinuses, compression and florid invasion were

classified the same since it is difficult to distinguish between the two without an MRV (most pts in this database have no MRVs). By virtue of being in the lateral ventricles, ventricular meningiomas were also considered to be invasive.

Various metrics have been used to measure tumor growth in image-based studies of the natural history of meningiomas (10, 11). For our present study, we used equations a) and b) to determine meningioma growth rates.

$\frac{[Final\ Tumor\ Volume - Initial\ Tumor\ Volume]}{Follow-up\ Interval\ i.e.\ (mL/month)} \dots\dots\dots (a)$
$\frac{[Final\ Tumor\ Diameter - Initial\ Tumor\ Diameter]}{Follow-up\ Interval\ i.e.\ (mm/month)} \dots\dots\dots (b)$

Surgery:

Most tumors were resected for mass effect/neurologic deficits or for being at risk of symptoms with further growth. Growth and radiologic parameters in a previously resected tumor were not measured. Similarly, partially resected tumors were not included in subsequent measurements because of the challenge in distinguishing postoperative changes versus natural progression of the tumor.

Pathology:

Only tumors for which there is a pathology report were included. If no comments were made about a specific histologic feature, the assumption was made that that specific feature was absent. For example, if a pathology report comments on cellularity, mitotic activity, and sheeting, the assumption is made that there is no necrosis since the report made no comments on necrosis. If multiple surgical specimens were sent for pathological analysis, but the pathology report groups all samples together, the assumption was made that all specimens expressed the same features. Sheeting is defined as patternless growth while MIBⁱ is a measure of aggressive growth with >3% theoretically means rapid growth. Ki67% is a proliferation index marker which is generally used as a predictor of recurrence. If a tumor has some rhabdoid pattern, it is by WHO definition a grade III tumor.

Statistical Analysis:

Distributive statistical analyses and correlative analyses were carried out using JMP software version 12.0.1 (64-bit) and R version 3.2.3 (2015-12-10)---“Wooden Christmas-Tree.”

Section 4:

RESULTS:

Table 3 below summarizes the cohort characteristics of our study. There were 34 patients total who met initial inclusion criteria, 28 of whom had at least one meningioma. The 8 who did not have at least 1 meningioma were therefore excluded from all subsequent analyses. Of these 28 remaining patients, 16(57%) were women while 12(43%) were men. The mean age of diagnosis was 23 with 13(46%) being diagnosed with NF2 before the age of 23. The youngest patient was diagnosed at 2 1/2 years of age, while the oldest age of diagnosis was 58. Regarding number of meningiomas per patient, the majority of patients (50%) had between 1 and 5 meningiomas while 7 (21%) patients had more than ten unique meningiomas. The patient with the most number of tumors harbored nineteen unique meningiomas. Overall, across all 28 patients with at least 1 meningioma, there were 177 meningiomas. For the purposes of our study, once a baseline MRI scan for each patient was established and all pre-existing tumors were accounted for, any new tumors that appeared in subsequent scans were described as being de novo. The majority (82%) of the tumors in this analysis were pre-existing and 38(18%) were de novo.

Table 3: Cohort Characteristics:

VARIABLE	N	CATEGORY	Count (%)
Diagnosis Age: (median=23)	28	≤22y.o.	13 (46%)
		>22y.o.	15(54%)
Gender:	28	Female	16 (57%)
		Male	12 (43%)
Number of Tumors/Pt*	34	0	6 (17.6%)
		≤5	17 (50%)
		5-to-10	4 (11.8%)
		>10	7 (20.6%)
Meningiomas	177	Pre-existing	144(82%)
		De Novo	33(18%)

**Includes the 6 patients who had 0 intracranial meningiomas (total patients=34 for this variable only)*

All MRI sequences obtained per patient were accompanied by an official radiologic report, with each describing the cranial location of the tumor. All descriptive adjectives used were collected and input into a word-cloud generating platform, results of which are shown in Figure 1 below. Consistent with conventional wisdom, the word-cloud shows that the majority of the meningiomas occupied the parafalcine regions along major convexities. In the anteroposterior

Linear dimensions for each tumor were determined by measuring the maximum axial diameter of each tumor on a T1 axial MR slice. Among the 177 meningiomas in the cohort, the mean diameter was 18.2mm (10.2) with the smallest one measuring 5mm and the largest measuring 63mm. On average, men harbored meningiomas with a much larger diameter (20.0mm) than women (17.4mm). However, women had 2.5times more meningiomas than men i.e. 127 versus 50 in men. Table 5 below also shows that on average, de novo meningiomas had a smaller diameter (16.2mm) than pre-existing ones (18.6mm). However, to account for time, the best way to compare de novo tumors to pre-existing ones is by measuring the growth rate. Merely measuring the linear dimensions does not account for the fact that the de novo tumor may not have enough time to “mature into full their potential” like the pre-existing ones. Table 6 highlights this distinction.

Table 5: Average Tumor Size by Maximum Diameter

Variable	n	Mean (SD)	Min	Max
Tumor Diameter(ALL tumors)	177	18.2(10.2)mm	5	63
Tumor Diameter(men)	50	20.0(12.7)mm	5	59
Tumor Diameter(women)	127	17.4(8.9)mm	5	63
Tumor Diameter(pre-existing tumors)	144	18.6(10.0)mm	5	63
Tumor Diameter(De Novo tumors)	33	16.2(10.5)mm	5	53

Growth Rate Analysis:

When accounting for differential follow-up times, it becomes clear that de novo tumors have a more aggressive growth pattern compared to pre-existing ones. Out of the 177 total tumors in the study, 64 displayed linear growth rates greater than at least 2mm between successive scans. Of these 64, sixty were pre-existent and only four were de novo. Mean linear growth for all tumors was 0.21(0.24)mm/month, but de novo meningiomas grew at a mean rate of 0.36mm/month while pre-existing ones grew at a rate of 0.2mm/month. Similar to absolute linear dimensions, men’s meningiomas grew at a rate higher than that for women: 0.26mm/month versus 0.18mm/month. This same pattern was maintained when growth rate was determined using volumes.

Only 12 growing tumors had 3D MR images available. By determining volumes for each tumor using MIM software, the average growth rate for all tumors was 0.25mL/month with men having a higher rate of growth than women: 0.39mL/month versus 0.14mL/month.

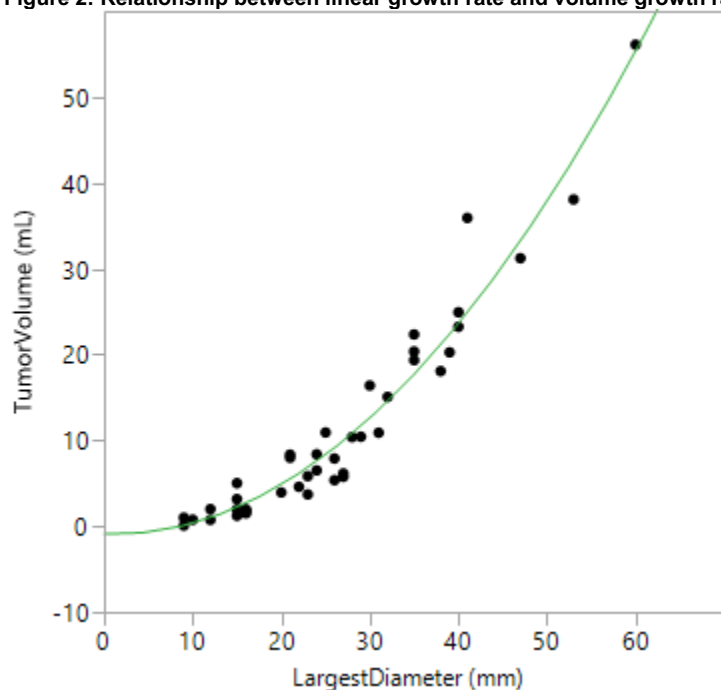
Table 6: Average Tumor growth by maximum axial diameter and by net volume

Variable	n	Mean (SD)	Min	Max
Linear growth Rate(ALL tumors)	64	0.21(0.24) mm/month	0.02	1
Linear growth Rate(men)	23	0.26(0.29)mm/month	0.02	0.94
Linear growth Rate(women)	41	0.18(0.21)mm/month	0.02	1
Linear growth Rate (pre-existing tumors)	60	0.20(0.23)mm/month	0.02	1
Linear Growth Rate(De Novo tumors)	4	0.36(0.4)mm/month	0.09	0.94
Volume growth rate(ALL tumors)	12	0.25(0.26) mL/month	0.01	0.9
Volume growth rate(men)	5	0.39(0.35) mL/month	0.03	0.9
Volume growth rate(women)	7	0.14(0.12) mL/month	0.01	0.3

Correlative Analysis:

We also analyzed how different variables correlated with one another. As one might expect, the linear dimensions as measured by the maximum axial diameter were not only directly proportional to the volume of the tumor. The relationship was exponential with the relationship falling towards: $[Volume \propto diameter^2]$. Figure 2 below displays this relationship.

Figure 2: Relationship between linear growth rate and volume growth rate



Apparent Diffusion Coefficient (ADC) on a DWI MR image is correlated with the tumor aggressiveness. The more active the cells of a dividing tumor, the more restriction of water molecules they will display and hence the lower the diffusion coefficient. So more rapidly

dividing cells are associated with a lower ADC. We looked at the relationship between the measured ADC on DWI images and the growth rates as determined above. For this preliminary analyses, there does not appear to be a relationship between ADC and linear or volume growth rate as shown in Figures 3 and 4.

Figure 3: Relationship between growth rate and ADC

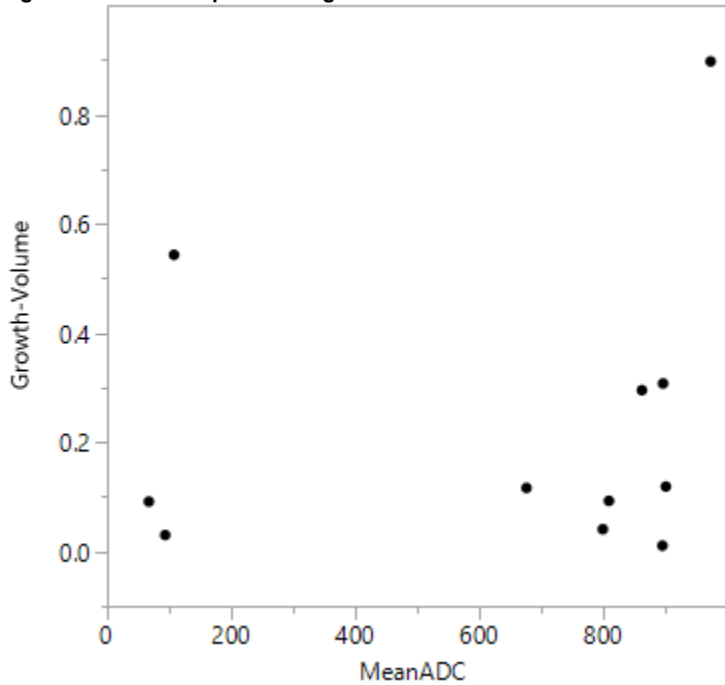
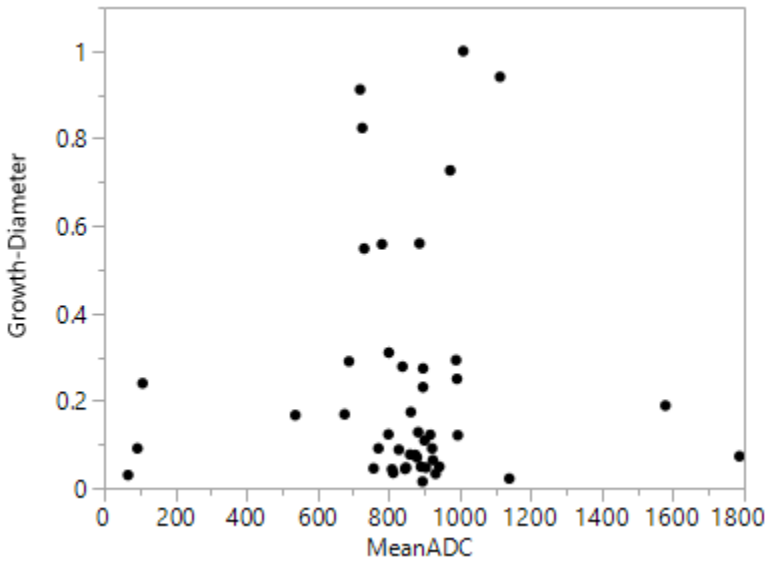


Figure 4: Relationship between linear diameter and ADC



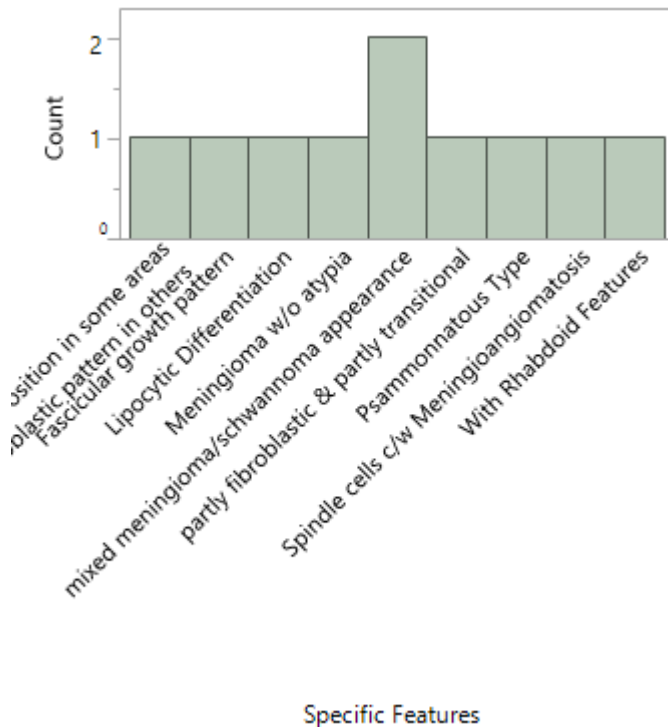
Pathology Data:

Over the course of the follow-up period, several meningiomas were resected and 14 of these had pathology reports available. Table 6 below summarizes some of the principal findings. While there were no WHO grade III meningiomas, the majority (7 out of 11) of the documented ones were grade II. Many samples had a normal N/C ratio without any visible necrosis. However, 9 out of the 14 meningioma resected samples displayed atypical features. For those meningiomas with specific features noted, Figure 5 below illustrates the observed spectrum.

Table 6: Pathology Data for the tumors that were resected and had pathology reports available.

Variable	Category	Count (N=14)
WHO Grade:	Grade I	4
	Grade II	7
	Grade III	0
N/C ratio:	Normal	10
	High	3
Necrosis:	Absent	9
	Present	5
Atypical Features:	None	5
	Present	9

Figure 5: Specific Features present on Pathology data



Section 5:

DISCUSSION:

We report on the long-term follow-up of 177 meningiomas in 28 NF2 patients. The goal of this investigation is to characterize meningiomas within the complex disease of NF2 to provide data to compare to the more common meningiomas of sporadic (non-NF 2) origin. Importantly, our findings will add to the sparse data on the natural history of this rare disease. The major weaknesses of our study are that it is a retrospective analysis study with few patients. However, for a rare disease such as NF2, it is very difficult to have a highly powered study. Also, as our analysis is only limited to intracranial meningiomas, these findings cannot be generalized to other tumors found in this patient population, such as spinal meningiomas, ependymomas, vestibular schwannomas, and peripheral neuromas.

One of the most striking findings in our investigation is that, in patients with NF2, women tend to have a higher intracranial meningioma tumor burden than men. On average, female patients also tend to be diagnosed with NF2 earlier than men, suggestive that they may express a more aggressive disease phenotype. However, despite having fewer tumors, meningiomas in men tend to be larger than in women. Although one might argue that their later age of diagnosis implies that tumors have had a longer period to grow, men's meningiomas have faster linear and volume growth rates. In fact, the volume growth rate of meningiomas in men is more than twice as fast as in women, suggesting more aggressive disease in this population subset.

Meanwhile, as has been suggested by an earlier study (10), de novo meningiomas trended to have a more aggressive growth pattern than pre-existing tumors. Their rate of growth is about 1.5 times greater than pre-existing tumors, thus warranting closer surveillance or early surgical intervention when possible. Also, since there is a very strong association between tumor diameter and linear growth rate, the larger tumors may require earlier intervention than the smaller ones. The first line therapy for the majority of the tumors in our database was surgery, with fractionation radiotherapy used in a smaller subset.

Several studies have shown that ADC is correlated with tumor aggressiveness [add reference here]. In our study, however, we did not detect an association between meningioma growth rate and ADC when looking at correlation analysis basis only. For volume growth rate, one confounder is that only 12 tumors in the cohort of 177 cases had 3D images available for volume calculation, hence there was insufficient data to determine a plausible relationship between ADC and volume growth rate.

Pathology data on resected meningiomas was also underpowered with only 14 tumors with reports. However, from this limited set, we determined that the majority were WHO grade II

tumors with normal N/C ratios. The majority of the samples exhibited atypical features and specific features ranged from no atypia to rhabdoid features.

For the next phase of our project, we will ascertain for potential significant relationships within our study cohort.

Section 6:

ACKNOWLEDGEMENTS:

I would like to thank the patients and their family members who made this study possible.

REFERENCES:

1. Evans, D. G., Huson, S. M., Donnai, D., Neary, W., Blair, V., Teare, D., ... & Harris, R. (1992). A genetic study of type 2 neurofibromatosis in the United Kingdom. I. Prevalence, mutation rate, fitness, and confirmation of maternal transmission effect on severity. *Journal of Medical Genetics*, 29(12), 841-846.
2. Seizinger, B. R., Martuza, R. L., & Gusella, J. F. (1986). Loss of genes on chromosome 22 in tumorigenesis of human acoustic neuroma.
3. Rouleau, G. A., Merel, P., Lutchman, M., Sanson, M., Zucman, J., Marineau, C., ... & Thomas, G. (1993). Alteration in a new gene encoding a putative membrane-organizing protein causes neuro-fibromatosis type 2.
4. Aoki, S., Barkovich, A. J., Nishimura, K., Kjos, B. O., Machida, T., Cogen, P., ... & Norman, D. (1989). Neurofibromatosis types 1 and 2: cranial MR findings. *Radiology*, 172(2), 527-534.
5. Parry, D. M., Eldridge, R., Kaiser-Kupfer, M. I., Bouzas, E. A., Pikus, A., & Patronas, N. (1994). Neurofibromatosis 2 (NF2): clinical characteristics of 63 affected individuals and clinical evidence for heterogeneity. *American journal of medical genetics*, 52(4), 450-461.
6. Goutagny, S., & Kalamarides, M. (2010). Meningiomas and neurofibromatosis. *Journal of neuro-oncology*, 99(3), 341-347.
7. Antinheimo, J., Haapasalo, H., Haltia, M., Tatagiba, M., Thomas, S., Brandis, A., ... & Jääskeläinen, J. (1997). Proliferation potential and histological features in neurofibromatosis 2-associated and sporadic meningiomas. *Journal of neurosurgery*, 87(4), 610-614
8. Hwang, W., Marciscano, A.E., Kim, D., Stemmer-Rachamimov, A.O., Curry, W.T., Barker, F.G., Larvie, M. and Shih, H.A., 2015. Correlation of Imaging Characteristics With Histopathological WHO Grade in Meningiomas. *International Journal of Radiation Oncology* Biology* Physics*, 93(3), p.E86.
9. Baser, M. E., Friedman, J. M., Aeschliman, D., Joe, H., Wallace, A. J., Ramsden, R. T., & Evans, D. G. R. (2002). Predictors of the risk of mortality in neurofibromatosis 2. *The American Journal of Human Genetics*, 71(4), 715-723.
10. Goutagny S, Henin D, Parfait B, Grayeli AB, Sterkers O, Kalamarides M. Long-term follow-up of 287 meningiomas in neurofibromatosis type 2 patients: clinical, radiological, and molecular features. *Neuro-oncology*. 2012 Aug 1;14(8):1090-6.
11. Dirks MS, Butman JA, Kim HJ, Wu T, Morgan K, Tran AP, Lonser RR, Asthagiri AR. Long-term natural history of neurofibromatosis Type 2-associated intracranial tumors: Clinical article. *Journal of neurosurgery*. 2012 Jul;117(1):109-17.

12. Asthagiri AR, Parry DM, Butman JA, Kim HJ, Tsilou ET, Zhuang Z, Lonser RR. Neurofibromatosis type 2. *The Lancet*. 2009 Jun 12;373(9679):1974-86.
13. Aboukais R, Zairi F, Baroncini M, Bonne NX, Schapira S, Vincent C, Lejeune JP. Intracranial meningiomas and neurofibromatosis type 2. *Acta neurochirurgica*. 2013 Jun 1;155(6):997-1001.
14. Antinheimo J, Haapasalo H, Haltia M, Tatagiba M, Thomas S, Brandis A, Sainio M, Carpen O, Samii M, Jääskeläinen J. Proliferation potential and histological features in neurofibromatosis 2-associated and sporadic meningiomas. *Journal of neurosurgery*. 1997 Oct;87(4):610-4.
15. Perry A, Giannini C, Raghavan R, Scheithauer BW, Banerjee R, Margraf L, Bowers DC, Lytle RA, Newsham IF, Gutmann DH. Aggressive Phenotypic and Genotypic Features in Pediatric and NF2-Associated Meningiomas: A Clinicopathologic Study of 53 Cases. *Journal of Neuropathology & Experimental Neurology*. 2001 Oct 1;60(10):994-1003.
16. Kleihues P, Burger PC, Scheithauer BW. *Histological Typing of Tumours of the Central Nervous System*. World Health Organization. Berlin: Springer-Verlag, 1993
17. Matsuno A, Fujimaki T, Sasaki, T et al. 1996. Clinical and histopathological analysis of proliferative potentials of recurrent and non-recurrent meningiomas. *Acta Neuropathol* 91:504-510.
18. Ohta M, Iwaki T, Kitamoto T, et al. 1994. MIB1 staining index and scoring of histologic features in meningioma. *Cancer* 74:3176-3189.
19. Perry A, Stafford SL, Scheithauer BW, Suman VJ, Lohse CM. Meningioma grading: an analysis of histologic parameters. *The American journal of surgical pathology*. 1997 Dec 1;21(12):1455-65.
20. Kanter WR, Eldridge R, Fabricant R, Allen JC, Koerber T. Central neurofibromatosis with bilateral acoustic neuroma: genetic, clinical and biochemical distinctions from peripheral neurofibromatosis. *Neurology* 1980;30:851-9.
21. Norden AD, Drappatz J, Wen PY. Advances in Meningioma Therapy. *Current Neurology and Neuroscience Reports* 2009, 9:231–240
22. Jaaskelainen J: Seemingly complete removal of histologically benign intracranial meningioma: late recurrence rate and factors predicting recurrence in 657 patients. A multivariate analysis. *Surg Neurol* 1986, 26:461–469.

ⁱ. The presence of a MIB-1 labeling index greater than 3% has been correlated with recurrence of meningiomas(3, 4)