



Assessment of the Femoro-Epiphyseal Acetabular Roof (FEAR) Index as a Predictor of Long-Term Outcomes in Developmental Dysplasia of the Hip

Citation

Fandino, Luis. 2019. Assessment of the Femoro-Epiphyseal Acetabular Roof (FEAR) Index as a Predictor of Long-Term Outcomes in Developmental Dysplasia of the Hip. Doctoral dissertation, Harvard Medical School.

Permanent link

<http://nrs.harvard.edu/urn-3:HUL.InstRepos:41971476>

Terms of Use

This article was downloaded from Harvard University's DASH repository, and is made available under the terms and conditions applicable to Other Posted Material, as set forth at <http://nrs.harvard.edu/urn-3:HUL.InstRepos:dash.current.terms-of-use#LAA>

Share Your Story

The Harvard community has made this article openly available.
Please share how this access benefits you. [Submit a story](#).

[Accessibility](#)

Scholarly Report submitted in partial fulfillment of the MD Degree at Harvard Medical School-

Date: 25 February 2019

Student Name: Luis Fandino, B.S.

Scholarly Report Title: Assessment of the Femoro-Epiphyseal Acetabular Roof (FEAR) Index as a Predictor of Long-Term Outcomes in Developmental Dysplasia of the Hip

No plans to submit for publication

Mentor and Affiliations: Travis Matheney, M.D. LMA *Boston Children's Hospital Department of Orthopaedic Surgery*

Contents

Abstract	3
Glossary of Abbreviations	4
Introduction	4-5
Student Role	5
Methods	5-6
Results	6
Discussion, Limitations, Conclusions, and Suggestions for Future Work	6-7
Acknowledgements	7
References	8-9
Tables and Figures	9-12

Abstract

Purpose: Periacetabular osteotomy (PAO) is an alternative to arthroplasty in patients with developmental dysplasia of the hip (DDH). PAO, a joint preserving surgery, is a desirable option as arthroplasty in young patients may be associated with prosthetic failure and activity restrictions.¹ The Femoro-Epiphyseal Acetabular Roof (FEAR) index has been shown to be a useful and reliable marker in determining clinical instability in patients with borderline hip dysplasia.² The primary aim of this study is to assess if there is an association between preoperative/postoperative FEAR index and long-term failure in DDH patients treated with PAO.

Methods: This study is a retrospective review of long-term outcomes (>20 years) for approximately 135 patients undergoing PAO from August 1991 to September 1998 at Boston Children's Hospital. The preoperative and postoperative FEAR indices were assessed on AP pelvis radiographs. Preoperative and postoperative FEAR indices were analyzed to assess whether preoperative index or degree of postoperative correction was predictive of PAO failure.

Results:

135 patient records were included in the initial study. 19 (19.8%) hips failed by WOMAC Score or conversion to THA with mean of 96 months \pm 14 months to failure. 77 (80.2%) of hips were preserved. Mean FEAR index improved from 13.66° preoperatively to -4.47° postoperatively. Mean lateral center edge angle (LCEA) improved from 5.41° preoperatively to 31.75° postoperatively. Mean preoperative Tönnis angle improved from 25.69° to 7.74° postoperatively. Mean anterior center edge angle (ACEA) improved from 6.1° to 27.41° postoperatively. Preoperative Tönnis grade 2-3 (OR: 3.613, 95% CI 1.21-10.01, $p=0.042$), postoperative Tönnis grade 2-3 (OR: 15.5, 95% CI 2.12-11.35, $p=0.007$) and postoperative minimum joint space width < 2 mm (OR: 9.046, 95% CI 1.43-6.54, $p=0.031$.) were found to be significantly associated with PAO failure

Conclusions: This retrospective review suggests that there is no association between preoperative/postoperative FEAR index measurement and long term PAO outcomes.

Glossary of Abbreviations

PAO: Periacetabular Osteotomy

DDH: Developmental Dysplasia of the Hip

FEAR Index: Femoro-Epiphyseal Acetabular Roof Index

LCEA: Lateral Center Edge Angle

ACEA: Anterior Center Edge Angle

THA: Total Hip Arthroplasty

WOMAC Index: Western Ontario and McMaster Universities Osteoarthritis Index

OA: Osteoarthritis

FAI: Femoroacetabular Impingement

BMI: Body Mass Index

MRA: Magnetic Resonance Arthrograph

Section 1: Introduction

Periacetabular osteotomy (PAO) is an alternative to arthroplasty in patients with developmental dysplasia of the hip (DDH). PAO, a joint preserving surgery, is a desirable option as arthroplasty in young patients may be associated with prosthetic failure and activity restrictions.²

Additionally, PAO has been shown to be a durable treatment option with good intermediate term outcomes.³ However, due to difficulty in defining osseous instability in these borderline dysplastic hips using radiographic measures, selecting surgical candidates for PAO remains.

Recently a new radiographic measure, the Femoro-Epiphyseal Acetabular Roof (FEAR) index has been shown to be a useful and reliable marker in determining clinical instability in patients with borderline hip dysplasia.²

Borderline dysplasia of the hip continues to be a source of controversy in hip preservation.^{4,5} In part, this controversy continues due to the difficulty in radiographic assessment of these hips. Traditionally, the lateral center edge angle (LCEA) has been used to classify hips with LCEA $>25^\circ$ as normal and dysplastic if LCEA is $<20^\circ$. Borderline hips are those in which LCEA is between 20° - 25° . Thus, it is not clear whether these hips should be classified as stable or dysplastic. Additionally, LCEA has not been found to be a reliable predictor of stability or as a guide in surgical management.¹

Despite recent advancements in imaging and biomechanics, it still remains unclear whether the underlying problem in borderline dysplastic hips is instability (dysplasia) or femoroacetabular impingement (FAI).³ This distinction is of importance as unstable hips benefit from PAO, while the preferred treatment for FAI is open or arthroscopic impingement surgery. In fact, arthroscopic repair of unstable hips may result in sustained symptoms of instability.² Thus it is crucial for today's surgeons to accurately predict which patients will benefit from PAO. As PAO becomes more widely used, it is important to understand long term outcomes and which factors may be associated with hip longevity. Currently these data are sparse.⁶

In a 2016 publication Wyatt et al. discuss the development of the FEAR index. In their study, they found that the FEAR index showed higher intraobserver and interobserver reliability compared to previous radiographic measures such as LCEA and acetabular index. Additionally,

FEAR index yielded the greatest distinction with respect to treatment status. Ultimately, Wyatt et al. concluded that a painful hip with a LCEA $\leq 25^\circ$ and FEAR index $< 5^\circ$ is likely to be stable.

Section 2: Student Role

I extracted explanatory variables from the medical record and recorded values onto a spreadsheet database. The patient database was queried and selected patients were excluded based on established criteria. Once patients were excluded, I searched the medical record for preoperative and postoperative AP pelvis and false profile views of the affected hip. I performed all radiographic measurements of interest.

I then analyzed patient characteristics comparing the descriptive statistics between preserved hips and failed hips. With the aid of a statistician, I performed univariate and multivariate analyses on variables of interest to assess association with PAO failure. I was responsible for creation of tables and graphs included in this report.

Section 3: Methods

This retrospective review examined long term outcomes (>20 years) for 135 patients undergoing PAO from August 1991 to September 1998 at Boston Children's Hospital. Electronic medical records were queried to exclude patients missing preoperative or postoperative hip radiographs, patients with PAO for indications other than DDH, and patients with prior hip trauma or surgeries. Additionally, conditions associated with joint hypermobility and instability were also excluded. Patients with previous diagnosis of Perthes disease, neuromuscular disorders/connective tissue disease, or trisomy 21 and were excluded. **Figure 1** summarizes application of inclusion and exclusion criteria.

Once patients were excluded, variables indicating PAO failure were recorded. Conversion to total hip arthroplasty (THA) was recorded. Previous surveys were examined for other indicators of PAO failure such as Western Ontario and McMaster Universities Osteoarthritis Index (WOMAC) pain score >10 . The date and patient age at time of PAO failure was recorded. Descriptive factors such as age at surgery, gender, race, height, weight, body mass index (BMI) were recorded. Surgical variables such as PAO date, laterality of PAO, and concurrent procedures were also recorded.

LCEA, Tönnis angle, minimum joint space, Tönnis grade, and FEAR index were measured on preoperative, early postoperative and late postoperative (>20 years) AP pelvis radiographs. FEAR indices were calculated by measuring the angle between a straight line spanning the central third of the femoral physeal scar and a line formed by connecting the most medial and lateral portions of the sclerosis of the sourcil. ACEA was measured at these same time points on false profile view hip radiographs. Tönnis classification was used to grade osteoarthritis (OA).
3,7,8

Statistical analyses were performed using Statistical Package for the Social Sciences (SPSS) Statistics. Descriptive statistics were calculated and Chi-squared testing was used to measure outcome associations. Variables showing significant associations ($p < 0.05$) with hip failure in univariable analyses were included in multivariable analysis. Backward selection was used to create multivariable logistic regression models. Model calibration was assessed using the

Hosmer-Lemeshow test. A probability value <0.05 was considered statistically significant for all tests.

Section 4: Results

135 patient records were included in initial study. Of these, 27 were excluded due to missing radiographs, prior hip trauma, Perthes, neuromuscular/connective tissue disorders, or trisomy 21. 12 patients were lost to follow up. Of 96 hips that qualified for analysis, 19 (19.8%) hips failed by WOMAC Score or conversion to THA with a mean of 96 months \pm 14 months to failure. 77 (80.2%) of hips were preserved.

At time of PAO, the mean age for these 108 patients was 26.6. 88.9% of the patients were female, and the majority of patients were white (85.9%). Mean height and weight were 166.1 cm and 72.3 kg respectively. Mean BMI was 26.4 kg/m². **Table 1** summarizes patient demographics.

Table 2 summarizes measurement of radiographic correction between preoperative and postoperative films. Mean FEAR index improved from 13.66° preoperatively to -4.47° postoperatively. Mean LCEA improved from 5.41° preoperatively to 31.75°. Mean preoperative Tönnis angle improved from 25.69° to 7.74° postoperatively. Mean ACEA improved from 6.1° to 27.41° postoperatively.

Univariate analysis was performed to assess association between patient characteristics and PAO failure. Age >25 years, BMI ≥ 30 , preoperative and postoperative grade 2-3 Tönnis grade and minimum joint space width < 2 mm were found to be significant. **Table 3** summarizes patient and hip characteristics by outcome in univariable analysis model. Statistically significant variables were used in a multivariable regression analysis. Preoperative and postoperative Tönnis grade 2-3, and postoperative minimum joint space width < 2 mm were found to be significant in multivariable regression analysis. Preoperative Tönnis Grade 2-3 had an OR:3.613, 95% CI 1.21-10.01, $p= 0.042$. Postoperative Tönnis Grade 2-3 had an OR: 15.5, 95% CI 2.12-11.35, $p= 0.007$. Postoperative minimum joint space width < 2 mm had an OR 9.046, 95% CI 1.43-6.54, $p= 0.031$. **Table 4** summarizes characteristics by outcome in multivariable regression models.

Section 5: Discussion, Limitations, Conclusions, and Suggestions for Future Work

Proper evaluation of borderline hip dysplasia remains a significant challenge for clinicians. Incorrect treatment, such as arthroscopy which is intended to treat FAI, could likely result in persistent symptoms of instability in these patients. With the advent of PAO, clinicians have sought to more accurately identify stable hips.

Our study showed that radiographic measurements were poor predictors of long term PAO failure. Of note, both preoperative and postoperative Tönnis Grade 2-3, and postoperative reduced joint space were associated with long term PAO failure. **Figure 2** shows Tönnis grade determination when assessing for radiographic signs of OA. Minimum joint space < 2 mm at the superior acetabulum is another radiographic marker of OA. It is reasonable that patients with these visible signs of OA would be more likely to require conversion to THA or demonstrate symptomatic failure indicated by patient reported outcome scales such as WOMAC. Of note, there is some controversy regarding the role of Tönnis grade in selecting PAO candidates. The

general consensus is that lower preoperative Tönnis grade will result in better outcomes. However, prior studies note differing cutoffs for surgical candidates.⁹⁻¹³ Additionally, it is important to note that the original paper by Wyatt et al excluded patients with Tönnis grade >1.

Though prior studies note excellent intraobserver reliability of FEAR index measurements (intraclass correlation coefficient 0.99), measurements in our study were not as consistent. User ability and experience when measuring radiographic landmarks may partially account for these differences. As with any interpretation of images, the quality of images can make a significant impact on the ability to accurately and precisely perform measurements. A significant number of the radiographs in our study were collected before advent of an electronic medical record and subsequently scanned. The loss of resolution and introduction of image artifact likely made clear identification of radiographic landmarks more difficult.

There are several important limitations to our study. First, our study occurred at a single institution. Though the PAO failure rate for the patients in this study is similar to previous studies, factors such as surgeon and institutional variability may limit generalizability of this study.^{3,14,15} Though we attempted to compare symptomatic hips to contralateral asymptomatic hips, this was not possible due to lack of recorded variables for asymptomatic hips. Additionally, exclusion of the outcomes of the 12 patients lost to follow up may have affected statistical analysis. There is also a paucity of data regarding soft tissue laxity. Many of the patients in our study did not undergo imaging such as dynamic ultrasound or magnetic resonance arthrography (MRA) during the preoperative and immediate postoperative periods. These imaging studies would provide valuable insight into the effects of soft tissue laxity in these patients.

Due to the retrospective nature of this study, we could not make predictions about FEAR index changes in the time course before and after surgery. Further prospective studies assessing whether FEAR index changes significantly throughout childhood are warranted. Additionally, our study used proxies for soft tissue integrity. In an attempt to control for this important factor in hip instability, we excluded patients with prior history of hip surgery and those with a previous diagnosis associated with soft tissue disorders. Future studies could address soft tissue laxity by investigating correlation between FEAR index and dynamic ultrasound measurements of the hip or MRA. In particular, studies should focus on MRA as this is the standard first step in determining hip instability.

Section 6: Acknowledgements

The authors are grateful to the following individuals who facilitated the IRB, review, and statistical analysis processes:

Patricia Miller
Roya Dastjerdi
Shanyce Hanson

References

1. McAuley JP, Szuszczewicz ES, Young A, Engh CAS Sr. Total hip arthroplasty in patients 50 years and younger. *Clin Orthop Relat Res.* 2004 Jan;418:119-25.
2. Wyatt M, Weidner J, Pfluger D, Beck M. The Femoro-Epiphyseal Acetabular Roof (FEAR) Index: A New Measurement Associated With Instability in Borderline Hip Dysplasia? *Clin Orthop Relat Res.* 2017 Mar;475(3):861-869.
3. Wells J, Schoenecker P, Duncan S, Goss CW, Thomason K, Clohisy JC. Intermediate-Term Hip Survivorship and Patient-Reported Outcomes of Periacetabular Osteotomy: The Washington University Experience. *J Bone Joint Surg Am.* 2018 Feb 7;100(3):218-225.
4. Nawabi DH, Degen RM, Fields KG, McLawhorn A, Ranawat AS, Sink EL, Kelly BT. Outcomes after arthroscopic treatment of femoroacetabular impingement for patients with borderline hip dysplasia. *Am J Sports Med.* 2016;44:1017–1023
5. Domb BG, Stake CE, Lindner D, El-Bitar Y, Jackson TJ. Arthroscopic capsular plication and labral preservation in borderline hip dysplasia: two-year clinical outcomes of a surgical approach to a challenging problem. *Am J Sports Med.* 2013;41:2591–2598.
6. Wells J, Millis M, Kim YJ, Bulat E, Miller P, Matheney T. Survivorship of the Bernese Periacetabular Osteotomy: What Factors are Associated with Long-term Failure? *Clin Orthop Relat Res.* 2017 Feb; 475(2):396-405.
7. Tönnis D. Congenital dysplasia and dislocation of the hip in children and adults. New York: Springer; 1987.
8. Tönnis D, Heinecke A. Acetabular and femoral anteversion: relationship with osteoarthritis of the hip. *J Bone Joint Surg Am.* 1999 Dec;81(12):1747-70.
9. Lee CB, Millis MB. Patient selection for rotational pelvic osteotomy. *Instr Course Lect.* 2013;62:265–277.
10. Garbuz DS, Awwad MA, Duncan CP. Periacetabular osteotomy and total hip arthroplasty in patients older than 40 years. *J Arthroplasty* 2008;23(7):960-963.
11. Nozawa M, Shitoto K, Matsuda K, Maezawa K, Kurosawa H. Rotational acetabular osteotomy for acetabular dysplasia. A follow-up for more than ten years. *J Bone Joint Surg Br.* 2002;84:59–65. doi: 10.1302/0301-620X.84B1.12299.
12. Ito H, Matsuno T, Minami A. Rotational acetabular osteotomy through an Ollier lateral U approach. *Clin Orthop Relat Res.* 2007;459:200–206. doi: 10.1097/BLO.0b013e31803b942a.

13. Ito H, Tanino H, Yamanaka Y, Minami A, Matsuno T. Intermediate to long-term results of periacetabular osteotomy in patients younger and older than forty years of age. J Bone Joint Surg Am. 2011;93:1347–1354. doi: 10.2106/JBJS.J.01059.
14. Steppacher SD, Tannast M, Ganz R, Siebenrock KA. Mean 20-year followup of Bernese periacetabular osteotomy. Clin Orthop Relat Res. 2008 Jul;466(7):1633- 44. Epub 2008 May 1.
15. Wells J, Millis M, Kim YJ, Bulat E, Miller P, Matheney T. Survivorship of the Bernese periacetabular osteotomy: what factors are associated with long-term failure? Clin Orthop Relat Res. 2017 Feb;475(2):396-405. Epub 2016 May 12.

Figures and Tables

Figure 1- Inclusion and Exclusion Criteria

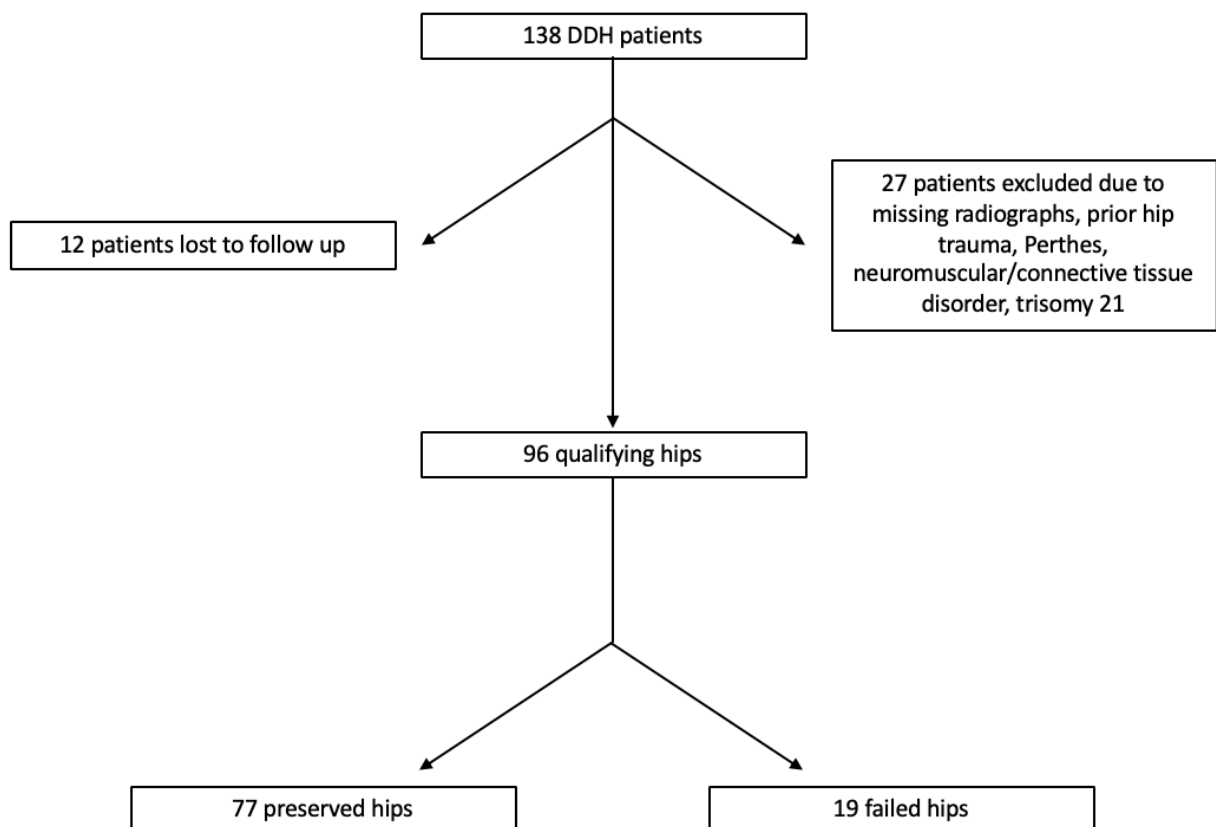


Table 1 Patient Demographics at Time of PAO (N= 108)	
Characteristic	
Age* (<i>yr</i>)	26.6, 9.5-44.5
Male (<i>% of hips</i>)	11.1
Female (<i>% of hips</i>)	88.9
Race- American Indian (%)	2.6
Race -Asian (%)	6.4
Race -Hispanic (%)	2.6
Race -White (%)	85.9
Race -Other (%)	2.6
Height* (<i>in [cm]</i>)	65.3 [166.1], 60-74[152.4-188] 159.4 [72.3], 105-240[47.6-108.9]
Weight* (<i>lb [kg]</i>)	
Body Mass Index* (<i>kg/m²</i>)	26.4, 19.2-41.2
*Values given as mean, range.	

Table 2 Radiographic Correction		
Measurement	Mean (SD)	
	Preoperative	Postoperative
Femoro-Epiphyseal Acetabular Roof (FEAR) Index	13.66 (8.48)	(-) 4.47 (6.52)
Lateral Center Edge Angle	5.41 (6.19)	31.75 (7.24)
Tönnis Angle	25.69 (5.92)	7.74 (5.37)
Anterior Center Edge Angle	6.1 (10.55)	27.41 (6.89)

Table 3 Patient and Hip Characteristics by Outcome

Characteristics	No (%)		P value
	Preserved Hips (N=77)	Failed Hips (N=19)	
Patient Characteristics			
Age >25 yr at surgery	38 (49.4%)	14 (73.7%)	0.024
Female	67 (87%)	18 (94.7%)	0.718
Body mass index (kg/m ²) ≥30	16 (20.8%)	0	0.009
Symptomatic Side			0.959
Left	39 (50.6%)	10 (52.6%)	
Right	38 (49.4%)	9 (47.4%)	
Preoperative radiographic characteristics			
Fear Index			0.739
≤5°	14 (18.2%)	2 (10.5%)	
>5°	63 (81.8%)	17 (89.5%)	
Lateral center edge angle			0.805
<20°	72 (93.5%)	18 (94.7%)	
20°-40°	5 (6.5%)	1 (5.3%)	
≥40°	0	0	
Tönnis Angle			0.065
≤20°	18 (23.4%)	1 (5.3%)	
>20°	59 (76.6%)	18 (94.7%)	
Tönnis Grade			0.008
0-1	64 (83.1%)	10 (52.6%)	
2-3	13 (16.9%)	9 (47.4%)	
Anterior center edge angle			0.289
≤10°	43 (55.8%)	14 (73.7%)	
>10°	22 (28.6%)	4 (21.1%)	
Minimum joint space width <2mm	4 (5.2%)	4 (21.1%)	0.034
Postoperative radiographic characteristics			
Fear Index			0.271
≤5°	74 (96.1%)	17 (89.5%)	
>5°	3 (3.9%)	2 (10.5%)	
Lateral center edge angle			0.247
<20°	2 (2.6%)	2 (10.5%)	
20°-40°	66 (85.7%)	16 (84.2%)	
≥40°	9 (11.7%)	1 (5.3%)	
Tönnis Angle			0.06
≤20°	77 (100%)	18 (94.7%)	
>20°	0	1 (5.3%)	

Tönnis Grade			0.012
0-1	56 (72.7%)	7 (36.8%)	
2-3	20 (26%)	12 (63.2%)	
Anterior center edge angle			
≤10°	0	0	
>10°	52 (67.5%)	17 (89.5%)	
Minimum joint space width <2mm	6 (7.8%)	4 (21.1%)	0.041

Table 4 Patient and Hip Characteristics by Outcome- Multivariable Regression			
Variable	Odds Ratio	95% Confidence Interval	Significance
Age >25 yr at surgery	3.112	0.99-9.78	0.521
Body mass index (kg/m ²) ≥30	0.52	0.048-5.629	0.591
Preoperative Tönnis Grade	3.016	0.94-9.72	0.643
0-1	-	-	Ref
2-3	3.613	1.21-10.01	0.042*
Preoperative Minimum joint space width <2mm			
Postoperative Tönnis Grade			
0-1	-	-	Ref
2-3	15.5	2.12-11.35	0.007*
Postoperative Minimum joint space width <2mm	9.046	1.43-6.54	0.031*
* Statistically significant differences (p< 0.05) on multivariable regression are bolded			

Table 5 Tönnis Classification	
Grade 0	No sign of OA
Grade 1	Sclerosis of head and acetabulum, mild joint space narrowing, slight joint margin lipping, no or minor loss of head sphericity
Grade 2	Small head/acetabulum cysts, moderate joint space narrowing, moderate loss of head sphericity
Grade 3	large head/acetabulum cysts, severe joint space narrowing/joint obliteration, severe head deformity