



# Recommendations for Cardiovascular Magnetic Resonance in Adults with Congenital Heart Disease from the Respective Working Groups of the European Society of Cardiology

## Citation

Kilner, Philip J., Tal Geva, Harald Kaemmerer, Pedro T. Trindade, Juerg Schwitter, and Gary D. Webb. 2010. Recommendations for cardiovascular magnetic resonance in adults with congenital heart disease from the respective working groups of the European Society of Cardiology. *European Heart Journal* 31(7): 794-805.

## Published Version

doi://10.1093/eurheartj/ehp586

## Permanent link

<http://nrs.harvard.edu/urn-3:HUL.InstRepos:8123177>

## Terms of Use

This article was downloaded from Harvard University's DASH repository, and is made available under the terms and conditions applicable to Other Posted Material, as set forth at <http://nrs.harvard.edu/urn-3:HUL.InstRepos:dash.current.terms-of-use#LAA>

## Share Your Story

The Harvard community has made this article openly available.  
Please share how this access benefits you. [Submit a story](#).

[Accessibility](#)

# Recommendations for cardiovascular magnetic resonance in adults with congenital heart disease from the respective working groups of the European Society of Cardiology

Philip J. Kilner<sup>1\*†</sup>, Tal Geva<sup>2</sup>, Harald Kaemmerer<sup>3‡</sup>, Pedro T. Trindade<sup>4‡</sup>, Juerg Schwitter<sup>5†</sup>, and Gary D. Webb<sup>6‡</sup>

<sup>1</sup>CMR Unit, Royal Brompton Hospital, London SW3 6NP, UK; <sup>2</sup>Division of Non-Invasive Imaging, Harvard Medical School, Children's Hospital Boston, Harvard Medical School, Boston, MA, USA; <sup>3</sup>Department of Pediatric Cardiology and Congenital Heart Disease, Deutsches Herzzentrum, Munich, Germany; <sup>4</sup>Cardiovascular Center, University Hospital, Zurich, Switzerland; <sup>5</sup>University Hospital, Lausanne, Switzerland; and <sup>6</sup>Cincinnati Children's Hospital, Cincinnati, OH, USA

Received 27 August 2009; revised 9 November 2009; accepted 7 December 2009; online publish-ahead-of-print 11 January 2010

This paper aims to provide information and explanations regarding the clinically relevant options, strengths, and limitations of cardiovascular magnetic resonance (CMR) in relation to adults with congenital heart disease (CHD). Cardiovascular magnetic resonance can provide assessments of anatomical connections, biventricular function, myocardial viability, measurements of flow, angiography, and more, without ionizing radiation. It should be regarded as a necessary facility in a centre specializing in the care of adults with CHD. Also, those using CMR to investigate acquired heart disease should be able to recognize and evaluate previously unsuspected CHD such as septal defects, anomalously connected pulmonary veins, or double-chambered right ventricle. To realize its full potential and to avoid pitfalls, however, CMR of CHD requires training and experience. Appropriate pathophysiological understanding is needed to evaluate cardiovascular function after surgery for tetralogy of Fallot, transposition of the great arteries, and after Fontan operations. For these and other complex CHD, CMR should be undertaken by specialists committed to long-term collaboration with the clinicians and surgeons managing the patients. We provide a table of CMR acquisition protocols in relation to CHD categories as a guide towards appropriate use of this uniquely versatile imaging modality.

## Keywords

Adult congenital heart disease • Cardiovascular magnetic resonance • Imaging • Tetralogy of Fallot • Transposition of the great arteries • Atrial septal defect • Ventricular septal defect • Aortic coarctation

## Introduction

This is a consensus document, commissioned, and approved by the Nucleus members of the European Society of Cardiology Working Groups for cardiovascular magnetic resonance (CMR) and grown-up congenital heart disease (GUCH). Its aim is to provide information and explanations regarding the clinically relevant options, strengths, and limitations of CMR in adult congenital heart disease (ACHD). It is based on the experience of the authors supported, where available, by references to published research, and should be read in conjunction with previously published 'Clinical indications for cardiovascular magnetic resonance'.<sup>1</sup>

Advances in paediatric cardiology and cardiac surgery have enabled the survival into adulthood of most patients born with congenital cardiovascular malformations. This has led to the establishment of the cardiological sub-specialty of ACHD or GUCH.<sup>2,3</sup> Many ACHD/GUCH patients have undergone palliative or reparative surgery earlier in life.<sup>4</sup> The operations performed for more complex malformations are rarely curative, in which case lifelong follow-up is generally required to optimize the quality and span of life. As patients survive into adulthood, they may need intervention or surgery for residual haemodynamic lesions, they are at risk of arrhythmias secondary to structural heart disease, and they are also susceptible to acquired heart disease. It is important for

\* Corresponding author. Tel: +44 207 351 8808, Fax: +44 207 351 8816, Email: p.kilner@rbht.nhs.uk

†Representing the CMR Working Group of the European Society of Cardiology.

‡Representing the GUCH Working Group of the European Society of Cardiology.

Published on behalf of the European Society of Cardiology. All rights reserved. © The Author 2010. For permissions please email: journals.permissions@oxfordjournals.org. The online version of this article has been published under an open access model. Users are entitled to use, reproduce, disseminate, or display the open access version of this article for non-commercial purposes provided that the original authorship is properly and fully attributed; the Journal, Learned Society and Oxford University Press are attributed as the original place of publication with correct citation details given; if an article is subsequently reproduced or disseminated not in its entirety but only in part or as a derivative work this must be clearly indicated. For commercial re-use, please contact journals.permissions@oxfordjournals.org

imaging specialists to understand the underlying malformations, the evolving operative procedures used,<sup>5,6</sup> the possible complications, and the questions that need to be addressed for decision making on management or re-intervention.

The versatility and comprehensiveness of CMR<sup>7,8</sup> offers numerous investigative possibilities, but this also presents challenges. The relatively high costs of CMR should be weighed against the costs of less fully informed management.

## Strengths and limitations of cardiovascular magnetic resonance in congenital heart disease

- Unrestricted access to cardiovascular anatomy and function, including the systemic and pulmonary venous connections, the right ventricle (RV) and pulmonary arteries, and the whole aorta, without ionizing radiation.
- Well suited for repeated, life-long follow-up investigation, if needed.
- Versatility, including measurements of biventricular size and function regardless of chamber geometry, measurements of flow volumes, characterization of tissues, and assessment of myocardial function, viability, and perfusion, when required.
- Applicable in women with CHD during pregnancy, but without gadolinium contrast agent, unless essential.
- However, electrocardiogram (ECG)-gated cine images and flow maps are typically acquired over a breath-hold and not in real time. Because of the acquisition period and the typical dimensions of the voxels, thin mobile structures may not be well seen.
- Experience is needed for appropriate velocity acquisition and interpretation (see below).
- Cardiovascular magnetic resonance lacks the portability of echo and is not available during open heart surgery.
- Implanted pacemakers and defibrillators generally preclude CMR (see below).

## Other key imaging modalities

- **Chest X-ray** (postero-anterior  $\pm$  lateral): the periodic use of chest X-ray provides an inexpensive and inclusive overview for serial comparison of heart size, lung parenchyma, pulmonary vascularity, and the thoracic skeleton, with only a small dose of ionizing radiation.
- **Echocardiography**: transthoracic echocardiography, and/or transesophageal when indicated, remains the first-line cardiovascular imaging modality in patients with CHD, although suboptimal acoustic access can be problematic after previous cardiovascular surgery. Echocardiography is preferable to **CMR**: for the identification of patent foramen ovale, structural abnormalities of valve leaflets, and their suspensory apparatus and infective endocardial vegetations.
- **Computed tomography** (CT): offers excellent spatial resolution and relatively unrestricted access in much shorter acquisition times than CMR. Computed tomography is well suited

for imaging the epicardial coronary arteries and their relations to adjacent structures or conduits.<sup>9</sup> Electrocardiogram-gated cine CT allows measurements of biventricular size and function, although at a lower temporal resolution than CMR, and subject to adequate opacification of each intraventricular blood volume.<sup>10,11</sup> In patients with a pacemaker or implantable cardioverter defibrillator, CT provides an alternative to CMR. The main drawback of CT is exposure to ionizing radiation and its associated risk of cancer.<sup>12–15</sup> This risk is dose-, age-, and gender-dependent and makes repeat CT examinations or studies in young patients unattractive. Other drawbacks compared with CMR include less versatile tissue characterization, an inferior ability to evaluate cardiovascular physiology and reliance on radio-opaque contrast agent.

## When to use cardiovascular magnetic resonance as an adjunct to echocardiography in clinical practice

- When an echocardiographic study is suboptimal and unable to provide images and measurements of sufficient quality to inform clinical management.
- When echo measurements are borderline or ambiguous: ventricular volumes and ejection fractions may be critical to management, for example in the setting of volume overload, and the same applies to the quantification of valvular regurgitation. When the values provided by echo are borderline or ambiguous, CMR should be used in to corroborate or amend the echo values before making clinical decisions.
- Where CMR usually informs management more effectively
  - Evaluation of systemic and pulmonary veins (anomalous connection or obstruction).
  - Quantification of RV volumes and ejection fraction, for example after repair of tetralogy of Fallot (ToF).
  - Evaluation of the right ventricular outflow tract (RVOT), RV–pulmonary artery (PA) conduits (site of stenosis or aneurysm), and the branch PAs.
  - Quantification of pulmonary regurgitation (PR).
  - Quantification of shunts by measurements of flow in the ascending aorta and pulmonary trunk.
  - Evaluation of the entire aorta (aneurysm, dissection, coarctation).
  - Aorto-pulmonary collaterals and arterio-venous malformations (but CT gives better spatial resolution).
  - Coronary anomalies and coronary artery disease, including possible assessment of viability and perfusion (but CT is superior for non-invasive coronary angiography).
  - Detection and quantification of myocardial fibrosis in the left ventricle (LV) and RV by late gadolinium enhancement (LGE).<sup>16</sup> However, enhancement of the RV–LV insertion regions is a common, non-specific finding where one or both ventricles are hypertrophied or dilated and of doubtful clinical significance.

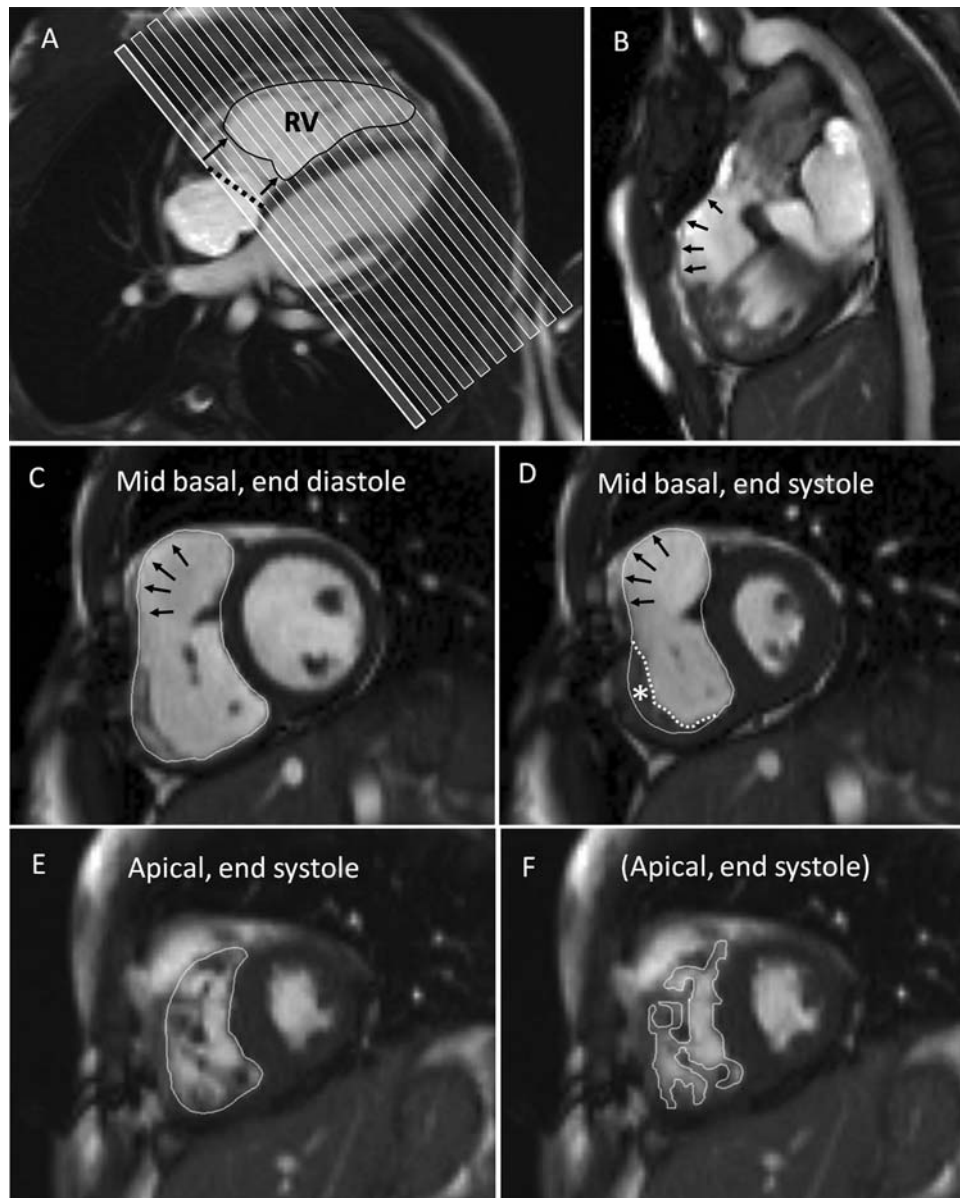
- Quantification of myocardial mass. Delineating the myocardium of the LV is relatively straightforward, but that of the RV is more challenging due to a greater proportion of trabeculated myocardium (Figure 1), the extent of which varies between individuals.
- Evaluation of intra- and extra-cardiac masses.
- Tissue characterization (fibrosis, fat, iron loading, etc.).

## General recommendations for cardiovascular magnetic resonance in adult congenital heart disease

- **Location of CMR resources:** A dedicated CMR service should be regarded as an indispensable facility, complementary to echocardiography, in a centre specializing in the care of ACHD.<sup>3,4,17,18</sup>
- **Training in CMR of ACHD:** CMR studies in ACHD should be supervised and reported by appropriately trained specialists<sup>19,20</sup> committed to long-term collaboration with the cardiologists and surgeons who manage ACHD patients. Level 2 and preferably Level 3 training in CMR is required<sup>21</sup> which would ideally include the supervised interpretation of 150 adult congenital CMR studies, having been present at the scan for at least 50 of these. Such experience is needed for appropriate optimization of acquisition protocols with respect to the patient, the clinical questions asked and the CMR system used.<sup>8</sup>
- **Recognition of previously unsuspected CHD in adults:** The clinicians and technicians who use CMR for the investigation of acquired heart disease should be taught to recognize and assess previously unsuspected congenital abnormalities.
- **Baseline CMR:** Many ACHD patients benefit from at least one CMR study. A CMR study can provide a baseline for future reference and may identify unexpected anomalies, previously overlooked or misinterpreted.
- **Follow-up CMR:** Echocardiography is generally suitable for routine follow-up, but CMR may be indicated if change is suspected. Where serial CMR studies are required, intervals between scans depend on the risk of the condition, the expected rate of change, and the accuracy of measurement in a particular centre. Intervals of 3 years or more are appropriate in most cases, but earlier restudy may be indicated by the onset or progression of symptoms, or the presence of a lesion liable to rapid progression.
- **Biventricular volume and function measurements:** CMR has emerged as the reference standard modality for quantitative assessment of biventricular volumes and mass.<sup>22–24</sup> The reproducibility of LV measurements is excellent.<sup>25</sup> Although measurements of the RV are challenging, studies have shown good reproducibility.<sup>26,27</sup> In routine clinical practice, however, measurements of biventricular size and function by CMR are time consuming, are not easy to achieve reproducibly, requiring dedicated software and a meticulous and clearly defined technique (Figure 1). In the interests of time and reproducibility, tracing of the RV boundary within the relatively thin compact myocardial layer may be preferable to attempted tracing within

the trabeculations.<sup>28</sup> However, semi-automated methods that identify blood-myocardial boundaries may be a practicable, if not directly comparable, alternative.<sup>29</sup> Whichever approach is used, it is crucial that longitudinal comparisons, and comparisons with published normal ranges, are based on comparable methods of acquisition and analysis. Contour data for volumetric analysis should ideally be stored in a database and remain available for comparison at the time of a subsequent study.

- **Data storage, access, analysis, and display:** The ability to access and review the wealth of structural and functional information contained in a CMR data set is crucial. Relevant staff should have access, with appropriate data security and confidentiality measures, to an image storage server from their own computer, equipped with software for CMR review and measurement. Analyses of biventricular function and flow should follow specified methods in a particular centre. Results should ideally be entered in a database, which, as it accumulates, provides measurement ranges, divisible into clinical categories, against which the results in a particular patient may be assessed. Facilities for access to and display of CMR data sets should be available in rooms for multidisciplinary discussions of patient management.
- **Comprehensive CMR acquisition in ACHD:** Except in straightforward cases where the questions to be answered are well defined,<sup>8</sup> it is prudent in a baseline or pre-surgical CMR study to perform a comprehensive examination that will allow review of the structure and function of the myocardium, valves, and vessels through all regions of the heart and mediastinum. Contiguous stacks of transaxial and/or coronal cine images can provide this. Dynamic contrast enhanced angiography or non-contrast 3D imaging can also be valuable, although they do not, on their own, yield cyclic functional information.
- **Magnetic field strength:** Most clinical and research experience of CMR in ACHD has been at 1.5 T, and this remains the field strength with relatively well tried and robust acquisition sequences. Higher field, 3 T systems offer better signal-to-noise, with potential advantages in terms of rapidity of acquisition or image quality, particularly for contrast enhanced angiography and myocardial perfusion imaging. However, these theoretical advantages have yet to be shown to deliver improved diagnostic performance.<sup>30</sup>
- **Catheter investigation and intervention combined with CMR:** A promising strength of this combination is improved accuracy of measurement of pulmonary vascular resistance based on simultaneous measurements of pulmonary flow by CMR and pressure by catheter transducer.<sup>31</sup> Work is progressing in the use of CMR for catheter and device guidance, with the potential advantages of 3D localization, tissue characterization and the avoidance or reduction of ionizing radiation.<sup>32</sup> However, until further advances in device compatibility and CMR technology are achieved, X-ray guidance using adjoining space and equipment remains a necessary adjunct. This field remains one for research, requiring sufficient allocation of time and money, rather than for mainstream clinical use.<sup>33,34</sup> Apart from this, the availability of CMR as well as echocardiography reduces the need for diagnostic catheterization and expedites the planning of percutaneous or surgical interventions.



**Figure 1** Right ventricular volume measurement in CHD: several regions are challenging and need consistent approaches for comparison between studies. The images are from a patient after repair of tetralogy of Fallot with infundibular resection. (A) The short-axis stack (typically 6 mm slice thickness with 4 mm gaps) is shown relative to four-chamber cine. The most basal short-axis cine should be located just within the basal myocardium of the RV and LV at end diastole. However, the tricuspid annular plane (dotted line) may lie oblique to this slice, and usually moves through the first and often the second slice during systole. Care is needed to delineate areas of the ventricular but not the atrial cavities in the more basal slices. (B) A thin, akinetic region of the RVOT (arrowed in the sagittal RVOT view) should be regarded as part of the RV up to the (expected) level of the pulmonary valve. (C) In a mid-basal short-axis slice, the arrows indicate an akinetic region. A relatively smooth contour is drawn immediately inside the compact myocardium of the free wall, outside the trabeculations. (D) However, at end systole, hyper-trophied trabeculations of the muscular part of the free wall may appear to merge (asterisk). The boundary line can still be located just inside the compact layer after viewing in cine mode. Alternatively, the dotted line drawn within the trabecular layer would give a slightly smaller end-systolic blood volume. (E) Trabeculations are numerous towards the apex of the RV and partial volume averaging blurs boundaries, so delineation outside the blood and trabeculations is probably the most reproducible approach. (F) Alternatively, tracing around the visible trabeculations at all levels may be more accurate, although not necessarily more reproducible between investigators and studies. The methods chosen need to be consistent for longitudinal comparison.

## Cardiovascular magnetic resonance safety considerations

- **Metallic objects and implantable devices:** No patient or accompanying person with a pacemaker or implanted defibrillator should approach the magnet, nor anyone with a ferromagnetic clip or steel fragment that might lie adjacent to soft tissue of the brain or retina. However, almost all sternal wires, clips, stents, occlusion devices, and prosthetic valves within the chest are safe in a 1.5 T magnet, causing only local image artefact. Newer devices that cause less artefacts may facilitate follow-up by CMR. Safety information relating to specific implants or situations should, however, be consulted, as necessary.<sup>35,36</sup> Vigilance and strict institutional safety procedures are needed to prevent medical staff or patients inadvertently approaching the magnet with ferromagnetic objects such as a gas cylinder, wheelchair, trolley, scissors, or other equipment that could cause harm to themselves or a patient in the magnetic field.
- **Gadolinium chelates:** are contrast agents widely used for CMR angiography or myocardial viability studies. It is generally associated with less adverse reactions than iodine-based agents, but in patients with renal failure, especially if advanced, gadolinium administration has been linked to cases of the severe complication of nephrogenic systemic fibrosis.<sup>37–39</sup> In cases where contrast agent is indicated, renal function needs to be tested, and the potential risks weighed against the benefits of contrast enhanced rather than non-contrast CMR imaging.<sup>40</sup>

## Other limitations and considerations

- **Claustrophobia and patient compliance:** CMR studies require the patient to lie still in the tubular bore of a magnet, which may not be tolerated by a small percentage of patients (~5%) due to claustrophobia. Anxiolytics such as oral benzodiazepine can be considered in individuals with mild or moderate claustrophobia. Limited ability to comply with breath-hold instructions can be an added problem in patients with Down syndrome or other cognitive or behavioural issues, although this is less often a problem in the adult than the paediatric population.<sup>41</sup> Neither sedation nor anaesthesia can be recommended for CMR of ACHD, unless undertaken in an appropriately equipped and staffed centre that maintains regular relevant experience in accordance with local practice guidelines. The relative safety and diagnostic efficacy of anaesthesia with intubation compared with sedation remains almost impossible to determine given the rarity but potential severity of the hazards in the CMR environment. Alternative imaging by repeat echocardiography or by CT may be preferable.
- **Intravascular pressures and jet velocities:** CMR does not, on its own, provide measurements of pressure. Pressure differences across stenoses of heart valves or large vessels can be estimated, by applying the modified Bernoulli equation, from measurements of jet velocities. However, CMR jet velocity mapping requires skill. The acquisition slice, with adequate

temporal and spatial resolution and appropriate velocity encoding range (VENC), should be located to transect the core of the jet immediately downstream of the orifice. The limitations of the technique need to be recognized. The velocities of narrow, eccentric jets through mildly regurgitant tricuspid, or pulmonary valves, which may be used in Doppler echocardiography for estimations of RV or PA pressure, are unlikely to be measured accurately by CMR. Nevertheless, CMR visualization of any RV hypertrophy, ventricular septal flattening, or dilatation of the PAs combined with their limited systolic expansion, means that the presence and approximate severity of pulmonary hypertension can be inferred from cine images.

- **Flow measurements:** The measurement of volume flow in a large vessel (*Figure 2*) is potentially an unrivalled strength of CMR.<sup>42</sup> For derived calculations of regurgitant fraction or shunt flow,<sup>43</sup> the measurements of velocity through a plane transecting a large vessel require a high standard of accuracy which, due to slight but cumulative background phase offset errors, may not be achievable without correction. Correction by means of the subsequent phase contrast imaging of a static phantom and image subtraction is effective, but takes time.<sup>44</sup> This approach is recommended to test a system for clinical use and to check any unexpected result. Image correction based on phase offset elimination across regions of signal from static tissues has been implemented,<sup>45</sup> but needs to be validated in clinical practice.
- **Choice of imaging parameters:** The complexity of CMR acquisition and image reconstruction means that the quality of an investigation depends on the optimization of multiple parameters. This applies particularly to velocity mapping, inversion recovery acquisitions used for myocardial fibrosis imaging after gadolinium injection,<sup>46</sup> stress perfusion imaging,<sup>47</sup> and coronary angiography. In CHD, the physician generally needs to be present during acquisition to adapt the choice of image planes and sequences to the anatomy and pathophysiology of a specific patient.

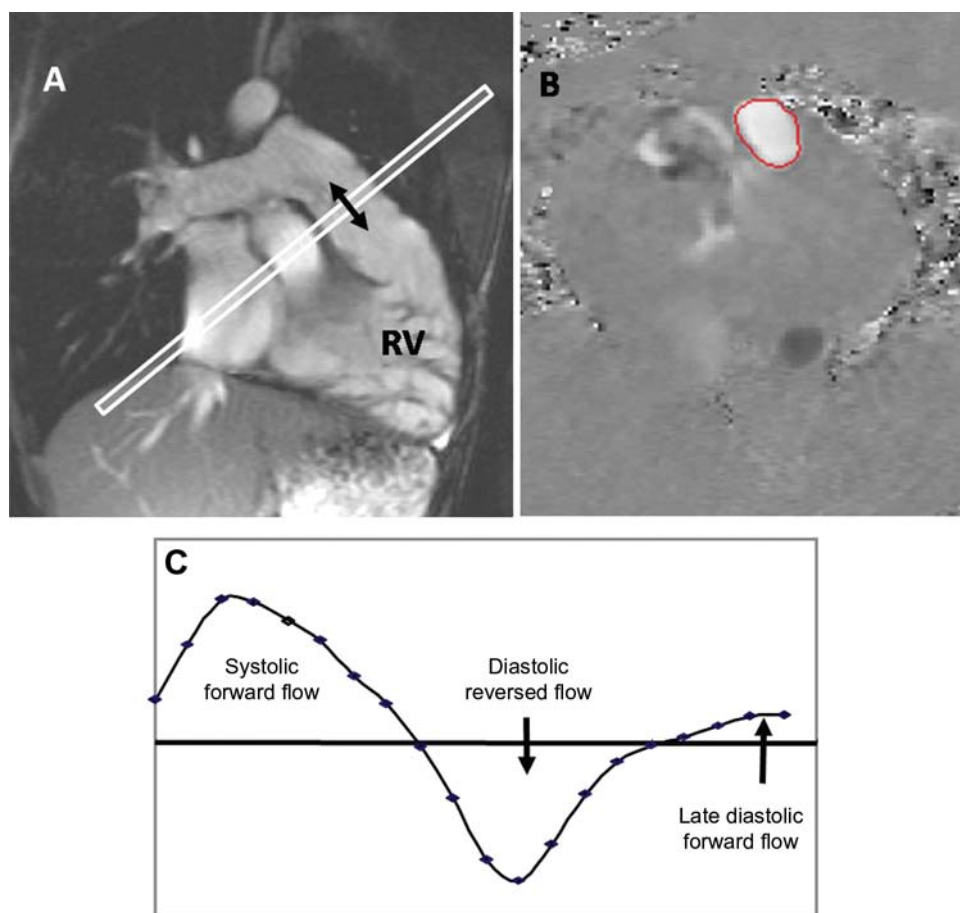
## Patient preparation

- Knowledge from the case notes of the patient's cardiac history, previous catheter, or surgical procedures is important for optimal planning and interpretation of CMR studies in ACHD. Review of echocardiographic images may help towards the choice of CMR acquisitions most likely to answer specific remaining questions.
- Care is needed to achieve an ECG signal suitable for consistent cardiac gating when in the magnetic field.
- In patients with kyphoscoliosis, care must be taken to achieve a comfortable position and to acquire key information as rapidly as possible.

## Specific indications

### Congenital mitral or aortic valve disease, before and after surgery

Although echocardiography remains the first line of investigation,<sup>48</sup> CMR can contribute to the measurement of regurgitation and the assessment of myocardial or other pathology associated with heart



**Figure 2** Pulmonary regurgitation measured by through-plane velocity mapping in repaired tetralogy of Fallot. (A) Cine imaging aligned with the RVOT showed no effective pulmonary valve, with unobstructed and expansile pulmonary arteries. (B) Mapping of velocities through a plane transecting the MPA showed (C) systolic forward flow, diastolic reversed flow, and late diastolic forward flow with atrial systole.

valve disease (Table 1; see also online supplementary notes to Table 1). In patients with bicuspid aortic valve (AoV), it allows assessment of any ascending aortic ectasia, aneurysm, or dissection. Regurgitant or stenotic jets are visible on cine imaging, although appearances depend on the jet size and characteristics and on the relative location and orientation of the imaging slice. The visibility extent of a jet does not necessarily relate to the severity of a lesion. Planimetry of an orifice, or of the cross-section of the jet immediately downstream of the orifice, is feasible in some but not all cases, depending on the structure of the jet and the relative thickness and location of the imaging slice. Jet velocity mapping can contribute to quantification of stenosis, but velocities may be underestimated if the slice is not optimally located, or if the coherent core of the jet is too narrow or fragmented to contain several whole voxels. Quantification of regurgitation of the inflow valves is feasible using ventricular stroke volume difference in the case of a single valve lesion, or by subtraction of the outflow volume, measured by mapping velocities through a plane transecting the relevant great artery, from the corresponding ventricular stroke volume.<sup>43</sup> For identification of tethering, prolapse or failure of coaptation of all parts of the mitral (or tricuspid) leaflets, a contiguous stack of cine images aligned perpendicular to the central part of the line of coaptation is recommended.<sup>49,50</sup>

## Ross operation

The commonest complications are stenosis or regurgitation of the RV-to-PA homograft conduit. Stenosis may be due to shrinkage and calcification of the homograft tube, valve, or suture lines. Any jet formation should be visualized by cine imaging and quantified by jet velocity mapping, and regurgitation measured by through-plane velocity mapping.<sup>51,52</sup> The autograft valve in the aortic position should also be assessed for possible dilatation and regurgitation particularly in the second decade after operation.<sup>53</sup> Possible sub-valvular pseudo-aneurysm formation at the proximal suture line should be sought. Visualization of the re-implanted coronary arteries may be included, using a 3D steady state free precession (SSFP) acquisition. If there is a question of post-surgical LV ischaemia or regional wall motion abnormality, perfusion imaging, and/or LGE may be considered.

## Aortic coarctation

Cardiovascular magnetic resonance allows assessment of restenosis or aneurysm formation in the region of coarctation repair, as well as any associated pathology such as stenosis or regurgitation of a bicuspid AoV, aortopathy, or LV hypertrophy.<sup>54</sup>

**Table 1** Cardiovascular magnetic resonance acquisition options in adults with congenital heart disease

CMR acquisition options in CHD (see accompanying notes)		1. Multislice scouts x 3	Cines and stacks of cines									Velocity mapping				3D SSFP		CEMRA			23. Late Gd enhancement	24. Myocardial perfusion			
			2. VLA and HLA	3. Short axis stack	4. 4ch, LVOT(s), AoV	5. Aortic arch cine(s)	6. RVOT cines	7. PA cines	8. Transaxial stack	9. Coronal stack	10. Atrial SA stack	11. Mitral stack	12. MPA flow	13. Aortic flow	14. Jet velocity series	15. ASD flow area	16. TR jet area	17. PR jet area	18. Global 3D	19. Coronary MRA			20. Pulmonary arteries	21. Pulmonary veins	22. Aortic Arch
<i>Italics = CMR study recommended</i>																									
Left heart	Mitral regurgitation																								
	Mitral stenosis																								
	Aortic stenosis																								
	Aortic regurgitation																								
	Ross operation																								
	Ao Coarctation																								
	Marfan disease																								
Right heart	Tricuspid regurgitation																								
	Ebstein																								
	DCRV																								
	Fallot, repaired																								
	PS/PR																								
	RV-PA conduit																								
	MAPCAs																								
Shunts	Pulmonary hypertension																								
	ASD																								
	VSD																								
	PAPVC																								
	PDA																								
	B-T shunt (etc.)																								
	Eisenmenger PHt																								
TGA	Mustard/Senning																								
	Arterial switch op.																								
	Rastelli op.																								
	CCTGA																								
Fontan	Fontan op.																								
Complex	Complex CHD																								
Coronary artery anomalies																									

See online supplementary notes for explanation of the acquisition options.

CEMRA, contrast enhanced magnetic resonance; 4ch, four-chamber (plane); VLA, vertical long-axis (plane); HLA, horizontal long-axis; LVOT, left ventricular outflow tract; SA, (ventricular) short-axis (plane); MPA, main pulmonary artery; ASD, atrial septal defect; TR, tricuspid regurgitation; PR, pulmonary regurgitation; MAPCAs, major aortopulmonary collateral arteries; PAPVC, partial anomalous pulmonary venous connection; CCTGA, congenitally corrected transposition of the great arteries.

Cardiovascular magnetic resonance is also helpful with a view to balloon dilatation and stenting or surgery,<sup>55,56</sup> with contrast enhanced angiography providing 3D visualization of arch geometry, any aneurysm formation or collateral vessels. After stent placement, depending on the composition of the stent material, CT may provide a more effective assessment and should be considered 3 months after such an intervention. Collateral flow can be quantified by comparing through-plane measurements of flow immediately proximal to the stenosis and at the level of the diaphragm. A decrease of  $\geq 10\%$  is expected physiologically, whereas an increase implies collateral flow rejoining the descending thoracic aorta.<sup>57</sup> The aortic arch with coarctation may not lie in a single plane, and when using cine imaging and velocity mapping, it is necessary to identify planes best suited for the depiction and measurement of any jet flow through the coarctation. The presence of diastolic prolongation of forward flow, or a diastolic tail, is a useful sign of significant (re-)coarctation, and can be demonstrated by plotting a velocity–time curve of jet flow beyond the

coarctation.<sup>58</sup> Berry aneurysms of the circle of Willis or other cerebral vessels occur in up to 10% of patients with coarctation bearing the risk of rupture.<sup>59</sup> As rupture of a cerebral aneurysm is associated with high mortality, screening for cerebrovascular aneurysms is possible by an additional magnetic resonance imaging study which may be advisable if symptoms develop.

## Marfan syndrome and other connective tissue disorders

Cardiovascular magnetic resonance studies allow measurement of the aortic root and of any aortic regurgitation. They allow measurements of the entire aorta and its major branches and of ventricular and mitral valve function. It is important to check for aortic dissection, which may be small and focal, for example by using a 3D contrast enhanced magnetic resonance or b-SSFP acquisition. Moreover, CMR can detect abnormal aortic elastic properties in affected patients before dilation occurs.<sup>60–62</sup> Magnetic

resonance imaging of the lumbosacral spine may be used to identify dural ectasia.<sup>63</sup> Cerebral contrast enhanced magnetic resonance can be helpful in patients with Loeys-Dietz syndrome.

## Ebstein anomaly and tricuspid regurgitation

A stack of transaxial cines, supplemented by four-chamber and other oblique cines, is recommended for visualizing the RA–RV anatomy in Ebstein patients. Transaxial cines may be suitable for volume measurements of the functional part of the Ebstein RV, which may be hard to delineate in short-axis slices. In spite of atrialization, higher RV volumes than normal may be found in the presence of severe tricuspid regurgitation. The severity of tricuspid regurgitation can be assessed using through-plane velocity mapping, the VENC typically set at 250 cm/s, to depict the cross-section of the regurgitant stream through a plane transecting the jet immediately on the atrial side of the defect. A tricuspid regurgitation jet cross-section, reflecting the regurgitant defect, of  $6 \times 6$  mm or more can be regarded as severe. An atrial septal defect, due to distension and gaping of a PFO, can be present in ~50% of adult Ebstein patients and should be sought with an atrial short-axis cine stack. If present, the resting shunt can be measured by aortic and pulmonary velocity mapping. Cines may show diastolic compression of the LV by the dilated right heart, which can impair LV filling and so limit the cardiac output.

## Repaired tetralogy of Fallot

Cardiovascular magnetic resonance has important contributions to make in the assessment and follow-up of adults with repaired ToF<sup>64</sup> and related conditions,<sup>65,66</sup> including those with RV–PA conduits. Cardiovascular magnetic resonance measurements of RV and LV function (Figure 1), any regional wall motion abnormalities, PR (Figure 2), RVOT obstruction, conduit or PA stenoses, and possible residual shunting all contribute to decisions on management, notably the possibility of pulmonary valve replacement for PR. The pathophysiology of PR differs from that of aortic regurgitation. Free PR, with little or no effective valve function, is common after repair of ToF. It may be tolerated without symptoms for decades and is typically associated with a regurgitant fraction of ~35–45%,<sup>67</sup> which should also be recorded as an indexed regurgitant volume.<sup>68</sup> However, RV dysfunction, arrhythmia, and premature death can result, with respect to which CMR late gadolinium imaging may contribute to risk stratification.<sup>16</sup> In most centres, pulmonary valve replacement is considered in such patients, but when to operate remains controversial, particularly if the patient is asymptomatic and bearing in mind that a homograft replacement may only function effectively for 15 or 20 years, or less.<sup>69–72</sup> Once a conduit is in position, however, progressive stenosis or regurgitation may be treatable by percutaneous placement of a stented valve within the relatively rigid tube of the conduit.<sup>73,74</sup> Cardiovascular magnetic resonance, with contrast angiography, has a role in the selection of patients for such procedures, but so also has CT, which allows the visualization of calcium and the clear delineation the coronary arteries relative to a previously placed conduit.

Studies by Therrien *et al.*<sup>75</sup> and Oosterhof *et al.*<sup>76</sup> compared CMR measurements of RV volumes before and after surgical pulmonary valve replacement. Both groups found reductions of RV volumes after surgery. However, patients with pre-operative indexed RV end-diastolic volumes above  $170 \text{ mL/m}^2$  (or above  $160 \text{ mL/m}^2$  in Oosterhof's study) and end-systolic volumes over  $85 \text{ mL/m}^2$  (or over  $82 \text{ mL/m}^2$ ) failed to recover to the normal RV volume range. Although this may be taken as a guide to RV volumes that should not be exceeded when waiting to replace a pulmonary valve, there are more factors to be considered. Even in the absence of an effective pulmonary valve, the amount of regurgitation depends on factors upstream and downstream. In occasional cases, the regurgitant fraction can exceed 50%.<sup>77</sup> This may be attributable to an unusually large and compliant RV, a large and compliant pulmonary trunk and PA branches whose recoil contributes to the regurgitation,<sup>78</sup> branch PA stenosis or elevated peripheral resistance limiting the distal escape of flow, or combinations of these.<sup>79</sup> In the case of unilateral branch PA stenosis, comparison of right pulmonary artery and left pulmonary artery flow volumes can be informative. Contrast enhanced 3D angiography may be used for the visualization of PA branch stenosis, and appropriately aligned cines can visualize jet formation and the reduced systolic expansion of PA branches distal to a stenosis that is obstructive enough to require relief, either percutaneously or at the time of surgery. Measurements of relative branch PA flow and the visualization of distal PA expansion may also contribute to the assessment of patency after stent placement. Tricuspid regurgitation needs to be identified and assessed, as does any residual ventricular septal defect (VSD) patch leak and consequent shunting. Global and regional LV function, and any aortic root dilatation or regurgitation, also need assessment.<sup>80</sup> In summary, the evaluation of repaired ToF requires thorough assessment of the left and right heart, extending to the branch PAs and ascending aorta.

## Double-chambered right ventricle or sub-infundibular stenosis

Results from obstructing muscular bands or ridges between the hypertrophied body or sinus of the RV and the non-hypertrophied infundibulum. It is usually associated with a VSD into the higher pressure RV sinus, close to the tricuspid valve, and may progress during adulthood. It should be possible to identify double-chambered right ventricle (DCRV) echocardiographically, although limited visualization may make it hard to distinguish between a jet through a VSD, the sub-infundibular stenosis and possible infundibular or pulmonary valve stenosis. Cardiovascular magnetic resonance can help to differentiate between these, although flow through the VSD can be hard to detect. The sub-infundibular origin of a DCRV jet, directed into the non-hypertrophied and non-obstructive infundibulum, is generally visible in routine basal short-axis cines.<sup>81</sup>

## Major aortopulmonary collateral arteries

Contrast enhanced 3D CMR angiography is valuable for delineation of all sources of pulmonary blood supply prior to surgical or transcatheter procedures in patients with major aortopulmonary collateral arteries associated with severe pulmonary stenosis

or atresia.<sup>82</sup> However, CT angiography is likely to depict small vessels more clearly.

## Pulmonary hypertension

Cardiovascular magnetic resonance allows assessment of RV size and function, the size of the main and branch pulmonary arteries, flow measurement in the aorta or main PA for calculation of indexed cardiac output, and to identify anomalies that might contribute to pulmonary hypertension such as patent ductus arteriosus (PDA) or VSD.<sup>83</sup> Contrast enhanced angiography may be used for the identification of thrombo-embolic disease or aorto-pulmonary collateral vessels, although contrast CT offers superior resolution in a shorter time, which may matter in patients with limited breath-holding ability.

## Shunts: atrial septal defect, ventricular septal defect, or patent ductus arteriosus

Cardiovascular magnetic resonance can assess questions remaining, after echocardiography, about the nature of the lesion, the amount of shunting,<sup>43</sup> biventricular size and function, and to detect associated anomalies, notably the possibility of anomalous pulmonary venous drainage.<sup>84–86</sup> Flow through the AoV represents Qs when there is an intracardiac left to right shunt, but Qp when the shunt is through a PDA, with the inverse applying to flow in the pulmonary trunk.<sup>43</sup>

## Transposition of the great arteries treated by atrial switch operation (Mustard or Senning)

Cardiovascular magnetic resonance can assess the atrial pathways and systemic RV function.<sup>87</sup> With experience, cines and velocity maps can be aligned with respect to systemic and pulmonary venous atrial pathways.<sup>66</sup> Comprehensive coverage can, however, be achieved using a stack of contiguous transaxial or coronal cines or a 3D SSFP sequence. Baffle-leaks may not be easy to identify by CMR, the suture line being long and tortuous. The measurement of pulmonary relative to aortic flow (Qp:Qs) may be useful, and any incompetence of the tricuspid valve into the systemic RV needs to be evaluated.

## Transposition of the great arteries treated by arterial switch operation

Cardiovascular magnetic resonance allows assessment of any RVOT or supra-auricular PA stenosis, branch PA stenosis, the neo-AoV, and biventricular function.<sup>5</sup> Previous myocardial infarction or fibrosis can be identified by LGE imaging, and assessment of the patency of the re-implanted coronary arteries and LV perfusion during pharmacological stress may be attempted by CMR.<sup>88</sup>

## Transposition of the great arteries treated by Rastelli operation

Cardiovascular magnetic resonance allows the assessment of possible stenosis or incompetence of the RV-to-PA conduit, the left ventricular outflow tract, of biventricular function, and possible residual shunt.

## Congenitally corrected transposition of the great arteries

This malformation consists of discordant atrio-ventricular and discordant ventriculo-arterial connections. If uncomplicated, the affected patients can occasionally remain symptom free and undiagnosed into adulthood. Associated lesions include dextrocardia, a VSD, (sub-)pulmonary stenosis and Ebstein-like malformation of the left-sided tricuspid valve. The sub-aortic RV is prone to dysfunction and regurgitation of its tricuspid valve.<sup>89</sup> Which ventricle is morphologically 'right' and which is 'left' can be determined from CMR short-axis and four-chamber cines, which show multiple coarse trabeculations, including the moderator band, arising from RV but not the LV side of the septum. Each atrio-ventricular valve and ventriculo-arterial connection should be visualized by appropriately aligned cines. Possible shunting through a VSD should be quantified, and the presence and severity of any (sub-)pulmonary stenosis or tricuspid regurgitation assessed.

## Fontan operations for functionally single ventricle

Fontan operations, generally performed in children with only one effective ventricle, result in a fundamental departure from normal circulatory dynamics.<sup>6</sup> The systemic and pulmonary vascular beds are connected in series downstream of the ventricle, so eliminating shunting at the cost of a critically elevated systemic venous pressure that maintains flow through the lungs. Earlier procedures incorporated the right atrium between the caval veins and pulmonary arteries, whereas total cavo-pulmonary connection, connecting inferior vena cava flow to the PAs via a lateral tunnel or extracardiac conduit, has been favoured in recent years.<sup>5</sup> Cardiovascular magnetic resonance allows careful assessment of the Fontan cavo-pulmonary connections, branch pulmonary arteries, pulmonary veins (which can be compressed by the dilated right atrium of an atrio-pulmonary connection), the ventricle(s), the atrio-ventricular valve(s), the ventricular outflow tract, and any residual leaks or collateral vessels, although artefacts from ferromagnetic occlusion devices, as seen in some older patients, can preclude satisfactory CMR.<sup>90</sup> Comprehensive coverage using a contiguous stack of transaxial cines is recommended, this generally being suitable for the identification of any intra-atrial thrombus or stenosis of the cavo-pulmonary connections. Velocity mapping can be used to assess flow through a suspected cavo-pulmonary narrowing where a peak jet velocity exceeding 1 m/s is likely to represent significant stenosis, and possible shunt flow through aorto-pulmonary collaterals.<sup>91</sup> Should contrast injection for angiography be considered, the timing and distribution of contrast arrival in the PAs and its dilution by non-opacified (inferior) caval flow need to be borne in mind. Non-contrast 3D SSFP imaging, or injection of contrast from a leg, may be preferable. Evaluation of myocardial fibrosis by LGE may be informative in patients with impaired ventricular function.

## Complex congenital heart disease, operated or not

Cardiovascular magnetic resonance allows clarification of anatomy and function, including anomalous vessels, connections, shunts, stenoses, abdominal situs, and possible polysplenia. Comprehensive

cardiac, mediastinal, and upper abdominal coverage using stacks of contiguous transaxial and coronal cines is recommended. Dynamic contrast enhanced angiography and 3D SSFP are also useful. Cine images should be aligned with each inflow and outflow valve, and with any shunt flow, so that connections can be established. Cardiovascular connections are best described according to sequential segmental analysis.<sup>92,93</sup> The relative pre-branch lengths of the left- and right-sided bronchi in coronal slices can provide a useful guide to thoracic situs, if in doubt. To distinguish a morphologically right from a LV, useful signs include the presence of a moderator band and additional coarse trabeculations arising from the RV side of the inter-ventricular septum, but not from its relatively smooth LV side.

## Coronary artery anomalies

The origin and proximal course of the coronary arteries can, in most patients, be visualized by CMR using cardiac gated 3D SSFP angiography, with fat suppression and without contrast agent.<sup>94,95</sup> Either diaphragm navigator or breath-hold acquisitions are used to minimize respiratory blurring. Acquisitions may be repeated in different orientations if necessary. Image quality is dependent on meticulous acquisition technique. However, contrast enhanced multi-detector CT angiography generally gives clearer, more extensive depiction of the coronary arteries.

## Coronary artery disease

In addition to patients subject to myocardial ischaemia secondary to Kawasaki disease or with surgically re-implanted coronaries, acquired atheromatous disease is becoming increasingly important as patients with CHD become older. Computed tomography angiography is superior to CMR for coronary luminography but, without radiation hazard, CMR can give important information on global and regional myocardial function, viability, and perfusion.<sup>96,97</sup>

## Conclusions

After transthoracic echocardiography, which remains the first-line imaging modality in ACHD, the choice of further imaging depends on the clinical questions that remain to be addressed. Besides tissue characterization, the strengths of CMR include comprehensive access and coverage, for example by the use of a stack of transaxial cine images or by dynamic contrast enhanced angiography, and the relatively accurate measurements of biventricular function and volume flow. These are particularly useful in the assessment and follow-up of adults after repairs of ToF, aortic coarctation, and transposition of the great arteries and those with Fontan operations or with operated or unoperated complex malformations. In the authors' view, a dedicated CMR service should be regarded as a necessary facility of a centre specializing in the care of ACHD, and adults who were born with relatively complex CHD should ideally be investigated as well as managed in such a centre. To realize its full potential and to avoid pitfalls, however, CMR of CHD requires appropriate training and experience.

## Supplementary material

Supplementary material is available at *European Heart Journal* online.

## Acknowledgements

We would like to thank Helmut Baumgartner, Folkert Meijboom, other members of the GUCH and CMR Working Groups of the ESC for their contributions during preparation of the manuscript.

## Funding

P.J.K. is supported by the British Heart Foundation. Funding to pay the Open Access publication charges for this article was provided by the CMR and GUCH Working Groups of the European Society of Cardiology.

**Conflict of interest:** none declared.

## References

- Pennell DJ, Sechtem UP, Higgins CB, Manning WJ, Pohost GM, Rademakers FE, van Rossum AC, Shaw LJ, Yucel EK. Clinical indications for cardiovascular magnetic resonance (CMR): Consensus Panel report. *Eur Heart J* 2004;**25**:1940–1965.
- Perloff JK, Warnes CA. Challenges posed by adults with repaired congenital heart disease. *Circulation* 2001;**103**:2637–2643.
- Dearani JA, Connolly HM, Martinez R, Fontanet H, Webb GD. Caring for adults with congenital cardiac disease: successes and challenges for 2007 and beyond. *Cardiol Young* 2007;**17**:87–96.
- Niwa K, Perloff JK, Webb GD, Murphy D, Liberthson R, Warnes CA, Gatzoulis MA. Survey of specialized tertiary care facilities for adults with congenital heart disease. *Int J Cardiol* 2004;**96**:211–216.
- Warnes CA. Transposition of the great arteries. *Circulation* 2006;**114**:2699–2709.
- Gewillig M. The Fontan circulation. *Heart* 2005;**91**:839–846.
- Fratz S, John H, Annika S, Christine B, Eva H, Stefan M, Heiko S. Routine clinical cardiovascular magnetic resonance in paediatric and adult congenital heart disease: patients, protocols, questions asked and contributions made. *J Cardiovasc Magn Reson* 2008;**10**:46.
- Schwittler J. *CMR-Update*. 1st ed. Zurich, Switzerland: Juerg Schwittler; 2008.
- Bluemke DA, Achenbach S, Budoff M, Gerber TC, Gersh B, Hillis LD, Hundley WG, Manning WJ, Printz BF, Stuber M, Woodard PK. Noninvasive coronary artery imaging: magnetic resonance angiography and multidetector computed tomography angiography: a scientific statement from the American Heart Association committee on cardiovascular imaging and intervention of the council on cardiovascular radiology and intervention, and the councils on clinical cardiology and cardiovascular disease in the young. *Circulation* 2008;**118**:586–606.
- Nicol ED, Gatzoulis M, Padley SP, Rubens M. Assessment of adult congenital heart disease with multi-detector computed tomography: beyond coronary lumenography. *Clin Radiol* 2007;**62**:518–527.
- Nicol ED, Kafka H, Stirrup J, Padley SP, Rubens MB, Kilner PJ, Gatzoulis MA. A single, comprehensive non-invasive cardiovascular assessment in pulmonary arterial hypertension: Combined computed tomography pulmonary and coronary angiography. *Int J Cardiol* 2009;**136**:278–288.
- Einstein AJ, Moser KW, Thompson RC, Cerqueira MD, Henzlova MJ. Radiation dose to patients from cardiac diagnostic imaging. *Circulation* 2007;**116**:1290–1305.
- Sadetzki S. Excess lifetime cancer mortality risk attributed to radiation exposure from pediatric computed tomography scan. *Isr Med Assoc J* 2007;**9**:607–609.
- Einstein AJ, Henzlova MJ, Rajagopalan S. Estimating risk of cancer associated with radiation exposure from 64-slice computed tomography coronary angiography. *J Am Med Assoc* 2007;**298**:317–323.
- Gerber TC, Carr JJ, Arai AE, Dixon RL, Ferrari VA, Gomes AS, Heller GV, McCollough CH, McNitt-Gray MF, Mettler FA, Mieres JH, Morin RL, Yester MV. Ionizing radiation in cardiac imaging: a science advisory from the American Heart Association Committee on Cardiac Imaging of the Council on Clinical Cardiology and Committee on Cardiovascular Imaging and Intervention of the Council on Cardiovascular Radiology and Intervention. *Circulation* 2009;**119**:1056–1065.
- Babu-Narayan SV, Kilner PJ, Li W, Moon JC, Goktekin O, Davlouros PA, Khan M, Ho SY, Pennell DJ, Gatzoulis MA. Ventricular fibrosis suggested by cardiovascular magnetic resonance in adults with repaired tetralogy of Fallot and its relationship to adverse markers of clinical outcome. *Circulation* 2006;**113**:405–413.

17. Wernovsky G, Rome JJ, Tabbutt S, Rychik J, Cohen MS, Paridon SM, Webb G, Dodds KM, Gallagher MA, Fleck DA, Spray TL, Vetter VL, Gleason MM. Guidelines for the outpatient management of complex congenital heart disease. *Congenit Heart Dis* 2006;**1**:10–26.
18. Williams RG, Pearson GD, Barst RJ, Child JS, del Nido P, Gersony WM, Kuehl KS, Landzberg MJ, Myerson M, Neish SR, Sahn DJ, Versteppen A, Warnes CA, Webb CL, National Heart, Lung, Blood Institute Working Group on research in adult congenital heart disease. Report of the National Heart, Lung, and Blood Institute Working Group on research in adult congenital heart disease. *J Am Coll Cardiol* 2006;**47**:701–707.
19. Helbing WA, Mertens L, Sieverding L. Recommendations from the Association for European Paediatric Cardiology for training in congenital cardiovascular magnetic resonance imaging. *Cardiol Young* 2006;**16**:410–412.
20. Sanders SP, Colan SD, Cordes TM, Donofrio MT, Ensing GJ, Geva T, Kimball TR, Webb DJ, Silverman NH, Sklansky MS, Weinberg PM. ACCF/AHA/AAP recommendations for training in pediatric cardiology. Task force 2: pediatric training guidelines for noninvasive cardiac imaging endorsed by the American Society of Echocardiography and the Society of Pediatric Echocardiography. *J Am Coll Cardiol* 2005;**46**:1384–1388.
21. Pohost GM, Kim RJ, Kramer CM, Manning WJ. Task Force 12: training in advanced cardiovascular imaging (cardiovascular magnetic resonance [CMR]) endorsed by the Society for Cardiovascular Magnetic Resonance. *J Am Coll Cardiol* 2008;**51**:404–408.
22. van den Bosch AE, Robbers-Visser D, Krenning BJ, McGhie JS, Helbing WA, Meijboom FJ, Roos-Hesselink JW. Comparison of real-time three-dimensional echocardiography to magnetic resonance imaging for assessment of left ventricular mass. *Am J Cardiol* 2006;**97**:113–117.
23. Mannaerts HF, Van Der Heide JA, Kamp O, Papavassiliu T, Marcus JT, Beek A, Van Rossum AC, Twisk J, Visser CA. Quantification of left ventricular volumes and ejection fraction using freehand transthoracic three-dimensional echocardiography: comparison with magnetic resonance imaging. *J Am Soc Echocardiogr* 2003;**16**:101–109.
24. Grothues F, Smith GC, Moon JC, Bellenger NG, Collins P, Klein HU, Pennell DJ. Comparison of interstudy reproducibility of cardiovascular magnetic resonance with two-dimensional echocardiography in normal subjects and in patients with heart failure or left ventricular hypertrophy. *Am J Cardiol* 2002;**90**:29–34.
25. Bellenger NG, Marcus NJ, Rajappan K, Yacoub M, Banner NR, Pennell DJ. Comparison of techniques for the measurement of left ventricular function following cardiac transplantation. *J Cardiovasc Magn Reson* 2002;**4**:255–263.
26. Karamitsos T, Hudsmith L, Selvanayagam J, Neubauer S, Francis J. Operator induced variability in left ventricular measurements with cardiovascular magnetic resonance is improved after training. *J Cardiovasc Mag Reson* 2007;**9**:777–783.
27. Mooij CF, de Wit CJ, Graham DA, Powell AJ, Geva T. Reproducibility of MRI measurements of right ventricular size and function in patients with normal and dilated ventricles. *J Magn Reson Imaging* 2008;**28**:67–73.
28. Winter MM, Bernink FJ, Groenink M, Bouma BJ, van Dijk AP, Helbing WA, Tijssen JG, Mulder BJ. Evaluating the systemic right ventricle by CMR: the importance of consistent and reproducible delineation of the cavity. *J Cardiovasc Magn Reson* 2008;**10**:40.
29. Codella NC, Weinsaft JW, Cham MD, Janik M, Prince MR, Wang Y. Left ventricle: automated segmentation by using myocardial perfusion threshold reduction and intravoxel computation at MR imaging. *Radiology* 2008;**248**:1004–1012.
30. Plein S, Schwitger J, Suerder D, Greenwood JP, Boesiger P, Kozerke S. k-Space and time sensitivity encoding-accelerated myocardial perfusion MR imaging at 3.0 T: comparison with 1.5 T. *Radiology* 2008;**249**:493–500.
31. Muthurangu V, Taylor A, Andriantsimavona R, Hegde S, Miquel ME, Tulloh R, Baker E, Hill DL, Razavi RS. Novel method of quantifying pulmonary vascular resistance by use of simultaneous invasive pressure monitoring and phase-contrast magnetic resonance flow. *Circulation* 2004;**110**:826–834.
32. Muthurangu V, Razavi RS. The value of magnetic resonance guided cardiac catheterisation. *Heart* 2005;**91**:995–996.
33. Geva T, Marshall AC. Magnetic resonance imaging-guided catheter interventions in congenital heart disease. *Circulation* 2006;**113**:1093–1100.
34. Prakash A, Powell AJ, Krishnamurthy R, Geva T. Magnetic resonance imaging evaluation of myocardial perfusion and viability in congenital and acquired pediatric heart disease. *Am J Cardiol* 2004;**93**:657–661.
35. Levine GN, Gomes AS, Arai AE, Bluemke DA, Flamm SD, Kanal E, Manning WJ, Martin ET, Smith JM, Wilke N, Shellock FS, American Heart Association Committee on Diagnostic Interventional Cardiac Catheterization; American Heart Association Council on Clinical Cardiology; American Heart Association Council on Cardiovascular Radiology, Intervention. Safety of magnetic resonance imaging in patients with cardiovascular devices: an American Heart Association scientific statement from the Committee on Diagnostic and Interventional Cardiac Catheterization, Council on Clinical Cardiology, and the Council on Cardiovascular Radiology and Intervention: endorsed by the American College of Cardiology Foundation, the North American Society for Cardiac Imaging, and the Society for Cardiovascular Magnetic Resonance. *Circulation* 2007;**116**:2878–2891.
36. Shellock FG, Spinazzi A. MRI safety update 2008: part 2, screening patients for MRI. *Am J Roentgenol* 2008;**191**:1140–1149.
37. Penfield JG. Nephrogenic systemic fibrosis and the use of gadolinium-based contrast agents. *Pediatr Nephrol* 2008;**23**:2121–2129.
38. Canavese C, Mereu MC, Aime S, Lazzarich E, Fenoglio R, Quaglia M, Stratta P. Gadolinium-associated nephrogenic systemic fibrosis: the need for nephrologists' awareness. *J Nephrol* 2008;**21**:324–336.
39. Shellock FG, Spinazzi A. MRI safety update 2008: part 1, MRI contrast agents and nephrogenic systemic fibrosis. *AJR Am J Roentgenol* 2008;**191**:1129–1139.
40. Royal College of Radiologists advice on gadolinium-based contrast media and nephrogenic systemic fibrosis: [http://www.rcr.ac.uk/docs/radiology/pdf/BFCR0714\\_Gadolinium\\_NSF\\_guidanceNov07.pdf](http://www.rcr.ac.uk/docs/radiology/pdf/BFCR0714_Gadolinium_NSF_guidanceNov07.pdf).
41. Odegard KC, DiNardo JA, Tsai-Goodman B, Powell AJ, Geva T, Laussen PC. Anaesthesia considerations for cardiac MRI in infants and small children. *Paediatr Anaesth* 2004;**14**:471–476.
42. Kilner PJ, Gatehouse PD, Firmin DN. Flow measurement by magnetic resonance: a unique asset worth optimising. *J Cardiovasc Magn Reson* 2007;**9**:723–728.
43. Davos D, Kilner PJ. Calculations of cardiovascular shunts and regurgitation using magnetic resonance ventricular volume and aortic and pulmonary flow measurements. *European Radiology* 2009; Epub ahead of print.
44. Chernobelsky A, Shubayev O, Comeau CR, Wolff SD. Baseline correction of phase contrast images improves quantification of blood flow in the great vessels. *J Cardiovasc Magn Reson* 2007;**9**:681–685.
45. Lankhaar JW, Hofman MB, Marcus JT, Zwanenburg JJ, Faes TJ, Vonk-Noordegraaf A. Correction of phase offset errors in main pulmonary artery flow quantification. *J Magn Reson Imaging* 2005;**22**:73–79.
46. Wagner A, Mahrholdt H, Kim RJ, Judd RM. Use of cardiac magnetic resonance to assess viability. *Curr Cardiol Rep* 2005;**7**:59–64.
47. Gerber BL, Raman SV, Nayak K, Epstein FH, Ferreira P, Axel L, Kraitchman DL. Myocardial first-pass perfusion cardiovascular magnetic resonance: history, theory, and current state of the art. *J Cardiovasc Magn Reson* 2008;**10**:18.
48. Bonow RO, Carabello BA, Kanu C, de Leon AC Jr, Faxon DP, Freed MD, Gaasch WH, Lytle BW, Nishimura RA, O'Gara PT, O'Rourke RA, Otto CM, Shah PM, Shanewise JS, Smith SC Jr, Jacobs AK, Adams CD, Anderson JL, Antman EM, Faxon DP, Fuster V, Halperin JL, Hiratzka LF, Hunt SA, Lytle BV, Nishimura R, Page RL, Riegel B. ACC/AHA Guidelines for the Management of Patients with Valvular Heart disease. *Circulation* 2006;**114**:e84–e231.
49. Gabriel RS, Kerr AJ, Raffel OC, Stewart RA, Cowan BR, Occleshaw CJ. Mapping of mitral regurgitant defects by cardiovascular magnetic resonance in moderate or severe mitral regurgitation secondary to mitral valve prolapse. *J Cardiovasc Magn Reson* 2008;**10**:16.
50. Chan KM, Wage R, Symmonds K, Rahman-Haley S, Mohiaddin RH, Firmin DN, Pepper JR, Pennell DJ, Kilner PJ. Towards comprehensive assessment of mitral regurgitation using cardiovascular magnetic resonance. *J Cardiovasc Magn Reson* 2008;**10**:61.
51. Carr-White GS, Kilner PJ, Hon JK, Rutledge T, Edwards S, Burman ED, Pennell DJ, Yacoub MH. Incidence, location, pathology, and significance of pulmonary homograft stenosis after the Ross operation. *Circulation* 2001;**104**:116–120.
52. Crowe M, Rocha CA, Wu E, Carr JC. Complications following the Ross procedure: cardiac MRI findings. *J Thorac Imaging* 2006;**21**:213–218.
53. Klieverik LM, Takkenberg JJ, Bekkers JA, Roos-Hesselink JW, Witsenburg M, Bogers AJ. The Ross operation: a Trojan horse? *Eur Heart J* 2007;**28**:1993–2000.
54. Therrien J, Thorne SA, Wright A, Kilner PJ, Somerville J. Repaired coarctation: a 'cost-effective' approach to identify complications in adults. *J Am Coll Cardiol* 2000;**35**:997–1002.
55. Chessa M, Carrozza M, Butera G, Piazza L, Negura DG, Bussadori C, Bossone E, Giamberti A, Carminati M. Results and mid-long-term follow-up of stent implantation for native and recurrent coarctation of the aorta. *Eur Heart J* 2005;**26**:2728–2732.
56. Hassan W, Awad M, Fawzy ME, Omrani AA, Malik S, Akhras N, Shoukri M. Long-term effects of balloon angioplasty on left ventricular hypertrophy in adolescent and adult patients with native coarctation of the aorta. Up to 18 years follow-up results. *Catheter Cardiovasc Interv* 2007;**70**:881–886.
57. Steffens JC, Bourne MW, Sakuma H, O'Sullivan M, Higgins CB. Quantification of collateral blood flow in coarctation of the aorta by velocity encoded cine magnetic resonance imaging. *Circulation* 1994;**90**:937–943.
58. Nielsen JC, Powell AJ, Gauvreau K, Marcus EN, Prakash A, Geva T. Magnetic resonance imaging predictors of coarctation severity. *Circulation* 2005;**111**:622–628.
59. Connolly HM, Huston J III, Brown RD Jr, Warnes CA, Ammass NM, Tajik AJ. Intracranial aneurysms in patients with coarctation of the aorta: a prospective magnetic resonance angiographic study of 100 patients. *Mayo Clin Proc* 2003;**78**:1491–1499.

60. Fattori R, Bacchi Reggiani L, Pepe G, Napoli G, Bna C, Celletti F, Lovato L, Gavelli G. Magnetic resonance imaging evaluation of aortic elastic properties as early expression of Marfan syndrome. *J Cardiovasc Magn Reson* 2000;**2**:251–256.
61. Kaemmerer H, Oechslin E, Seidel H, Neuhaan T, Neuhaan IM, Mayer HM, Hess J. Marfan syndrome: what internists and pediatric or adult cardiologists need to know. *Expert Rev Cardiovasc Ther* 2005;**3**:891–909.
62. Baumgartner D, Baumgartner C, Matyas G, Steinmann B, Löffler-Ragg J, Schermer E, Schweigmann U, Baldissera I, Frischhut B, Hess J, Hammerer I. Diagnostic power of aortic elastic properties in young patients with Marfan syndrome. *J Thorac Cardiovasc Surg* 2005;**129**:730–739.
63. Knirsch W, Kurtz C, Häffner N, Binz G, Heim P, Winkler P, Baumgartner D, Freund-Unsinn K, Stern H, Kaemmerer H, Molinari L, Kececioglu D, Uhlemann F. Dural ectasia in children with Marfan syndrome: a prospective, multi-center, patient-control study. *Am J Med Genet A* 2006;**140**:775–781.
64. Apitz C, Webb GD, Redington AN. Tetralogy of Fallot. *Lancet* 2009; [Epub ahead of print].
65. Davlouros PA, Kilner PJ, Hornung TS, Li W, Francis JM, Moon JC, Smith GC, Tat T, Pennell DJ, Gatzoulis MA. Right ventricular function in adults with repaired tetralogy of Fallot assessed with cardiovascular magnetic resonance imaging: detrimental role of right ventricular outflow aneurysms or akinesia and adverse right-to-left ventricular interaction. *J Am Coll Cardiol* 2002;**40**:2044–2052.
66. Dorfman AL, Geva T. Magnetic resonance imaging evaluation of congenital heart disease: conotruncal anomalies. *J Cardiovasc Magn Reson* 2006;**8**:645–659.
67. Samyn MM, Powell AJ, Garg R, Sena L, Geva T. Range of ventricular dimensions and function by steady-state free precession cine MRI in repaired tetralogy of Fallot: right ventricular outflow tract patch vs. conduit repair. *J Magn Reson Imaging* 2007;**26**:934–940.
68. Wald RM, Redington AN, Pereira A, Provost YL, Paul NS, Oechslin EN, Silversides CK. Refining the assessment of pulmonary regurgitation in adults after tetralogy of Fallot repair: should we be measuring regurgitant fraction or regurgitant volume? *Eur Heart J* 2009;**30**:356–361.
69. Henkens IR, van Straten A, Schalij MJ, Hazekamp MG, de Roos A, van der Wall EE, Vliegen HW. Predicting outcome of pulmonary valve replacement in adult tetralogy of Fallot patients. *Ann Thorac Surg* 2007;**83**:907–911.
70. Geva T. Indications and timing of pulmonary valve replacement after tetralogy of Fallot repair. *Semin Thorac Cardiovasc Surg Pediatr Card Surg Annu* 2006;**9**:11–22.
71. Frigiola A, Tsang V, Bull C, Coats L, Khambadkone S, Derrick G, Mist B, Walker F, van Doorn C, Bonhoeffer P, Taylor AM. Biventricular response after pulmonary valve replacement for right ventricular outflow tract dysfunction: is age a predictor of outcome? *Circulation* 2008;**118**:S182–S190.
72. Harrild DM, Berul CI, Cecchin F, Geva T, Gauvreau K, Pigula F, Walsh EP. Pulmonary valve replacement in tetralogy of Fallot: impact on survival and ventricular tachycardia. *Circulation* 2009;**119**:445–451.
73. Lurz P, Coats L, Khambadkone S, Nordmeyer J, Boudjemline Y, Schievano S, Muthurangu V, Lee TY, Parenzan G, Derrick G, Cullen S, Walker F, Tsang V, Deanfield J, Taylor AM, Bonhoeffer P. Percutaneous pulmonary valve implantation: impact of evolving technology and learning curve on clinical outcome. *Circulation* 2008;**117**:1964–1972.
74. Frigiola A, Tsang V, Nordmeyer J, Lurz P, van Doorn C, Taylor AM, Bonhoeffer P, de Leval M. Current approaches to pulmonary regurgitation. *Eur J Cardiothorac Surg* 2008;**34**:576–580.
75. Therrien J, Provost Y, Merchant N, Williams W, Colman J, Webb G. Optimal timing for pulmonary valve replacement in adults after tetralogy of Fallot repair. *Am J Cardiol* 2005;**95**:779–782.
76. Oosterhof T, van Straten A, Vliegen HW, Meijboom FJ, van Dijk AP, Spijkerboer AM, Bouma BJ, Zwinderman AH, Hazekamp MG, de Roos A, Mulder BJ. Preoperative thresholds for pulmonary valve replacement in patients with corrected tetralogy of Fallot using cardiovascular magnetic resonance. *Circulation* 2007;**116**:545–551.
77. Geva T, Sahn DJ, Powell AJ. Magnetic resonance imaging of congenital heart disease in adults. *Prog Pediatr Cardiol* 2003;**17**:21–39.
78. Kilner PJ, Balossino R, Dubini G, Babu-Narayan SV, Taylor AM, Pennati G, Migliavacca F. Pulmonary regurgitation: the effects of varying pulmonary artery compliance, and of increased resistance proximal or distal to the compliance. *Int J Cardiol* 2009;**133**:157–166.
79. Chaturvedi RR, Redington AN. Pulmonary regurgitation in congenital heart disease. *Heart* 2007;**93**:880–889.
80. Geva T, Sandweiss BM, Gauvreau K, Lock JE, Powell AJ. Factors associated with impaired clinical status in long-term survivors of tetralogy of Fallot repair evaluated by magnetic resonance imaging. *J Am Coll Cardiol* 2004;**43**:1068–1074.
81. Kilner PJ, Sievers B, Meyer GP, Ho SY. Double-chambered right ventricle or subinfundibular stenosis assessed by cardiovascular magnetic resonance. *J Cardiovasc Magn Reson* 2002;**4**:373–379.
82. Geva T, Greil GF, Marshall AC, Landzberg M, Powell AJ. Gadolinium-enhanced 3-dimensional magnetic resonance angiography of pulmonary blood supply in patients with complex pulmonary stenosis or atresia: comparison with x-ray angiography. *Circulation* 2002;**106**:473–478.
83. Nagendran J, Michelakis E. MRI: one-stop shop for the comprehensive assessment of pulmonary arterial hypertension? *Chest* 2007;**132**:2–5.
84. Wald RM, Powell AJ. Simple congenital heart lesions. *J Cardiovasc Magn Reson* 2006;**8**:619–631.
85. Piaw CS, Kiam OT, Rapae A, Khoon LC, Bang LH, Ling CW, Samion H, Hian SK. Use of non-invasive phase contrast magnetic resonance imaging for estimation of atrial septal defect size and morphology: a comparison with transesophageal echo. *Cardiovasc Intervent Radiol* 2006;**29**:230–234.
86. Valente AM, Sena L, Powell AJ, Del Nido PJ, Geva T. Cardiac magnetic resonance imaging evaluation of sinus venosus defects: comparison to surgical findings. *Pediatr Cardiol* 2007;**28**:51–56.
87. Salehian O, Schwerzmann M, Merchant N, Webb GD, Siu SC, Therrien J. Assessment of systemic right ventricular function in patients with transposition of the great arteries using the myocardial performance index: comparison with cardiac magnetic resonance imaging. *Circulation* 2004;**110**:3229–3233.
88. Taylor AM, Dymarkowski S, Hamaekers P, Razavi R, Gewillig M, Mertens L, Bogaert J. MR coronary angiography and late-enhancement myocardial MR in children who underwent arterial switch surgery for transposition of great arteries. *Radiology* 2005;**234**:542–547.
89. Rutledge JM, Nihill MR, Fraser CD, Smith OE, McMahon CJ, Bezold LI. Outcome of 121 patients with congenitally corrected transposition of the great arteries. *Pediatr Cardiol* 2002;**23**:137–145.
90. Garg R, Powell AJ, Sena L, Marshall AC, Geva T. Effects of metallic implants on magnetic resonance imaging evaluation of Fontan palliation. *Am J Cardiol* 2005;**95**:688–691.
91. Grosse-Wortmann L, Al-Otay A, Yoo SJ. Aortopulmonary collaterals after bidirectional cavopulmonary connection or Fontan completion: quantification with MRI. *Circ Cardiovasc Imaging* 2009;**2**:219–225.
92. Anderson RH, Becker AE, Freedom RM, Macartney FJ, Quero-Jimenez M, Shinebourne EA, Wilkinson JL, Tynan M. Sequential segmental analysis of congenital heart disease. *Pediatr Cardiol* 1984;**5**:281–287.
93. Van Praagh R, Santini F, Geva T. Segmental situs in congenital heart disease: a fundamental concept. *G Ital Cardiol* 1990;**20**:246–253.
94. Taylor AM, Thorne SA, Rubens MB, Jhooti P, Keegan J, Gatehouse PD, Wiesmann F, Grothues F, Somerville J, Pennell DJ. Coronary artery imaging in grown-up congenital heart disease: complementary role of MR and X-ray coronary angiography. *Circulation* 2000;**101**:1670–1678.
95. Bunce NH, Lorenz CH, Keegan J, Lesser J, Reyes EM, Firmin DN, Pennell DJ. Coronary artery anomalies: assessment with free-breathing three-dimensional coronary MR angiography. *Radiology* 2003;**227**:201–208.
96. Valsangiacomo Buechel ER, Balmer C, Bauersfeld U, Kellenberger CJ, Schwittler J. Feasibility of perfusion cardiovascular magnetic resonance in paediatric patients. *J Cardiovasc Reson Med* 2009;**11**:51–59.
97. Schwittler J, Wacker CM, van Rossum AC, Lombardi M, Al-Saadi N, Ahlstrom H, Dill T, Larsson HBW, Flamm SD, Marquardt M, Johansson L. MR-IMPACT: comparison of perfusion-cardiac magnetic resonance with single-photon emission computed tomography for the detection of coronary artery disease in a multicentre, multivendor, randomized trial. *Eur Heart J* 2008;**29**:480–489.