



Effect of Penetrating Keratoplasty and Keratoprosthesis Implantation on the Posterior Segment of the Eye

Citation

Published version

<https://doi.org/10.1167/iovs.15-17557>

Link

<http://nrs.harvard.edu/urn-3:HUL.InstRepos:29408293>

Terms of use

This article was downloaded from Harvard University's DASH repository, and is made available under the terms and conditions applicable to Other Posted Material (LAA), as set forth at

<https://harvardwiki.atlassian.net/wiki/external/NGY5NDE4ZjgzNTc5NDQzMGIzZWZhMGFIOWI2M2EwYTg>

Accessibility

<https://accessibility.huit.harvard.edu/digital-accessibility-policy>

Share Your Story

The Harvard community has made this article openly available.
Please share how this access benefits you. [Submit a story](#)

Effect of Penetrating Keratoplasty and Keratoprosthesis Implantation on the Posterior Segment of the Eye

Alja Črnej, Masahiro Omoto, Thomas H. Dohlman, Miguel Gonzalez-Andrades, Eleftherios I. Paschalis, Andrea Cruzat, T. H. Khanh Vu, Marianne Doorenbos, Dong Feng Chen, Claes H. Dohlman, and Reza Dana

Schepens Eye Research Institute, Massachusetts Eye and Ear Infirmary, Department of Ophthalmology, Harvard Medical School, Boston, Massachusetts, United States

Correspondence: Reza Dana, Schepens Eye Research Institute, 20 Staniford Street, Boston, MA 02114, USA; reza_dana@meei.harvard.edu.

Submitted: June 24, 2015
Accepted: February 26, 2016

Citation: Črnej A, Omoto M, Dohlman TH, et al. Effect of penetrating keratoplasty and keratoprosthesis implantation on the posterior segment of the eye. *Invest Ophthalmol Vis Sci*. 2016;57:1643-1648. DOI:10.1167/iov.15-17557

PURPOSE. To compare the effects of post-penetrating keratoplasty (PK) and post-keratoprosthesis (KPro) surgery-related inflammation on the posterior segment of the eye and to assess inhibition of tumor necrosis factor alpha (TNF α) and interleukin-1 beta (IL-1 β) on these effects.

METHODS. BALB/C (syngeneic) or C57BL/6 (allogeneic) corneas were transplanted onto BALB/C host beds as part of PK or miniature KPro (m-KPro) implantation. Intraocular pressure (IOP) was measured via an intracameral pressure sensor; tissues were harvested and analyzed 8 weeks after surgery. Expression of TNF α and IL-1 β in the retina was analyzed using real-time quantitative (q)PCR. Optic nerve degeneration (axon count, circularity, and area) was assessed quantitatively using ImageJ software. After m-KPro implantation, mice were treated with saline, anti-TNF α , or anti-IL-1 β antibody, and axonal loss was assessed after 10 weeks.

RESULTS. Mean IOP was within normal limits in the operated and fellow eyes in all groups. The mRNA expression of TNF α and IL-1 β was highest in m-KPro groups with either syngeneic or an allogeneic carrier. We observed optic nerve degeneration in both allogeneic PK and m-KPro implanted eyes with an allogeneic carrier. However, TNF α blockade significantly reduced axonal loss by 35%.

CONCLUSIONS. Allogeneic PK and m-KPro implants with an allogeneic carrier lead to chronic inflammation in the posterior segment of the eye, resulting in optic nerve degeneration. In addition, blockade of TNF α prevents axonal degeneration in this preclinical model of allogeneic m-KPro (alloKPro) implantation.

Keywords: Boston keratoprosthesis, keratoplasty, chronic inflammation, optic neuropathy

Penetrating keratoplasty (PK) and Boston keratoprosthesis (B-KPro) implantation are sight-saving procedures in many patients with corneal blindness. The vast majority of corneal donor tissues for PK and corneas used as a B-KPro carrier are allogeneic and are derived from a genetically nonidentical donor. Recent data on PK have demonstrated guarded long-term survival rates for several disease categories, including Fuchs endothelial dystrophy and pseudophakic bullous keratopathy, as well as in regrafts.^{1,2}

Allograft rejection, late endothelial failure, postgraft infection, and glaucoma are the most common causes for graft failure after PK.² Boston keratoprosthesis, the most widely used artificial cornea, consists of a polymethylmethacrylate (PMMA) front plate and a PMMA or titanium back plate supported by a donor corneal transplant, and can be used when standard PK is expected to yield a poor prognosis. Keratoprosthesis with a PMMA back plate is the most commonly implanted KPro design outside the Massachusetts Eye and Ear Infirmary (MEEI); however, the newest design with titanium back plate has been used at MEEI since 2005.³ The titanium back plate is thinner, causing less crowdedness of the anterior chamber of the eye, and titanium is known to cause less inflammation in the tissue than PMMA.^{3,4} More than 50% of all patients receiving B-KPro retain good vision after 7 years, but these patients can also

experience long-term complications such as retroprosthesis membrane, glaucoma, sterile corneal necrosis, optic neuropathy, retinal detachment, chronic macular edema, and choroidal detachment.⁵⁻⁸

Using a miniature-KPro model (m-KPro),⁹ our group recently reported increased chronic inflammation in the cornea after allogeneic PK and m-KPro implants with an allogeneic carrier.¹⁰ These changes may lead to anterior segment complications such as allograft rejection or late endothelial failure in PK or retroprosthesis membrane and sterile corneal necrosis in KPro. It is known that cytokines play a critical role in promoting inflammation in corneal transplantation¹¹; however, the effect of inflammation in the anterior eye on posterior changes and long-term complications in B-KPro patients remains largely unknown. In this study, we hypothesize that allogeneic PK and m-KPro implantation with an allogeneic carrier not only cause anterior segment inflammation but also chronic changes in the posterior segment of the eye (not tissue-restricted immune response).

Here, we assessed inflammation and associated damage to the posterior part of murine eyes after performing PK and m-KPro implantation using allogeneic or syngeneic corneal tissue. We analyzed the expression of TNF α and IL-1 β in the retina after PK and m-KPro implantation, and evaluated whether

blockade of TNF α or IL-1 β can reduce optic nerve degeneration. For the first time, we shed light on potential mechanisms of posterior segment complications after PK and KPro implantation.

METHODS

Animals

A total of 125 male mice (8–10 weeks old; Jackson Laboratory, Bar Harbor, ME, USA; 82 BALB/C as recipients; 10 BALB/C and 28 C57BL/6 as donors; and 11 as naïve) were used in this study. Mice were housed in a climate-controlled animal facility at the Schepens Eye Research Institute, Massachusetts Eye and Ear, Harvard Medical School (Boston, MA, USA), and kept under cyclic light conditions (12 hours on/off). All animal experiments were approved by the Institutional Animal Care and Use Committee and were conducted in accordance with the ARVO Statement for the Use of Animals in Ophthalmic and Vision Research.

For the first part of the study, mice were divided into five groups (10 mice/group): (1) naïve, (2) syngeneic penetrating keratoplasty (synPK) (BALB/C donor cornea transplanted to BALB/C recipient), (3) allogeneic penetrating keratoplasty (alloPK) (C57BL/6 donor cornea transplanted to BALB/C recipient), (4) syngeneic m-KPro implantation (synKPro) (BALB/C carrier corneal graft with assembled m-KPro transplanted to BALB/C recipient), and (5) allogeneic m-KPro implantation (alloKPro) (C57BL/6 carrier corneal graft with assembled m-KPro transplanted to BALB/C recipient).

Second, to analyze the effect of cytokine inhibition, alloKPro implantation was performed. After implantation, mice were divided into four groups and treated with saline, anti-TNF α or anti-IL-1 β antibody or kept untreated. Intraperitoneal saline, anti-TNF α antibody (10 mg/kg), or anti-IL-1 β antibody (10 mg/kg) was administered once a week starting at day 0 through week 10. The mice were analyzed 10 weeks after the procedure.

Penetrating Keratoplasty

Surgeries were performed under a surgical microscope (Zeiss, Jena, Germany). Procedures were performed by two investigators (MO and AC). After euthanasia of the donor mice, corneas were marked with a 2-mm-diameter biopsy punch (Miltex, Plainsboro, NJ, USA). To maintain a deep anterior chamber, viscoelastic (Viscoat; Alcon, Irvine, CA, USA) was injected through the groove with a 30-gauge cannula (Rumex, Clearwater, FL, USA). Corneas were excised with Vannas scissors (Storz Instruments Company, San Dimas, CA, USA) and placed in phosphate-buffered saline (PBS) until the host corneal bed had been prepared.

Recipient mice were anesthetized by intraperitoneal injection of ketamine (120 mg/kg) and xylazine (20 mg/kg). A drop of 1% tropicamide (Bausch & Lomb, New York, NY, USA) and a drop of 0.5% phenylephrine hydrochloride (Altaire Pharmaceuticals, New York, NY, USA) were applied to the right eye to dilate the pupil 15 minutes before the procedure. Corneas were marked with a 2-mm-diameter biopsy punch (Harris UniCore punch; Ted Pella, Inc., Redding, CA, USA). Before opening the eye, viscoelastic (Viscoat, Alcon) was injected via a 30-gauge cannula (Rumex, Clearwater, FL, USA). The cornea was excised with Vannas scissors (Storz Instruments Company). Throughout the procedure, viscoelastic was used to maintain the depth of the anterior chamber. The host lens was removed as previously described.¹² Briefly, a curvilinear continuous capsulorrhexis was performed with

jeweler forceps (Katena, Denville, NJ, USA), and a hydrodissection was performed with a 30-gauge cannula and PBS to deliver the lens en bloc. Visible cortex remnants were carefully aspirated through the cannula. The donor cornea was then placed in the recipient bed and secured with eight interrupted 11-0 nylon sutures (SharpPoint; Angiotech Pharmaceuticals, Vancouver, Canada) in standard PK fashion.

Miniature KPro Implantation

A miniature keratoprosthesis (m-KPro) (JG Machine, Wilmington, MA, USA), minimized, but otherwise identical to the B-KPro device used in humans, was used. It consists of a PMMA front plate with central stem and a titanium (Ti) back plate with eight peripheral holes. The diameters of the front and back plate were 1.0 and 1.3 mm, respectively. The design description and the exact dimensions of the m-KPro are described elsewhere.⁹ The surgical procedure was performed similarly to B-KPro implantation in humans and has been described previously.⁹

Briefly, to prepare for the assembly of the m-KPro device, excised donor corneas were trephined centrally with a 0.5-mm-diameter punch (Harris UniCore punch, Ted Pella, Inc.) and then slid over the stem of the PMMA front plate. The titanium back plate was positioned and locked on the stem such that the donor cornea became securely sandwiched between the front and back plates. The donor-device complex was then placed in PBS until the host corneal bed had been prepared as described above. After preparation, the donor cornea-m-KPro complex was placed in the recipient bed and secured with eight interrupted 11-0 nylon sutures (SharpPoint, Angiotech Pharmaceuticals) in standard PK fashion.

Postoperative Treatment

In the first part of the study, postoperative treatment was identical after PK and m-KPro implantation. One drop of 1% corticosteroid (Pred Forte; Allergan, Irvine, CA, USA) and antibiotic ointment (AK-POLY-BAC; Akorn, Lake Forest, IL, USA) were applied immediately after the procedure, and a tarsorrhaphy was performed using 8-0 nylon sutures (SharpPoint, Angiotech Pharmaceuticals). Corticosteroid was administered once a day for 2 weeks and then every other day for 2 weeks. The tarsorrhaphy was removed 48 hours after the surgery, and corneal sutures were removed 1 week following surgery. Per standard institutional animal care and use protocols, 0.1 mg/kg buprenorphine (Reckitt Benckiser Healthcare Ltd., Hull, England) was applied subcutaneously after the procedure and every 12 hours for 48 hours postoperatively. The mice were euthanized 8 weeks after the procedure for further analysis. Eight weeks in mice corresponds to around 6 years in humans.¹³

In the second part of the study, corticosteroids were not used and mice were euthanized 10 weeks after the procedure; the rest of the postoperative treatment was identical to that for the first part.

Intraocular Pressure (IOP) Measurement

To evaluate IOP after syngeneic or allogeneic PK and m-KPro implantation, direct manometry was used. Intracameral IOP measurements were performed in anesthetized mice using a custom-designed 32-gauge needle electromechanical pressure sensor. Measurements were performed by inserting the needle in the anterior chamber of the eye through a clear cornea puncture. Intraocular pressure readings were stored in a personal computer for further analysis.

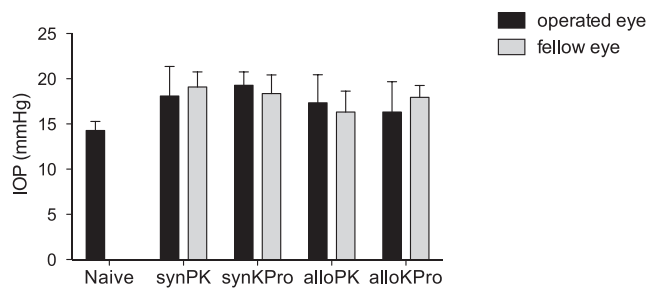


FIGURE 1. Intraocular pressure measurements in mice. Intraocular pressure was measured in the operated and fellow eyes using manometry 8 weeks post surgery. N, naïve; synPK, syngeneic PK; synKPro, syngeneic m-KPro; alloPK, allogeneic PK; and alloKPro, allogeneic m-KPro. $n = 5/\text{group}$.

Reverse Transcription and Real-Time PCR

Retinas were harvested at 8 weeks post surgery. RNA was isolated with the RNeasy Micro Kit (Qiagen, Valencia, CA, USA) and reverse transcribed using Superscript III Kit (Invitrogen, Grand Island, NY, USA). Real-time quantitative (q)PCR was performed using Taqman Universal PCR Mastermix and preformulated primers for murine glyceraldehyde 3-phosphate dehydrogenase (GAPDH), tumor necrosis factor alpha (TNF α), and interleukin-1 beta (IL-1 β) (Applied Biosystems, Foster City, CA, USA). The results were normalized to the expression level in naïve mice and were analyzed by the comparative threshold cycle method, using GAPDH as an internal control. Real-time PCR was repeated twice for each cytokine. Retinas of three mice were pooled and duplicates for each group were analyzed.

Optic Nerve Axon Counts, Circularity, and Area

Optic nerves were analyzed as described before.¹⁴ Briefly, optic nerves were fixed with half-strength Karnovsky fixative and cut into 1- μm cross sections. Pictures of five cross sections were taken with $\times 20$ magnification under a light microscope to determine optic nerve perimeter. Five pictures of each cross section were taken with $\times 100$ magnification to quantify axon numbers per mm^2 and axon size. The pictures were systematically analyzed using ImageJ (National Institutes of Health, Bethesda, MD, USA). Circularity was defined as $4\pi \times [\text{Area}]/[\text{Perimeter}]^2$ with a value of 1.0 indicating a perfect circle. As the value approaches 0.0, it indicates an increasingly noncircular shape.

Statistics

Student's *t*-test was used to analyze the data. $P \leq 0.05$ was considered statistically significant. Results are presented as the mean \pm standard error of the mean (SEM).

RESULTS

Intraocular Pressure After Syngeneic or Allogeneic PK and m-KPro Implantation

We measured IOP in the operated and fellow eyes of mice after syngeneic or allogeneic PK and m-KPro implantation and in the eyes of naïve mice. All groups showed a similar mean IOP within normal limits (14–19 mm Hg). There was no statistically significant difference between any of the experimental groups (Fig. 1).

Inflammatory Cytokine Expression in the Retina After Syngeneic or Allogeneic PK and m-KPro

To evaluate inflammation in the retina following PK and m-KPro implantation, we quantified mRNA expression of the proinflammatory cytokines TNF α and IL-1 β at week 8 after surgery. We detected an increase in TNF α expression in all operated groups compared to naïve mice; however, a significant increase was seen only in the synKPro ($P < 0.01$) and alloKPro ($P < 0.05$) groups (Fig. 2A). The expression of IL-1 β was higher in syngeneic and allogeneic m-KPro groups compared to syngeneic and allogeneic PK groups, respectively (Fig. 2B). The alloKPro group showed significantly higher expression of IL-1 β compared to naïve mice ($P < 0.05$; Fig. 2B).

Optic Nerve Axon Count, Size, and Circularity After Syngeneic or Allogeneic PK and m-KPro Implantation

To determine the effect of PK and m-KPro implantation on optic nerve changes, we analyzed optic nerve images from week 8 after surgery with ImageJ (Figs. 3A, 3B). The number of axons remained similar in the synPK and synKPro groups compared to the fellow eye. However, we observed axon loss of $13 \pm 8\%$ and $19 \pm 8\%$ in the alloPK and alloKPro groups, respectively (Fig. 3C). We additionally analyzed axon size and circularity. Average axon size increased in all operated groups compared to naïve mice (Fig. 3D). Axon circularity was reduced in all four groups compared to naïve mice and significantly reduced in the alloKPro group (Fig. 3E).

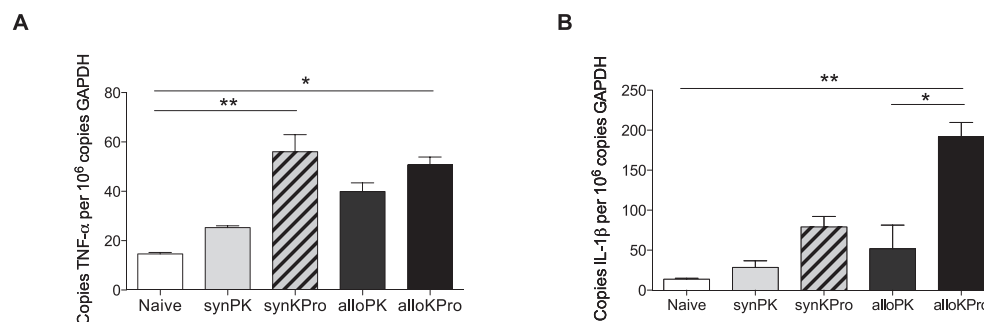


FIGURE 2. Quantification of proinflammatory cytokines in the retina. Transplant recipients from all groups (syngeneic [syn] and allogeneic [allo] penetrating keratoplasty [PK] and miniature-Boston keratoprosthesis [m-KPro]) were euthanized at 8 weeks post surgery and retinas were collected and analyzed for the expression of (A) TNF α and (B) IL-1 β by real-time qPCR. $n = 6/\text{group}$; * $P = 0.05$; ** $P < 0.05$. Data from one representative experiment of two is shown. N, naïve; synPK, syngeneic PK; synKPro, syngeneic m-KPro; alloPK, allogeneic PK; and alloKPro, allogeneic m-KPro.

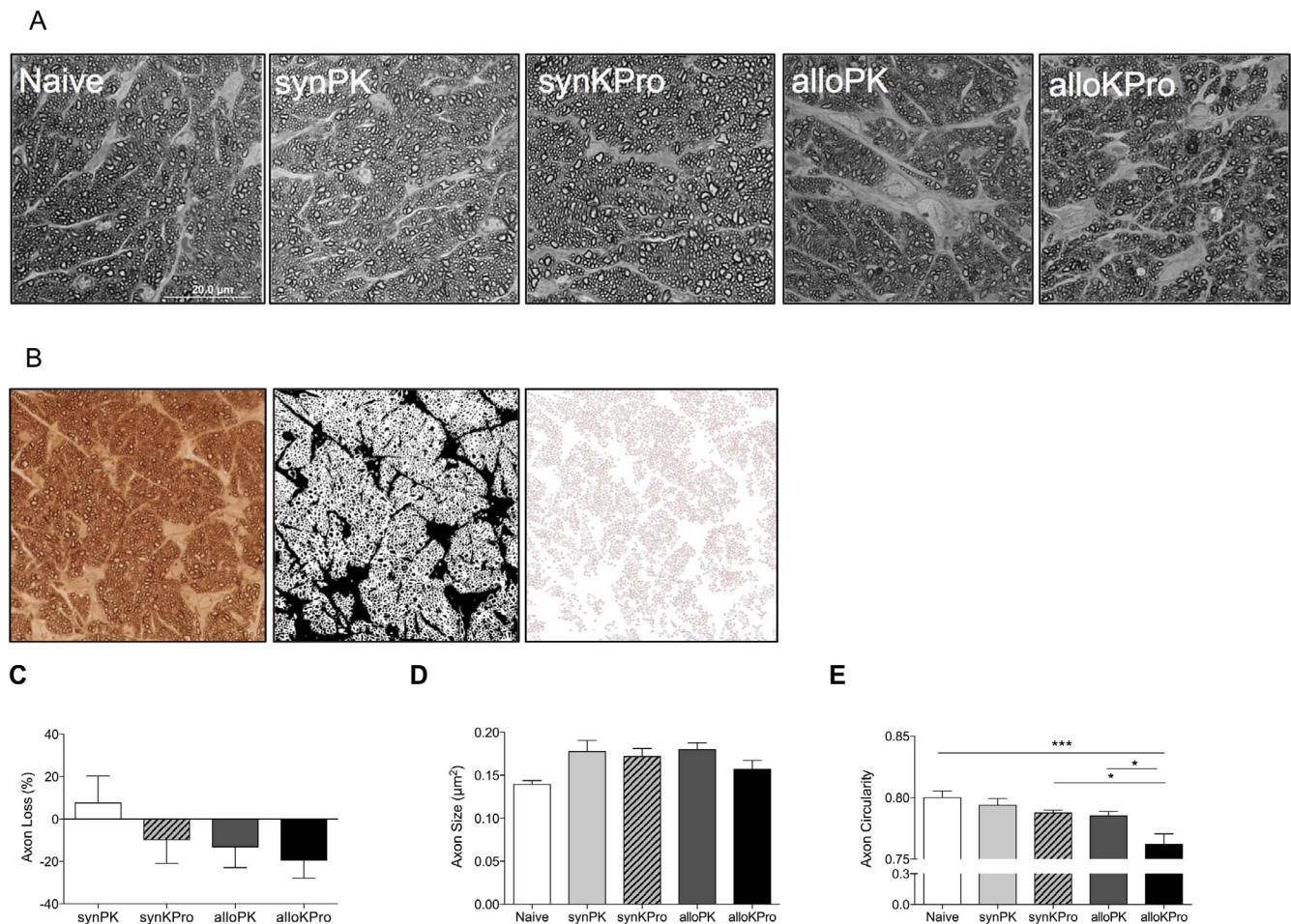


FIGURE 3. Quantification of optic nerve axon loss and axon circularity and size in mice. **(A)** Representative electron microscopy images taken from p-phenylenediamine-stained optic nerve sections of naïve (N), syngeneic PK (synPK), syngeneic m-KPro (synKPro), allogeneic PK (alloPK), and allogeneic m-KPro (alloKPro) mice. Scale bar: 20 µm. **(B)** Representative images showing the analysis with ImageJ. Quantification (as percentage) of axon loss compared to the fellow eye **(C)**, axon average size **(D)**, and axon circularity **(E)** at 8 weeks postoperatively is shown. A value of 1.0 indicates a perfect circle; as the value approaches 0.0, it indicates an increasingly noncircular shape. $n = 6/\text{group}$; $***P < 0.01$.

TNF α Blockade Protects the Optic Nerve After Allogeneic m-KPro

To determine the protective effect of TNF α and IL-1 β blockade on optic nerve degeneration, anti-TNF α or anti-IL-1 β antibody was administered after alloKPro implantation. We quantified optic nerve axon numbers 10 weeks after the surgery. Control

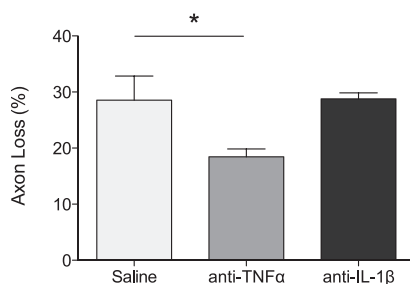


FIGURE 4. Quantification of optic nerve axon loss in saline-, anti-TNF α -, and anti-IL-1 β -treated alloKPro implanted mice. After allogeneic m-KPro implantation, mice were treated with saline, anti-TNF α (10 mg/kg), or anti-IL-1 β (10 mg/kg) antibody, and axon loss (as percentage compared to naïve mice) was assessed after 10 weeks using Karnovsky fixative and ImageJ. $n = 6/\text{group}$; $P = 0.03$.

mice that had m-KPro implantation (treated only with saline) had a reduction of $29 \pm 4\%$ in axon numbers compared to unoperated eyes. Similarly, m-KPro mice treated with anti-IL-1 β antibody had an associated axon loss of $29 \pm 1\%$ compared to unoperated mice, indistinguishable from the saline control group (Fig. 4; $P = 0.96$). In contrast, m-KPro mice that were treated with anti-TNF α antibody experienced axon loss of only $19 \pm 1\%$, a 35% reduction in axon loss compared to the saline-treated m-KPro implanted mice ($P = 0.03$).

DISCUSSION

The etiologies of chronic complications after PK and B-KPro surgery such as late endothelial failure, optic neuropathy, epiretinal membrane, macular edema, and retinal detachment remain largely unknown. And, for undetermined reasons, unusually rapid progression of glaucoma can be observed in PK¹⁵ as well as in KPro patients.^{16,17} It is known that anterior segment injuries and procedures like corneal burn or lens removal can induce posterior segment inflammation and damage.^{18,19} This is most likely caused by posterior diffusion of inflammatory cytokines secreted in the injured anterior segment.²⁰ We have recently shown increased TNF α and IL-1 β expression in the cornea after allogeneic PK and m-KPro implantation with allogeneic carrier.¹⁰ Increased TNF α pro-

duction has been also associated with high IOP and with optic nerve degeneration in murine models of glaucoma.²¹ In our study, mean IOP was within normal limits, although some eyes had high IOP, and peak values of IOP might not have been detected by a one-time measurement.

With this in mind, we analyzed the extent of retinal inflammation and optic nerve damage following PK and m-KPro surgery in order to elucidate a mechanism by which postoperative complications arise after such procedures. We observed increased retinal inflammation by measuring proinflammatory cytokine expression. We detected increased mRNA TNF α expression in the retina after alloPK as well as after synKPro and alloKPro compared to naïve and synPK. The mRNA expression of IL-1 β was higher after synKPro and alloKPro compared with the synPK and alloPK groups, respectively, a pattern that is consistent with the expression of inflammatory cytokines seen in our previous study.¹⁰ By comparing retinal inflammation after syngeneic and allogeneic PK and m-KPro implantation, we found that both the allogeneic carrier graft and the m-KPro device contribute to chronic inflammation of the posterior segment.

We further analyzed optic nerve degeneration and found similar axon numbers in operated eyes of both syngeneic groups (synPK and synKPro) compared with the fellow, nonoperated eye, but we observed axon loss in the alloPK and the alloKPro groups compared to fellow eyes. During degeneration, axons first swell and bead,²² then decrease in their caliber and lose circularity.²³⁻²⁵ In our study, we found that the axon size slightly increased in the synPK, alloPK, and synKPro groups, but remained comparable to naïve in the alloKPro group. Additionally, we found reduced circularity in all operated groups compared to naïve mice, with a significant difference in the alloKPro group. These results suggest an ongoing degenerative process of the optic nerve in the chronic postoperative period in operated eyes, which is more pronounced after alloKPro implantation. Blocking TNF α , but not IL-1 β , in alloKPro implanted mice had a significant protective effect on axon loss, similar to the reported protective effect of TNF α blockade in preclinical models of glaucoma.²¹ While TNF α antagonists could prove a new strategy to protect against chronic damage to the posterior segment after KPro implantation or repeated transplants, we would caution against any generalization derived from our data in regard to this treatment strategy. Rather, we believe that controlled studies evaluating the efficacy and toxicity/safety of anti-TNF α strategies for suppressing optic neuropathy in highly inflamed eyes that undergo keratoplasty or KPro surgery are warranted before any recommendations are made in relation to specific therapeutic approaches.

In summary, this study provides the first insights into the mechanisms by which KPro implantation may lead to optic nerve damage, and supports the anecdotal reports of rapid and progressive optic neuropathy after KPro implantation. Our data further suggest that corneal allogenicity and the KPro device itself both contribute to the chronic inflammation, affect the posterior segment of the eye, and affect the resultant optic neuropathy. The validation of reducing carrier tissue allogenicity (e.g., via gamma irradiation),²⁶ or cytokine blockade to reduce optic neuropathy after KPro will require clinical trial confirmation.

Acknowledgments

The authors thank Susanne Eiglmeier (Schepens Eye Research Institute, Massachusetts Eye and Ear Infirmary, Boston) for helpful scientific discussions and for providing editorial assistance in the preparation of this manuscript; Demetrios Vavvas (Massachusetts Eye

and Ear Infirmary, Boston) for scientific advice; Pavlina Tsoka, Miin (Irene) Roh (Massachusetts Eye and Ear Infirmary, Boston), Kishore Katikireddy, and Antonio di Zazzo (Schepens Eye Research Institute, Boston) for advice and help in analyzing retinas and optic nerves.

Supported by the Boston-KPro research fund and National Institutes of Health Grant R01-EY 12963.

Disclosure: **A. Črnej**, Massachusetts Eye and Ear Infirmary (E); **M. Omoto**, Massachusetts Eye and Ear Infirmary (E); **T.H. Dohlman**, Massachusetts Eye and Ear Infirmary (E); **M. Gonzalez-Andrades**, Massachusetts Eye and Ear Infirmary (E); **E.I. Paschalis**, Massachusetts Eye and Ear Infirmary (E); **A. Cruzat**, Massachusetts Eye and Ear Infirmary (E); **T.H.K. Vu**, Massachusetts Eye and Ear Infirmary (E); **M. Doorenbos**, Massachusetts Eye and Ear Infirmary (E); **D.F. Chen**, Massachusetts Eye and Ear Infirmary (E); **C.H. Dohlman**, Massachusetts Eye and Ear Infirmary (E); **R. Dana**, Massachusetts Eye and Ear Infirmary (E)

References

- Al-Mezaine H, Wagoner MD; King Khaled Eye Specialist Hospital Cornea Transplant Study Group. Repeat penetrating keratoplasty: indications, graft survival, and visual outcome. *Br J Ophthalmol*. 2006;90:324-327.
- Tan DTH, Janardhanan P, Zhou H, et al. Penetrating keratoplasty in Asian eyes: the Singapore Corneal Transplant Study. *Ophthalmology*. 2008;115:975-982, e1.
- Todani A, Ciolino JB, Ament JD, et al. Titanium back plate for a PMMA keratoprosthesis: clinical outcomes. *Graefes Arch Clin Exp Ophthalmol*. 2011;249:1515-1518.
- Overgaard L, Danielsen N, Bjursten LM. Anti-inflammatory properties of titanium in the joint environment. An experimental study in rats. *J Bone Joint Surg Br*. 1998;80:888-893.
- Srikumaran D, Munoz B, Aldave AJ, et al. Long-term outcomes of boston type 1 keratoprosthesis implantation. *Ophthalmology*. 2014;121:2159-2164.
- Ciolino JB, Belin MW, Todani A, Al-Arfaj K, Rudnisky CJ; Boston Keratoprosthesis Type 1 Study Group. Retention of the Boston keratoprosthesis type 1: multicenter study results. *Ophthalmology*. 2013;120:1195-1200.
- Modjtahedi BS, Elliott D. Vitreoretinal complications of the Boston Keratoprosthesis. *Semin Ophthalmol*. 2014;29:338-348.
- Aldave AJ, Sangwan VS, Basu S, et al. International results with the Boston type I keratoprosthesis. *Ophthalmology*. 2012;119:1530-1538.
- Crnej A, Omoto M, Dohlman TH, et al. A novel murine model for keratoprosthesis. *Invest Ophthalmol Vis Sci*. 2014;55:3681-3685.
- Crnej A, Omoto M, Dohlman TH, Dohlman CH, Dana R. Corneal inflammation after miniature keratoprosthesis implantation. *Invest Ophthalmol Vis Sci*. 2015;56:185-189.
- Amouzegar A, Chauhan SK, Dana R. Alloimmunity and tolerance in corneal transplantation. *J Immunol*. 2016. In press.
- Kurihara T, Omoto M, Noda K, et al. Retinal phototoxicity in a novel murine model of intraocular lens implantation. *Mol Vis*. 2009;15:2751-2761.
- Miller RA, Nadon NL. Principles of animal use for gerontological research. *J Gerontol A Biol Sci Med Sci*. 2000;55:B117-B123.
- Yang Q, Cho KS, Chen H, et al. Microbead-induced ocular hypertensive mouse model for screening and testing of aqueous production suppressants for glaucoma. *Invest Ophthalmol Vis Sci*. 2012;53:3733-3741.
- Rumelt S, Bersudsky V, Blum-Hareuveni T, Rehany U. Preexisting and postoperative glaucoma in repeated corneal transplantation. *Cornea*. 2002;21:759-765.

16. Crnej A, Paschalis EI, Salvador-Culla B, et al. Glaucoma progression and role of glaucoma surgery in patients with Boston keratoprosthesis. *Cornea*. 2014;33:349-354.
17. Kamyar R, Weizer JS, de Paula FH, et al. Glaucoma associated with Boston type I keratoprosthesis. *Cornea*. 2012;31:134-139.
18. Cade F, Paschalis EI, Regatieri CV, Vavvas DG, Dana R, Dohlman CH. Alkali burn to the eye: protection using TNF- α inhibition. *Cornea*. 2014;33:382-389.
19. Xu H, Chen M, Forrester JV, Lois N. Cataract surgery induces retinal pro-inflammatory gene expression and protein secretion. *Invest Ophthalmol Vis Sci*. 2011;52:249-255.
20. Nakazawa T, Nakazawa C, Matsubara A, et al. Tumor necrosis factor-alpha mediates oligodendrocyte death and delayed retinal ganglion cell loss in a mouse model of glaucoma. *J Neurosci*. 2006;26:12633-12641.
21. Roh M, Zhang Y, Murakami Y, et al. Etanercept, a widely used inhibitor of tumor necrosis factor- α (TNF- α), prevents retinal ganglion cell loss in a rat model of glaucoma. *PLoS One*. 2012; 7:e40065.
22. Gaudet AD, Popovich PG, Ramer MS. Wallerian degeneration: gaining perspective on inflammatory events after peripheral nerve injury. *J Neuroinflammation*. 2011;8:110.
23. Sievers C, Platt N, Perry VH, Coleman MP, Conforti L. Neurites undergoing Wallerian degeneration show an apoptotic-like process with Annexin V positive staining and loss of mitochondrial membrane potential. *Neurosci Res*. 2003;46: 161-169.
24. Buckmaster EA, Perry VH, Brown MC. The rate of Wallerian degeneration in cultured neurons from wild type and C57BL/ WldS mice depends on time in culture and may be extended in the presence of elevated K⁺ levels. *Eur J Neurosci*. 1995;7: 1596-1602.
25. Pullarkat PA, Dommersnes P, Fernández P, Joanny J-F, Ott A. Osmotically driven shape transformations in axons. *Phys Rev Lett*. 2006;96:048104.
26. Stevenson W, Cheng S-F, Emami-Naeini P, et al. Gamma-irradiation reduces the allogenicity of donor corneas. *Invest Ophthalmol Vis Sci*. 2012;53:7151-7158.