



Ocular surgical models for immune and angiogenic responses

Citation

Inomata, Takenori, Alireza Mashaghi, Antonio Di Zazzo, and Reza Dana. 2015. "Ocular Surgical Models for Immune and Angiogenic Responses." *Journal of Biological Methods* 2 (3) (September 21): 27. doi:10.14440/jbm.2015.78.

Published version

<https://doi.org/10.14440/jbm.2015.78>

Link

<http://nrs.harvard.edu/urn-3:HUL.InstRepos:34854267>

Terms of use

This article was downloaded from Harvard University's DASH repository, and is made available under the terms and conditions applicable to Open Access Policy Articles (OAP), as set forth at

<https://harvardwiki.atlassian.net/wiki/external/NGY5NDE4ZjgzNTc5NDQzMGIzZWZhMGFIOWI2M2EwYTg>

Accessibility

<https://accessibility.huit.harvard.edu/digital-accessibility-policy>

Share Your Story

The Harvard community has made this article openly available.

Please share how this access benefits you. [Submit a story](#)



HHS Public Access

Author manuscript

J Biol Methods. Author manuscript; available in PMC 2015 November 06.

Published in final edited form as:

J Biol Methods. 2015 ; 2(3): . doi:10.14440/jbm.2015.78.

Ocular surgical models for immune and angiogenic responses

Takenori Inomata[†], Alireza Mashaghi[†], Antonio Di Zazzo[†], and Reza Dana^{*}

Schepens Eye Research Institute, Massachusetts Eye and Ear Infirmary, Department of Ophthalmology, Harvard Medical School, Boston, MA 02114, USA

Abstract

Corneal transplantation serves as a reproducible and simple surgical model to study mechanisms regulating immunity and angiogenesis. The simplicity of the model allows for systematic analysis of different mechanisms involved in immune and angiogenic privilege and their failures. This protocol describes how to induce neovessels and inflammation in an actively regulated avascular and immune-privileged site. This involves placing intra-stromal corneal sutures for two weeks, disrupting the privileges, and performing corneal transplantation subsequently. Privileged and non-privileged recipient responses to donor cornea can be compared to identify key immunological mechanisms that underlie angiogenesis and graft rejection. This protocol can also be adapted to the growing repertoire of genetic models available in the mouse, and is a valuable tool to elucidate molecular mechanisms mediating acceptance or failure of corneal graft. The model could be used to assess the potential of therapeutic molecules to enhance graft survival *in vivo*.

Keywords

alloimmunity; angiogenesis; immune privilege; transplantation

BACKGROUND

Cornea is an avascular tissue and serves as a model system of choice for angiogenesis studies [1]. It actively works to establish an angiogenic privilege, which is essential for maintaining its transparency. Studies on corneal angiogenesis resulted in important insights into how angiogenesis is regulated, and in particular how blood and lymphatic neovessels can be inhibited or induced. Such studies led to the development of potential therapeutics for cardiovascular, neoplastic, and inflammatory diseases [2].

^{*}Corresponding Author: Reza Dana, MD, MSc, MPH, 20 Staniford St, Schepens Eye Research Institute, Massachusetts Eye and Ear Infirmary, Department of Ophthalmology, Harvard Medical School, Boston, MA 02114, USA. Tel: 617-912-7401; Fax: 617-912-0117, Reza_Dana@meei.harvard.edu.

[†]These authors contributed equally to this work.

Competing interests: The authors have declared that no competing interests exist.

Supplementary information

Movie S1. Intra-stromal suture placement.

Movie S2. Suture removal from vascularized host bed.

Movie S3. Excision of host cornea.

Movie S4. High-risk corneal transplantation.

Supplementary information of this article can be found online at <http://www.jbmethods.org/jbm/rt/suppFiles/72>.

Studying cornea angiogenesis (hemangiogenesis and/or lymphangiogenesis) provides a platform for exploring different aspects of the immune response [3]. It is known that a foreign antigen is brought to regional lymphatic tissue via lymphatic vessels where it is specifically recognized. While lymphatic vessels act as afferent arm of the immune response, blood vessels deliver the effector immune cells to the site of insult, acting as efferent arm of the immune response [4]. Aberrant growth of these vessels in the cornea breaks its immune privilege [5]. The link between angiogenesis and immune system in the cornea is bidirectional because resident immune cells play a critical role in initiating and promoting angiogenesis.

Several approaches, involving the eye, have been applied to investigate different aspects of angiogenesis and immunity. A landmark discovery in oncology, showing the tumor-mediated angiogenesis, emerged from introducing tumors into the anterior chamber of a rabbit eye [6]. Experimental eye models have been used to study allergic reactions to antigens [7] as well. Further it has been used to study cellular mechanisms that actively suppress immune responses such as melanocyte-stimulating hormone mediated immune regulation [8].

Our model allows for a comparative analysis of immune responses and the interplay between these responses and angiogenesis. It involves transplantation in an immune privilege context and non-immune privilege one by controlled induction of neovascularization [9]. Corneal transplantation is a common and clinically relevant way for studying the immune response to foreign antigens. The strength of our approach lies in its simplicity and cost effectiveness. An important advantage of corneal transplantation as a model is its accessibility and consequent ease of assessment for angiogenesis and immunological reaction. Since the original development of this model in early 90's [10, 11], our group along with others has been using this or adapted versions of the model to explore corneal immunity and angiogenesis for decades [9]. These efforts led to mechanistic understanding of immune tolerance and of secondary lymphangiogenesis [9].

Briefly, our protocol involves inducing inflammation and neovascularization in cornea and using it as a host bed for corneal transplant. Inflamed and neovascularized host beds carry a higher risk of graft rejection [9]. Neovascularization and inflammation is achieved by performing three butterfly intra-stromal corneal sutures in a well-defined arrangement. After at least two weeks, to have a proper and stable neovascularization, we graft an allogeneic cornea onto the high-risk bed [12]. We can then monitor the graft and perform *in vivo* and *ex vivo* assessments.

MATERIALS

Reagents

Male 6- to 8-week-old C57BL/6 mice are used as donors. Male 6- to 8-week-old Balb/c mice are used as allogeneic recipients. We recommend usage of age- and sex-matched mice to have less variable outcomes. Depending on the aim of the study, the technique can be applied to different strains, genders, ages and animal models for donor and recipient

animals. Care must be taken in trying different options as the ones recommended here. For example it is known that grafting on C57BL/6 mice induces a stronger immune reaction.

- ✓ Ocular viscoelastic device (OVD), (Bausch & Lomb, Rochester, NY, USA, Cat. # 59081L)
- ✓ Propacaine hydrochloride ophthalmic solution 0.5% (wt/vol), (Bausch & Lomb Incorporated, Tampa, FL, USA, NDC 24208-730-06)
- ✓ Phenylephrine ophthalmic solution 5% (ALTAIRE Pharmaceuticals, Inc., Aquebogue, NY, USA, NDC 59390-193-13)
- ✓ Tropicamide ophthalmic solution 1% (Bausch & Lomb Incorporated, Tampa, FL, USA, NDC 24208-590-64)
- ✓ Triple antibiotic eye ointment (Bacitracine Zinc, Neomycin, polymyxin B Sulfates), (Bausch & Lomb Incorporated, Tampa, FL, USA, NDC 24208-780-55)
- ✓ Ketamine (20 mg/kg)/Xylazine (100–200 mg/kg)
- ✓ Buprenorphine (0.05–0.1 mg/kg)
- ✓ Sterile Phosphate Buffer Saline (PBS), (Life Technologies Corporation, Grand Island, NY, USA, Cat. # 10010-031)

Equipment

- ✓ 11-0 nylon suture (MANI, Inc., Tochigi, Japan, Cat. # 0550S)
- ✓ 8-0 nylon suture (MANI, Inc., Tochigi, Japan, Cat. # 2056)
- ✓ Sterile Jeweler's forceps (one blunt and one fine)
- ✓ Scissors (Vannas and curved)
- ✓ Sterile trephine, diameter 2 mm and 1.5 mm. (HealthLink, Jacksonville, FL, USA, Cat. # BP15, BP20)
- ✓ Sterile needles 25G and 30G
- ✓ Binocular microscope
- ✓ Slit lamp
- ✓ Eye spears (Beaver Visitec International, Inc., Waltham, MA, USA, Cat. # 008680)

PROCEDURE

All animal experiments conducted in this protocol were approved by the Institutional Animal Care and Use Committee of the Schepens Eye Research Institute.

High-risk model

A mouse model of corneal neovascularization will be prepared using corneal sutures:

1. Anesthetize mouse with intraperitoneal ketamine (120 mg/kg) and xylazine (20 mg/kg) using a 25G needle.
2. Place mouse in a laterally recumbent position for surgical dissecting microscope visualization.
3. Cut the whiskers and eye lashes to have a clean operating field.
4. Wash the ocular surface with PBS and dry it using a sterile sponge (eye spears).
5. Apply one drop of anesthetic proparacaine 0.5% to the corneal surface prior to starting the procedure. Wait 1–2 min.
6. Dry the ocular surface using eye spears without touching the cornea.
7. Mark the central cornea with 1.5 mm trephine by softly touching the epithelium (Fig. 1A and 1B, Fig. 3A).
8. Place three intrastromal butterfly interrupted sutures (11-0 nylon) with two stromal incursions per suture, extending over 120° of the corneal circumference each. The sutures are positioned out of the marked area without reaching the limbus (Fig. 1C and 1D, Fig. 3B, Movie S1).
9. Apply antibiotic ointment.
10. Administer buprenorphine by subcutaneous injection through 25G needle immediately after surgery and every 12 h for 48 h to minimize post-operative pain.
11. The mice will be clinically evaluated under a surgical microscope and slit lamp every day for up to 2 weeks.

Allogeneic penetrating corneal transplantation

First, prepare the donor cornea and then operate on the recipient.

Donor preparation

12. Euthanize donor mouse using CO₂.
13. Mark the central cornea with a 2 mm diameter trephine. Here, we recommend applying enough pressure to penetrate into deep stroma without perforating the cornea.
14. Tunnel into the anterior chamber from a point on the marked edge using a 30G needle. A proper tunneling would lead to leakage of aqueous humor and a partial collapse of the anterior chamber.
15. Inject OVD to rebuild the depth of the anterior chamber.
16. Carefully dry the surface with eye spears.
17. Partially excise the central donor cornea with Vannas scissors along the marked edge for 270 degrees (Fig. 2A).

18. For less experienced hands we recommend to pass the suture through the free edge of the donor cornea. This is a critical step because suturing the donor on the recipient may be difficult otherwise.
19. Excise the complete cornea, while the suture is in place, by cutting the remaining attachment.
20. Rapidly transfer the cornea with suture into sterile PBS and keep it until the recipient bed is prepared.

Recipient preparation

21. Anesthetize mouse with intraperitoneal ketamine (120 mg/kg) and xylazine (20 mg/kg) using a 25G needle.
22. Place mouse in a laterally recumbent position for surgical dissecting microscope visualization.
23. Cut the whiskers and eye lashes to have a clean operating field.
24. Wash the ocular surface with PBS and dry it using a sterile sponge (eye spears).
25. Apply one drop of anesthetic proparacaine 0.5% to the corneal surface prior to starting the procedure. Wait 1–2 min.
26. Apply one drop of phenylephrine and tropicamide each to dilate the pupil. Wait 1–2 min.
27. Dry the ocular surface using eye spears without touching the cornea.
28. Remove the intrastromal sutures (Movie S2).
29. Mark the central cornea with a 1.5 mm diameter trephine. In this case, we recommend applying enough pressure to penetrate into deep stroma without perforating the cornea (Fig. 3D, Movie S3).
30. Tunnel into the anterior chamber from the marked edge using a 30G needle. A proper tunneling would lead to leakage of aqueous humor and a partial collapse of the anterior chamber. Particular care should be taken to avoid touching lens and iris.
31. Inject OVD to rebuild the depth of the anterior chamber.
32. Carefully dry the surface with eye spears.
33. Excise the complete central host cornea with Vannas scissors along the marked edge (Movie S3).
34. Secure the 2.0 mm diameter donor cornea button to the prepared recipient bed of 1.5 mm diameter with 8 interrupted 11–0 nylon sutures to keep a deep anterior chamber (Fig. 2C, 2D, Fig. 3E, Movie S4).
35. Inject OVD into anterior chamber during the procedure to maintain intraocular structure. We strongly recommend injecting OVD after placement of the first four sutures.

36. Wash the anterior chamber with PBS to remove OVD at the end of the procedure.
37. Keep the contralateral eye moist by using triple antibiotic ointment during the procedure.
38. Apply antibiotic ointment to the operated eye.
39. Close the eyelid for 24 h with 8-0 nylon sutures (tarsorrhaphy, avoids contact between sutures and orb).
40. Administer buprenorphine (0.05–0.1 mg/kg) by subcutaneous injections with a 25G needle immediately after surgery and every 12 h for 48 h to minimize post-operative pain.
41. Remove the eyelid sutures at 24 h post-transplantation in anesthetized recipients under a dissecting microscope with needles.
42. Remove 8 interrupted 11-0 nylon sutures at day 7 post transplantation.

Clinical assessment

Examine all grafted eyes using a slit lamp microscopy, and exclude grafts with technical difficulties (hyphema, infection, loss of anterior chamber). Examine grafts weekly by slit-lamp microscopy for edema, opacity, and neovascularization. Use a standard scoring system [13] (see Table 1) to describe the extent of opacity and neovascularization. Grafts with an opacity score of 2+ or greater 3 weeks after transplantation are considered rejected (immunologic failure). Grafts with an opacity score of 3+ or greater at 2 weeks post-transplantation that never clear are also considered rejected.

ANTICIPATED RESULTS

Introducing intrastromal sutures as described here will lead to growth of sprouting vessels within 1 to 2 days. Within few days a prominent neovascularization should be established in more than two quadrants of the cornea, which is minimally needed for an effective high-risk model (Fig. 2B, Fig. 3C).

Allogeneic corneal transplantation onto a vascularized and inflamed host bed, as described in our model, succeeds in 90% of the cases by the end of two weeks post transplantation. After 4 weeks, the graft survival rate will decrease to 50% (Fig. 3F). In contrast, in the absence of inflammation and aberrant vessels the rate of rejection is dramatically reduced and no grafts are rejected two weeks after transplantation [14, 15].

Our model allows for detailed analysis of immune pathways involved, including Th1 immune response, regulatory effect of T cells and pro-inflammatory and tolerogenic capacity of antigen presenting cells. We also use this model to study the role of innate and adaptive immunity in angiogenesis. All these are possible by not only using the eye tissues but also assessing the changes in the draining lymph node and spleen. Moreover, this model can be used with knockout and transgenic mice to evaluate various molecular pathways participating in immune response and angiogenesis.

A number of other models for high-risk corneal beds have been used previously and may complement the model proposed in this paper. The cornea micropocket assay [16] been used for such studies for decades; however, over time the assay has been replaced by the surgical procedure described in our paper which may has many advantages such as reproducibility, low cost, and easy feasibility. In the micropocket assay, the vessels are induced by a not discriminated combination of injury and drugs, and the success of the micropocket technique highly depends on the ability of the surgeon. Slight changes in the procedure and device inserted into the eye can result in very high variations of vessel induction. In contrast, using the suture model presented in this protocol induces homogenously distributed neovessels in all four quadrants of the cornea. We note that the model presented here does not serve as a generic model for all high-risk settings. For instance, patients with allergic background carry high risk for rejection. Here, we recommend usage of allergic mouse models [7]. Alkali burns to murine cornea also serve as suitable model systems for patients with accidental exposure to a number of chemicals [17]. Corneal alkali burn leads to severe neovascularization, however, the underlying damage to the cornea is biologically complex and we have limited control on the extent of the damages (in contrast to the suture model) that may involve limbal areas among others. Thus, it is relatively hard to disentangle the role of various contributing factors (immunologic and non-immunologic). Overall, the simplicity, availability, and the cost of the described model provide a unique platform to study basic principles of immunity and angiogenesis beyond ophthalmic issues.

TROUBLESHOOTING

During the procedure one may encounter a number of problems. Here we list potential issues and explain how one can do troubleshooting.

1. During introduction of intra-stromal sutures, one may occasionally perforate the cornea. This is evidenced by leakage of the humor and a subsequent Siedel sign (Fig. 4). In this case, the immune privilege of the anterior chamber is compromised. The compromised cornea should be discharged.
2. Cataract is a major complication that results from touching the capsule of the lens while preparing the recipient. In this case, an undesired inflammatory reaction against the lens antigens will suddenly rise.
3. In case of incomplete removal of the OVD from the anterior chamber, we will face a high risk of intra ocular hypertension.
4. A severe complication is bleeding in the anterior chamber and subsequent hyphema formation. This is often related to cutting the iris during the procedure as well as to sudden decrease of the intraocular pressure during or after the procedure. Sometimes it can be caused by ingrowing neovessels into the anterior chamber after suture placement.
5. At the end of the procedure, it is important to check the tightness of the sutures and the arrangement of the graft edge for avoiding humor leakage and iris trap.

6. For phenylephrine administration, we suggest to administer the drug carefully to avoid airways and oral mucosa adsorption. Systemic adsorption of the drug leads to cardiovascular and respiratory dysfunctions.
7. Late removal of tarsorrhaphy may lead to surface inflammation and an increased rejection rate.

Supplementary Material

Refer to Web version on PubMed Central for supplementary material.

Acknowledgments

The authors thank Dr. Victor Sendra for technical support and Dr. Susanne Eiglmeier for critical reading of the manuscript. This work was supported by the National Institute of Health (Grant number: EY-012963).

References

1. Dana MR. Angiogenesis and lymphangiogenesis-implications for corneal immunity. *Semin Ophthalmol.* 2006; 21:19–22. PMID: 16517440. [PubMed: 16517440]
2. Skobe M, Dana R. Blocking the path of lymphatic vessels. *Nat Med.* 2009; 15:993–994. PMID: 19734869. [PubMed: 19734869]
3. Chen L, Hamrah P, Cursiefen C, Zhang Q, Pytowski B, et al. Vascular endothelial growth factor receptor-3 mediates induction of corneal alloimmunity. *Nat Med.* 2004; 10:813–815. PMID: 15235599. [PubMed: 15235599]
4. Cursiefen C, Chen L, Borges LP, Jackson D, Cao J, et al. VEGF-A stimulates lymphangiogenesis and hemangiogenesis in inflammatory neovascularization via macrophage recruitment. *J Clin Invest.* 2004; 113:1040–1050. PMID: 15057311. [PubMed: 15057311]
5. Streilein JW. Ocular immune privilege: therapeutic opportunities from an experiment of nature. *Nat Rev Immunol.* 2003; 3:879–889. PMID: 14668804. [PubMed: 14668804]
6. Gimbrone MA Jr, Leapman SB, Cotran RS, Folkman J. Tumor dormancy *in vivo* by prevention of neovascularization. *J Exp Med.* 1972; 136:261–276. PMID: 5043412. [PubMed: 5043412]
7. Niederkorn JY, Chen PW, Mellon J, Stevens C, Mayhew E. Allergic conjunctivitis exacerbates corneal allograft rejection by activating Th1 and Th2 alloimmune responses. *J Immunol.* 2010; 184:6076–6083. PMID: 20410484. [PubMed: 20410484]
8. Hamrah P, Haskova Z, Taylor AW, Zhang Q, Ksander BR, et al. Local treatment with alpha-melanocyte stimulating hormone reduces corneal allojection. *Transplantation.* 2009; 88:180–187. PMID: 19623012. [PubMed: 19623012]
9. Dana MR, Qian Y, Hamrah P. Twenty-five-year panorama of corneal immunology: emerging concepts in the immunopathogenesis of microbial keratitis, peripheral ulcerative keratitis, and corneal transplant rejection. *Cornea.* 2000; 19:625–643. PMID: 11009315. [PubMed: 11009315]
10. She SC, Steahly LP, Moticka EJ. A method for performing full-thickness, orthotopic, penetrating keratoplasty in the mouse. *Ophthalmic Surg.* 1990; 21:781–785. PMID: 2270163. [PubMed: 2270163]
11. He YG, Ross J, Niederkorn JY. Promotion of murine orthotopic corneal allograft survival by systemic administration of anti-CD4 monoclonal antibody. *Invest Ophthalmol Vis Sci.* 1991; 32:2723–2728. PMID: 1680112. [PubMed: 1680112]
12. Hamrah P. High-risk penetrating keratoplasty. *Arch Soc Esp Oftalmol.* 2005; 80:5–7. PMID: 15692887. [PubMed: 15692887]
13. Sonoda Y, Streilein JW. Orthotopic corneal transplantation in mice—evidence that the immunogenetic rules of rejection do not apply. *Transplantation.* 1992; 54:694–704. [PubMed: 1412761]

14. Huq S, Liu Y, Benichou G, Dana MR. Relevance of the direct pathway of sensitization in corneal transplantation is dictated by the graft bed microenvironment. *J Immunol.* 2004; 173:4464–4469. PMID: 15383577. [PubMed: 15383577]
15. Yamagami S, Dana MR, Tsuru T. Draining lymph nodes play an essential role in alloimmunity generated in response to high-risk corneal transplantation. *Cornea.* 2002; 21:405–409. PMID: 11973391. [PubMed: 11973391]
16. Rogers MS, Birsner AE, D'Amato RJ. The mouse cornea micropocket angiogenesis assay. *Nat Protoc.* 2007; 2:2545–2550. PMID: 17947997. [PubMed: 17947997]
17. Anderson C, Zhou Q, Wang S. An alkali-burn injury model of corneal neovascularization in the mouse. *J Vis Exp.* 2014 PMID: 24748032.

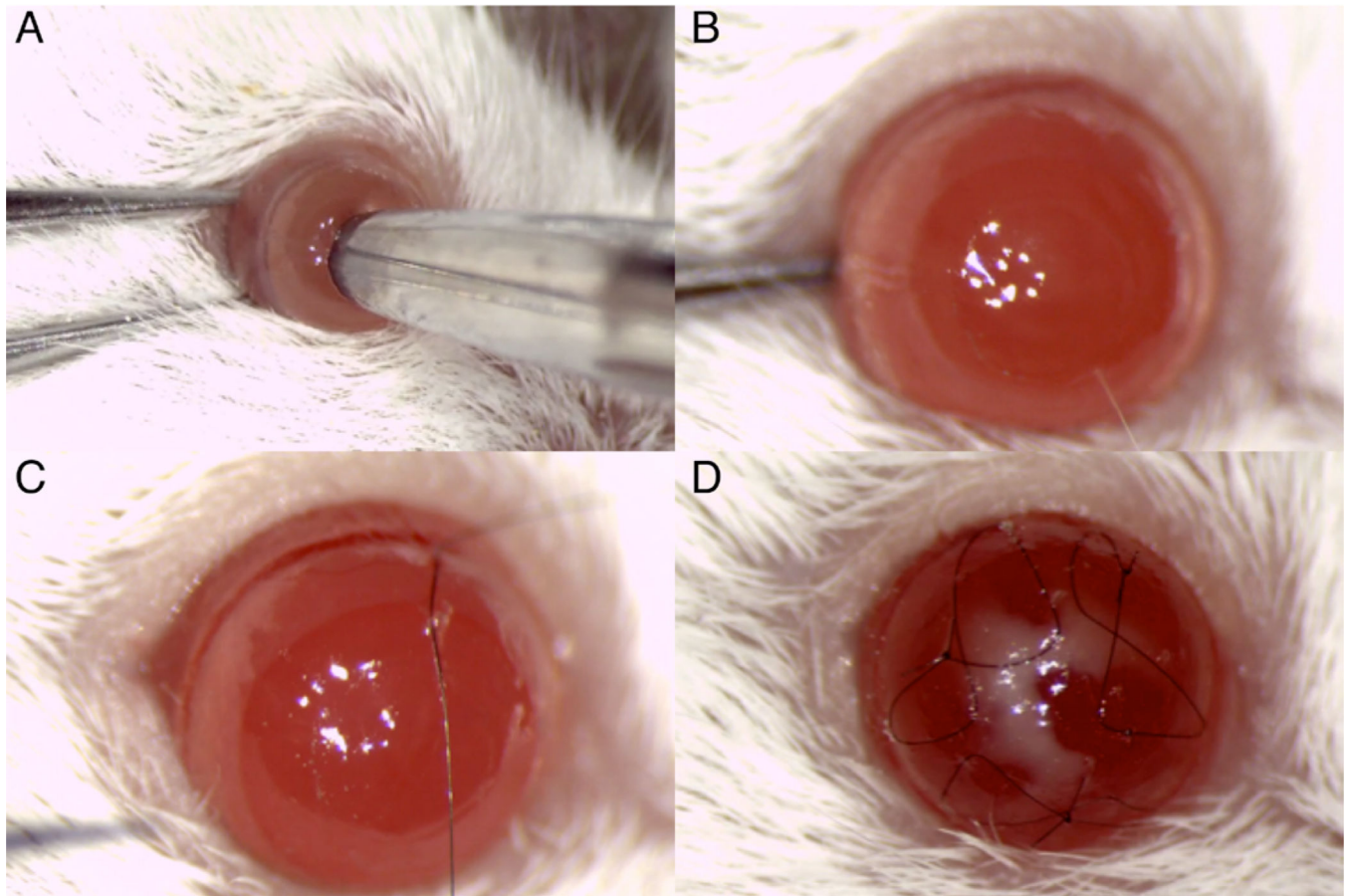


Figure 1. Intra-stromal suture placement

A and B. Marking the cornea. **C.** Suture positioning between the limbus and marked ring. **D.** Three butterfly sutures.

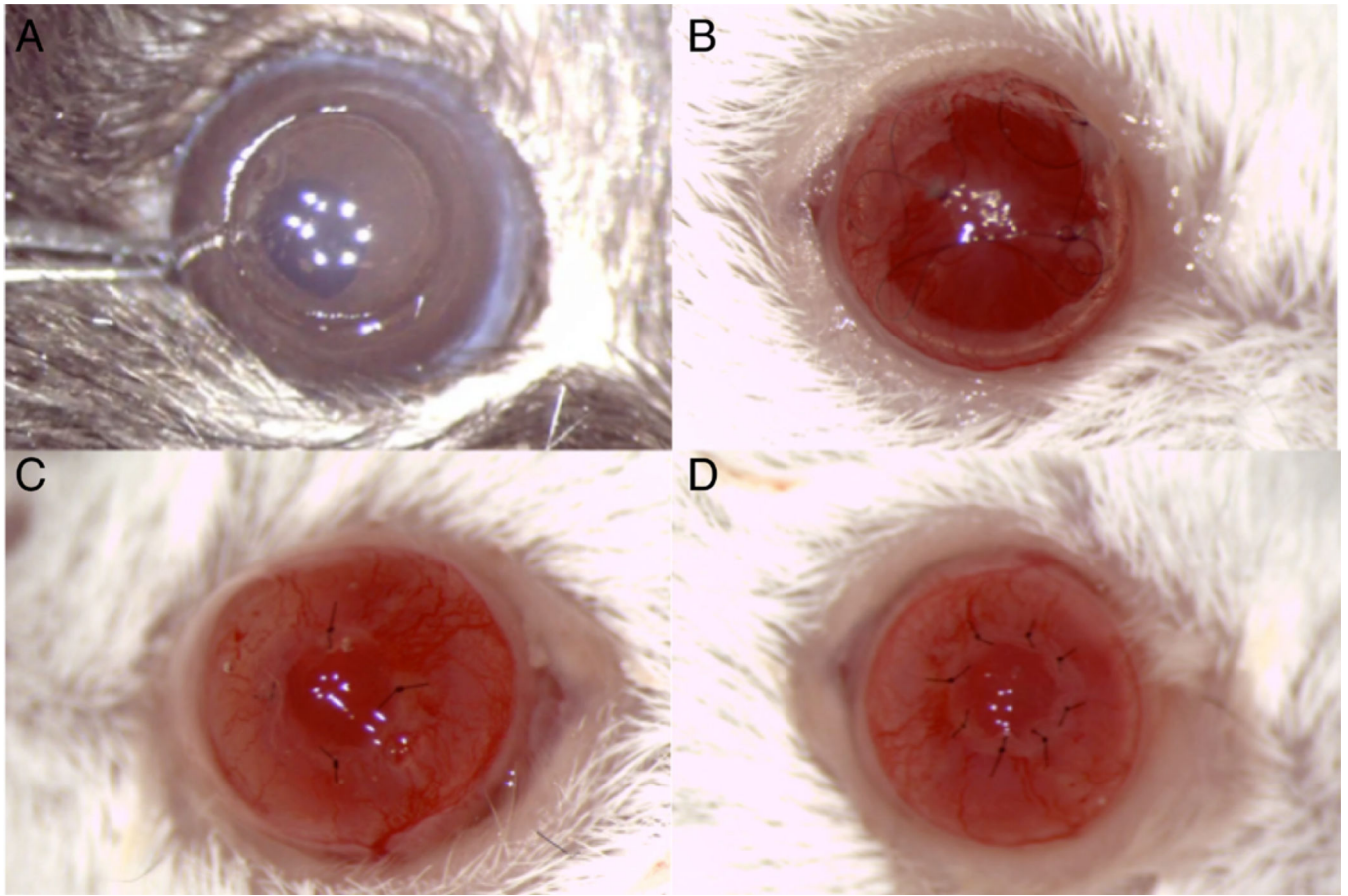


Figure 2. Allogenic corneal transplantation

A. Donor preparation. **B.** Vascularized and inflamed host bed. **C.** The graft after placement of four sutures. **D.** Allografted cornea.

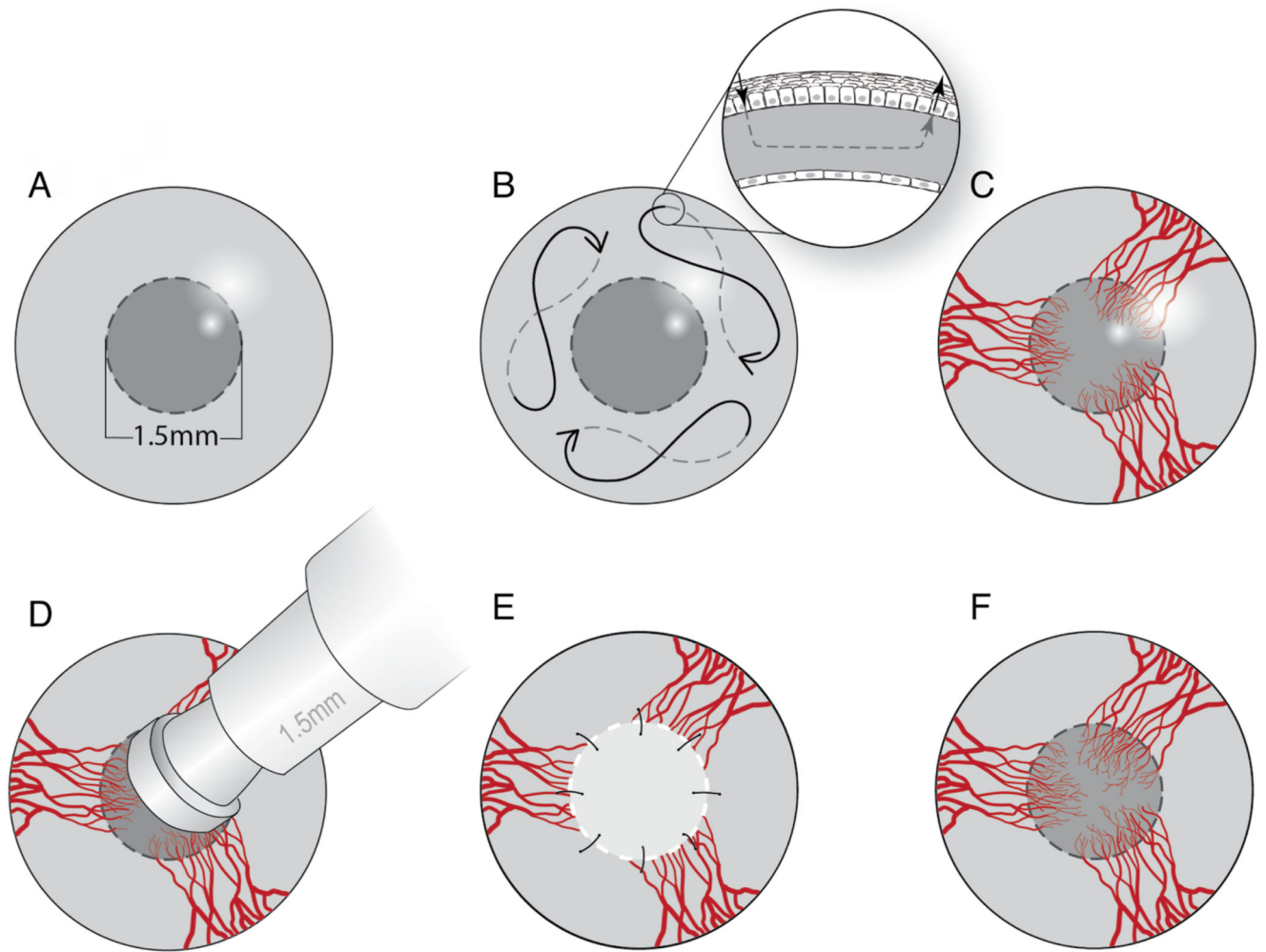


Figure 3. Schematic drawing of the surgical procedure

A. Mark the central cornea with 1.5 mm trephine. **B.** Place three intra-stromal butterfly interrupted sutures. **C.** Vascularized and inflamed host bed. **D.** Mark the central donor cornea with 1.5 mm trephine. **E.** Donor cornea is transplanted onto vascularized cornea bed of the host. **F.** Rejected graft with vessel ingrowth and opacity.

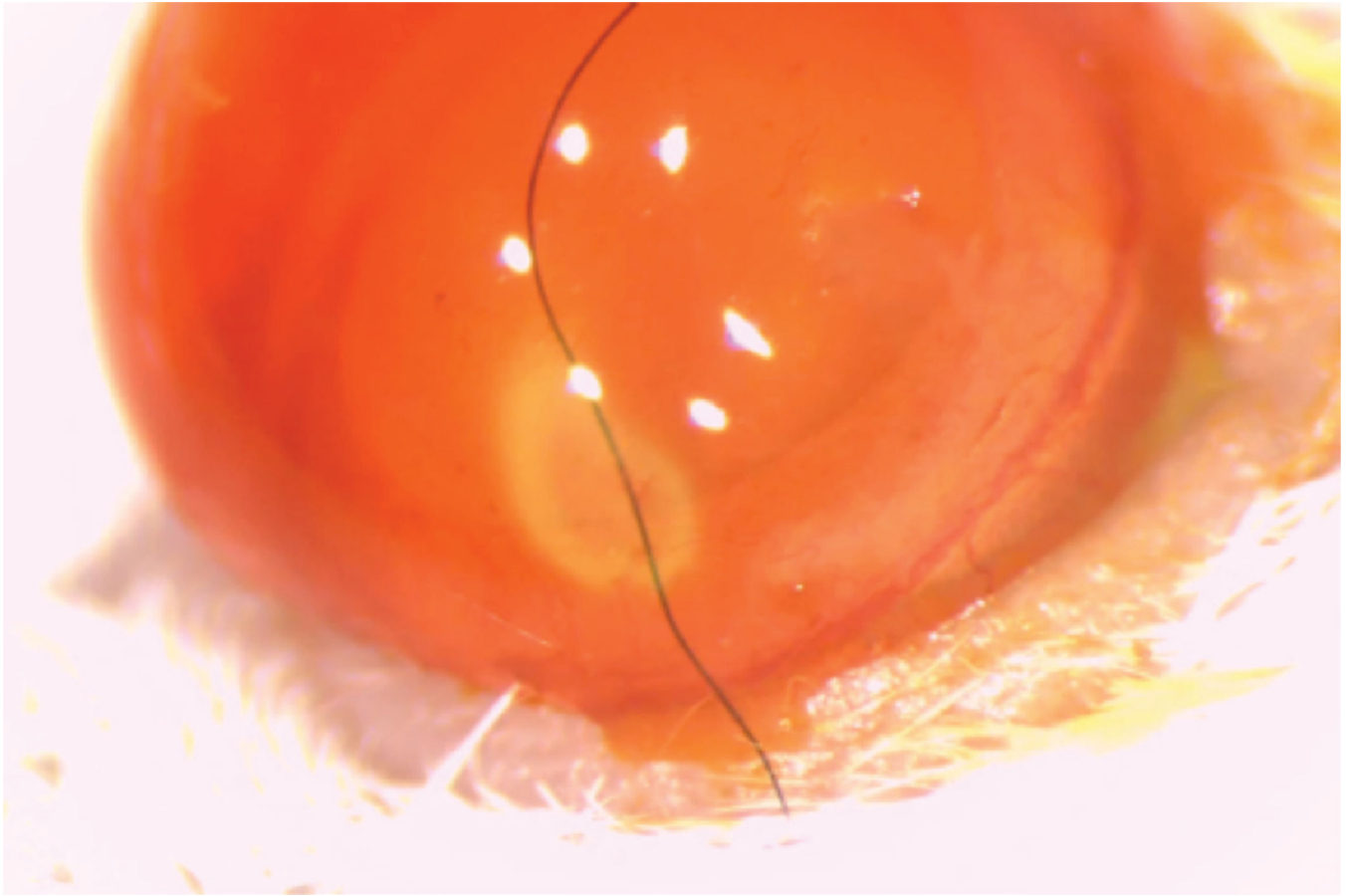


Figure 4. Corneal perforation

Perforation is a main complication of intra-stromal suture placement. Positive Siedel sign.

Table 1

Graft scoring based on corneal opacity and neovascularization.

Score	Clinical manifestations
0	Clear
1	Minimal superficial opacity, iris vessels readily visible
2	Minimal deep (stromal), opacity, iris vessels still visible
3	Moderate stromal opacity, only pupil margin visible
4	Intense stromal opacity, only portion of pupil margin visible
5	Maximal stromal opacity, anterior chamber not visible
Score	Clinical manifestation
0	No vessels
1	Vessels bed only (1–2 quadrants)
2	Vessels bed only (3–4 quadrants)
3	Vessels recipient graft border (1–2 quadrants)
4	Vessels recipient graft border (3–4 quadrants)
5	Vessels peripheral donor stroma (1–2 quadrants)
6	Vessels peripheral donor stroma (3–4 quadrants)
7	Vessels central donor stroma (1–2 quadrants)
8	Vessels central donor stroma (3–4 quadrants)

Author Manuscript

Author Manuscript

Author Manuscript

Author Manuscript